

# Hypothyroidism due to Hashimoto thyroiditis post struma ovarii excision

Vera N. Amareen, MD, JB (Gyn & Obs), Fares H. Haddad, MD, MRCP(UK), Nabih S. Al-Kaisi, JB, MD.

---

## ABSTRACT

Struma ovarii is a rare ovarian teratoma that may produce hyperthyroidism. The association with Hashimoto thyroiditis (HT), however is rare and has been reported in only one case. We report a case of HT following the resection of struma ovarii tumor, after which the patient became frankly, hypothyroid with elevated thyroid stimulating hormone and low thyroxine levels. Her thyroid peroxidase antibodies were positive. She improved after initiation of levothyroxine replacement therapy. We believe her euthyroid status preoperatively was due to thyroid hormone secretion by struma ovarii itself.

Saudi Med J 2004; Vol. 25 (7): 948-950

---

Struma ovarii (SO) is a rare monodermic teratoma of the ovary with a prevalence of 2.7%.<sup>1</sup> It is usually associated with malignancy in 5-10% of cases.<sup>1-3</sup> The association and production of hyperthyroidism has been frequently reported.<sup>4-6</sup> The association with hypothyroidism is very rare and has been reported in only one case.<sup>7</sup> Hashimoto thyroiditis (HT) has also been reported in SO tumor with positive anti-thyroid antibodies but with absence of signs and symptoms of thyroid dysfunction,<sup>8</sup> again HT was reported in a papillary thyroid carcinoma in a malignant teratoma of the ovary.<sup>9</sup> We report a case of HT in struma ovarii with post-operative clinical signs and symptoms of hypothyroidism.

**Case Report.** A 41-year-old lady who is gravida 9 para 8+1 (still birth), presented in June 2002 with increasing lower abdominal pain for 3 weeks prior to her presentation. Physical examination was free except for a pelvic mass lesion, which was confirmed by pelvic and vaginal ultrasound to be a 10 x 10 cm homogenous mass in

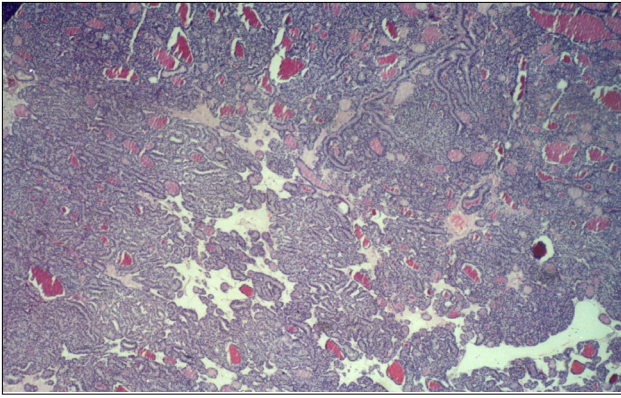
the left ovary pushing the uterus. Follow up ultrasound showed a further enlargement of the mass lesion, so examinations made a prompt decision towards laparotomy. At laparotomy a 10-cm mass arising from the left ovary was removed, the tumor was not invading the surrounding tissues or adherent to it. The frozen section examination however, gave conflicting report highly suggestive of a malignant process. Therefore, total abdominal hysterectomy and bilateral salpingo-oophorectomy was performed. The immediate postoperative course was uneventful except for tiredness. The final histopathological report was of a tumor of 11 cm in greatest dimension, lobulated, encapsulated with homogenous creamy colored and contained small cystic areas. The capsule was smooth, and intact the microscopic examination slides showed a monodermal teratoma composed entirely of mature benign thyroid tissue, with no evidence of adenoma, carcinoma or other tissue elements, therefore, the diagnosis of struma ovarii was established. (Figures 1 & 2).

---

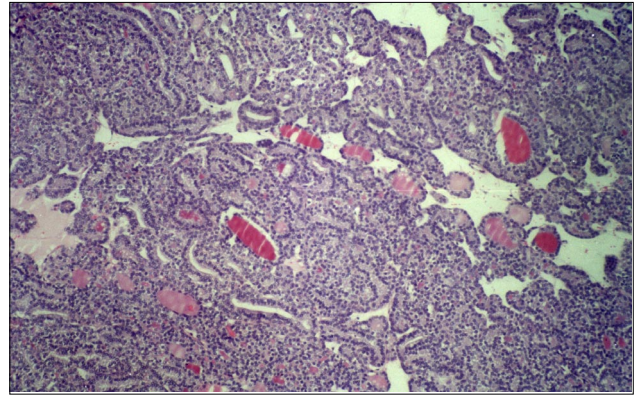
From the Department of Obstetric and Gynecology (Amareen), King Hussein Medical Center, Division of Endocrine, Medical Department (Haddad), Department of Histopathology (Al-Kaisi), Princess Iman Research and Laboratory Sciences Center, Amman, Jordan.

Received 15th November 2003. Accepted for publication in final form 10th February 2004.

Address correspondence and reprint request to: Dr. Fares H. Haddad, Medical Department, PO Box 967, Amman 11118, King Hussein Medical Center, Jordan. Tel. +962 (79) 5904905. E-mail: haddf@hotmail.com.



**Figure 1** - Hematoxylin and eosin x 40 showing benign thyroid tissue replacing the whole mass.



**Figure 2** - Hematoxylin and eosin x 100 close up view revealing colloid and benign follicular cell. No evidence of adenoma or malignant cell.

Two weeks postoperatively the patient came back with tiredness, severe myalgia and lack of zest. She also complained of dryness of skin and constipation. Clinical examination revealed frank hypothyroid lady with coarse hair, puffy face and delayed ankle reflexes. An acute hypothyroidism was suspected in the context of struma ovarii. The results of thyroid function test were; thyroid stimulating hormone (TSH) >50.2 uiU/ml (normal range 0.4-4.5), free triiodothyronine (FT3) was low (<1.00pg/ml normal range 1.4-4.6), free thyroxine (FT4) at 0.4ng/dL (normal 0.8-1.9). Her antithyroglobulin antibodies were negative, and anti thyroid peroxidase antibodies were positive at 1/1600 (normal <1/100) confirming hypothyroidism due to autoimmune HT. Thyroid technetium scan showed rather reduced uptake at the thyroid bed and the I<sup>131</sup> whole body scan did not show abnormal uptake in the thyroid bed nor elsewhere. The patient was started initially on levothyroxine 50 mg per day then adjusted up to 125 mg with marked improvement in patient's symptoms and normalization of her TSH.

**Discussion.** Struma ovarii is a monodermal teratoma of the ovaries that contain a large amount of thyroid tissue. Its diagnosis is almost always carried out incidentally, as an ovarian mass.<sup>7,10</sup> These tumors may cause ascitis, pain, abnormal bleeding, intestinal obstruction, virilization and death. No evidence of vital function maintained by an ovarian neoplasm has been reported. Struma ovarii may cause hyperthyroidism and the differential diagnosis includes ectopic causes of hyperthyroidism, factitious hyperthyroidism and metastatic thyroid cancer,<sup>7</sup> in these cases radioiodine I<sup>131</sup> whole body scan is of great help in clarifying the site of hypersecretion outside thyroid bed.<sup>11,12</sup> Carvalho et al<sup>7</sup> has reported the first case of hypothyroidism, which appeared acutely after removal of SO. The diagnosis of thyroiditis was

suggested by ultrasonic examination in this case. Bonadio<sup>8</sup> has reported a case of HT proved by positive antithyroid antibodies but has no clinical or biochemical evidence of thyroid dysfunction. We report a case of overt hypothyroidism that appeared acutely after removal of SO and has a positive thyroid antibodies highly suggestive of HT. We believe that the SO tumor was secreting thyroid hormone which was enough to render a euthyroid status in this patient, once the source of thyroid hormone was removed; the patient exhibited hypothyroidism. The thyroid function test was not checked prior to the operation as of lack of clinical signs and symptoms (euthyroid clinical status) and of uncertainty of the presence of SO as it is with many other struma ovarii cases.<sup>2,7,10</sup> This report should alert gynecologists to consider SO in the differential diagnosis of ovarian masses and to consider checking thyroid function tests as a baseline in their patients.

## References

1. Cohen A, Aguilar C, Gomez S, Rodriguez M. Struma ovarii, a variety of monodermal teratoma of the ovary, report of 8 cases. *Ginecol Obstet Mex* 1999; 67: 153-157.
2. Young RH. New and unusual aspects of ovarian germ cell tumors. *Am J Surg Pathol* 1993; 17: 1210-1222.
3. Yannopoulos D, Yannopoulos K, Ossowski R. Malignant struma ovarii. *Pathol Annu* 1976; 11: 403-413.
4. Mimura Y, Kishida M, Musuyama H, Suwaki N, Kodama J, Otsuka F et al. Coexistence of Graves' and struma ovarii: case report and literature review. *Endocr J* 2001; 48: 255-260.
5. Duzendorfer T, deLas Morenas A, Kalir T, Levin RM. Struma ovarii and hyperthyroidism. *Thyroid* 1999; 9: 499-502.
6. Kano H, Inoue M, Nishino T, Yoshimoto Y, Arima R. Malignant struma ovarii with Graves' disease. *Gynecol Oncol* 2000; 79: 508-510.
7. Carvalho JP, Carvalho FM, Lima de Oliveria FF, Asato de Camargo RY. Hypothyroidism following struma ovarii tumor resection: a case report. *Rev Hosp Clin Fac Med Sao Paulo* 2002; 57: 112-114.

8. Bonadio AG. Hashimoto's thyroiditis in "struma ovarii". Case reports and review of the literature. *Minerva Endocrinol* 2002; 27: 49-52.
9. Doldi N, Taccagni GL, Bassan M, Frigerio L, Mangili G, Jansen AM et al. Hashimoto's disease in a papillary carcinoma of the thyroid originating in a teratoma of the ovary (malignant struma ovarii). *Gynecol Endocrinol* 1998; 12: 41-42.
10. Szyfelbein WM, Young RH, Scully RE. Cystic struma ovarii: a frequently unrecognized tumor. A report of 20 cases. *Am J Surg Pathol* 1994; 18: 785-788.
11. Lazarus JH, Richards AR, MacPherson MJ, Dinnen JS, Williams ED, Owen GM et al. Struma ovarii: a case report. *Clin Endocrinol (Oxf)* 1987; 27: 715-720.
12. Grandt PJ, Remi MH. Struma ovarii with hyperthyroidism. *Clin Nucl Med* 2000; 25: 763-765.

**Access [www.smj.org.sa](http://www.smj.org.sa)**

**Saudi Medical Journal Online features**

- Instructions to Authors
- Uniform Requirements
- STARD
- Free access to the Journal's Current Issue
- Future Contents
- Advertising and Subscription Information

All Subscribers have access to full text articles in HTML and PDF format. Abstracts and Editorials are available to all Online Guests free of charge and can access link references to EMBASE, Excerpta Medica, BIOBASE & PubMed.