Case Report

Abdominal tuberculosis in adolescents

Difficulties in diagnosis

Mustafa Akcam, MD, Reha Artan, MD, Aygen Yılmaz, MD, Hikmet Cig, MD, Nazif H. Aksoy, MD.

ABSTRACT

Since the nature of abdominal tuberculosis is mimicking a number of diseases, this may cause delayed diagnosis resulting in evident increased morbidity and mortality. Most of the time, serologic and bacteriologic tools are not enough. We report 3 adolescents with distinct presentations, one mimicking Crohn's disease, one with hepatitis, and the last one with ascites. Terminal ileitis and mesenteric lymphadenitis were found in laparotomy of the first case mimicking Crohn disease. Granulomatous hepatitis was found in the liver biopsy of the second patient, and peritonitis was found by laparoscopy of the third patient. Tuberculosis could be diagnosed merely by histopathologic investigation. All were treated successfully without complication.

Saudi Med J 2005; Vol. 26 (1): 122-126

Tuberculosis has also become an important health problem in developed, as well as, underdeveloped or developing countries after the emergence of acute immune deficiency syndrome (AIDS). Abdominal tuberculosis (AT) in this paper refers to the peritoneum and its reflections, gastrointestinal tract, abdominal lymphatic system, and solid visceral organs as they are subject to varying degrees of involvement alone or in combination. Tuberculous peritonitis (TP), which occurs most often in young men, is uncommon in adolescents and rare in children.[1] Abdominal tuberculosis is characterized by fever, abdominal pain, anorexia, weight loss, and ascites. However, as none of these symptoms is specific for the disease, it is commonly misdiagnosed, especially as carcinomatous peritonitis, miliary Crohn disease, starch peritonitis, schistosomiasis and rare chronic granulomatous peritonitis. Early diagnosis of TP is important in the control of the disease.[2,3]

Tuberculosis is familiar from ancient times, but unfortunately, an easy, economic, noninvasive, rapid and net resulting diagnostic tool has not been explored. Diagnosis of pulmonary tuberculosis is relatively easy. On the other hand, if due to the rare incidence and silent progression that AT is not suspected, the delay of diagnosis increased the mortality and morbidity. Traditional bacteriological methods are time-consuming and their sensitivity is low. Although, there are some advanced diagnostic tools (polymerase chain reaction (PCR),[4] adenosine Deaminase (ADA)[5], and cancer antigen 125 (CA-125),[6] and so forth) definite diagnosis could be possible only with histopathologic examination. In most cases, treatment is empirical and physicians

From the Department of Pediatrics (Akcam, Artan, Yilmaz, Cig) Department of Pathology (Aksoy), Division of Pediatric Gastroenterology, Hepatology and Nutrition, Faculty of Medicine, Akdeniz University, Antalya, *Turkey*.

Received 20th June 2004. Accepted for publication in final form 18th September 2004.

Address correspondence and reprint request to: Dr. Reha Artan, Department of Pediatrics, Division of Pediatric Gastroenterology, Hepatology and Nutrition, Faculty of Medicine, Akdeniz University, 07070 Antalya, *Turkey*. Tel. +90 (242) 2274343. Fax. +90 (242) 2274320. E-mail: artan@akdeniz.edu.tr

are often uncertain as to whether they should continue or discontinue anti-tuberculous therapy.

We presented 3 adolescents with vague symptoms. Diagnosis were confirmed only by the help of histopathologic examination.

Case Report. ***Patient one.*** A 14-year-old girl presented with abdominal distention, diarrhea, secondary amenorrhea and weight loss (4 kg in one month). She had one and half year history of progressive loss of appetite. She had bowel movements twice a day that were watery, foul smelling and containing neither mucus nor blood. She had worked as a shepherd and drank raw milk habitually. There was no family history of tuberculosis. Physical examination revealed: weight 37 kg (3-10 percentiles), height 151 cm (50-75 percentiles), well developed secondary sex characteristics, lethargy, wasting, edema on the dorsum of foots and clubbing of fingers. She has a Bacillus Calmette-Guerin (BCG) scar. Urinalysis, complete blood count, chest x-ray, serum vitamin B12 and folic acid, antigliadin antibodies, were performed to evaluate her etiology, and were found normal except with mild anemia. C-reactive protein (CRP) was positive and erythrocyte sedimentation rate (ESR) was 97 mm/h. Tuberculin test using 5 units of purified protein derivative (PPD), yielded 10 mm in the duration of 48 hours. Human immune-deficiency virus (HIV) was negative. Stool examination demonstrates Giardia cysts. Abdominal ultrasonography revealed mesenteric lymphadenopathy on the right lower quadrant. Biopsy materials that was obtained by upper and lower gastrointestinal endoscopy were reported as bulbitis, lymphocytic gastritis and non-specific colitis. Her gastrointestinal symptoms and weight loss persisted and subfebrile fever emerged while she was taking treatment against giardiasis.

Crohn disease was considered because of her complaints of which 5-amino salicylic acid and prednisolone were started, but clinical improvement was not observed. At the second month of her hospitalization, laparotomy was performed and showed terminal ileitis and enlargement of mesenteric lymph nodes. The histopathologic findings of obtained mesenteric lymph node were considered as tuberculosis (**Figure 1**). After initiation of pyrazinamid (PZ), isoniasid (INH), and rifampicin (RIF) combination her health improved. She began to gain weight, and survived without any complaint during 2-year follow up period.

Patient 2. A 12-year-old girl, diagnosed as incontinentia pigmenti with mental motor retardation, was previously admitted with abdominal pain and fever for a period of 3 months. Her axillary lymphadenitis and pneumonia had

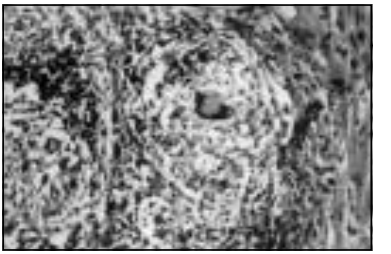

Figure 1 - Pathology (Hematoxylin and Eosin x 200) of mesenteric lymph node biopsy showing epitheloid granulomas with central caseation necrosis and Langhan's giant cell.

Figure 2 - Pathology (Hematoxylin and Eosin x 100) liver biopsy showing ceseating granuloma and Langhan's giant cell.

Figure 3 - Laparoscopy of abdominal cavity showing adhesions, whitish, rounded, small nodules involving the peritoneum.

developed after BCG vaccination at her fourth month of age. Family screening for tuberculosis was negative. Physical examination revealed hyperpigmented areas over the whole body, abdominal distention but no ascites, caput medusae and her palpable liver of 5 cm and spleen of 9 cm were below the costal margins. She had a right hemiparesia and shortness of right leg. The laboratory findings were as follows; hemoglobin: 7 g/dL, leukocyte: 3640/mm^3, platelet: 164000/mm^3, alanine aminotransferase / aspartate aminotransferase / gamma glutamyl transferase / alkaline phosphatase: 67/107/158/4338 U/L, total protein/albumin: 7.5/2.2 g/dl. Erythrocyte sedimentation rate was 113 mm/h, CRP: 7.9 mg/dL, total/direct bilirubin: 5.1/4.4 mg/dL, prothrombine and activated partial thromboplastin times were normal. Purified protein derivative test was strongly positive (22 mm indurations at 48 hours), hepatitis A, B, C and E markers were all negative. Acido resistant bacillus (ARB) with Erlich Ziehl Neelsen stain, PCR, and culture for tuberculosis were negative in fasting gastric fluid. The antimitochondrial, antismooth muscle and liver-kidney microsomal antibodies were negative. *Toxoplasma*, rubella, cytomegalovirus, herpes simplex virus antibodies and brucella agglutination test were all negative. Hepatomegaly with minimal heterogeneity, parenchymal calcification at right posterior region (9 x 7 mm) of the liver was detected with ultrasonography. Although her chest x-ray was normal, the high resolution computed tomography (HRCT) showed miliary lesions in the lungs. Granulomatous inflammation containing Langhan's giant cells with caseation necrosis was demonstrated by histopathologic evaluation of liver specimens (**Figure 2**). She was diagnosed at the end of the first month of hospitalization and triple antituberculous regime was started (PZ+RIF+INH). Ethambutol (EMB) was added because of persistent fever. Fever and abdominal complaints were solved in 5 days. The follow up visits did not reveal any problem related to tuberculosis.

Patient 3. A 16-year-old boy was admitted with one month history of fever, a 5 kg weight loss and weakness. He was a member of high socioeconomic level family where there is no history of tuberculosis. Optimal physical growth, toxic facial appearance, diminished breath sounds on the right hemithorax and dullness on the basal parts of the lungs, distended abdomen without tenderness and rebound, ascites and 2 BCG scars were detected on physical examination. There was no hepatosplenomegaly, ESR: 42 mm/h, CRP: 15 mg/dL. Hepatitis A, B, C, E virus, HIV and PPD test were negative, CA-125:183 U/ml (Normal: $\leq$35 U/ml). Abdominal ultrasonography revealed free fluid in perihepatic and perisplenic areas. Right pleural effusion was demonstrated by chest x-ray. Abdomen and thorax computed tomography (CT) revealed ascites, irregular heterogenic thickening of omentum and right-sided pleurisy. Ascite fluid characteristics were serohemorrhagy, lymphomonocytic cell predominance and no atypical cell. Acido resistant bacillus, PCR and culture were negative for tuberculosis. Laparoscopy revealed moderate ascites, diffuse adhesions, and multiple pinhead-size whitish nodules in abdominal cavity (**Figure 3**). Histopathology demonstrated granulomatous inflammation with caseation necrosis and Langhan's giant cells. After pathologic diagnosis, antituberculous regime was started (streptomycine + INH + RIF) and a rapid clinical improvement was seen. He gained 3 kg one month after treatment together with reduction of ESR to 10 mm/h and CA-125 to 35 U/ml.

Discussion. Despite the introduction of effective antituberculous therapy, the mortality of TP remained high and was probably related to the diagnostic difficulty of this great mimicker defying diagnosis. Tuberculous peritonitis accounts for about 1-2% of all cases of tuberculosis, and the incidence having increased after the onset of the HIV epidemic.[7]

Generalized peritonitis may originate from subclinical or miliary hematogenous dissemination. Localized peritonitis may cause the direct extension from an abdominal lymph node, intestinal focus, or genitourinary tuberculosis. Rarely, the lymph nodes, omentum, and peritoneum become matted and can be palpated as a "doughy" irregular non-tender mass. Ascites and low grade fever commonly accompany this complication.[1] In a broad adult study, the triad of abdominal pain, abdominal swelling/ascites and fever are the most common findings of presentation.[8] In another study, which includes 45 children, abdominal distension (64%), weight loss (56%), pain (51%) and fever (47%) were reported as most common symptoms at admission.[9] In view of our patients, 2 had fever, 2 had weight loss and abdominal distention, one ascites, one diarrhea, and one abdominal pain at admission. However, acid fast staining is usually negative and cultures are positive in 30-40% of cases, making bacteriological confirmation of the AT very difficult.[7] We also could not demonstrate bacillus by Ziehl-Nielsen stain and could not gain in Loewenstein-Jensen media in none of our patients. Generally, findings of tuberculosis on chest x-ray were detected in approximately one-third of cases in a survey.[8] In another study, as high as 64% pulmonary findings suggesting tuberculosis was detected.[9] We explored chest findings that suggest

tuberculosis in 2 of our patients (pleurisy in one, and pulmonary findings that were visible only by HRCT in another). Elevated ERS and normochromic normocytic anemia often accompany tuberculous peritonitis,[3] but are of limited diagnostic importance in view of their nonspecificity. All 3 of our patients had anemia and elevated ESR. The tuberculin test gives a disappointing yield and could be negative in as many as half of the subjects with substantial population spectrum of energy[3] and was reported as 64% in a recent pediatric study.[9] We detected positive tuberculin test in only one of our patient. Advances in molecular techniques have provided a new approach to the rapid diagnosis of tuberculosis by nucleic acid probes and PCR.[10] However, little is known about the value of this approach for patients with TP. Polymerase chain reaction were studied in 2 of our patients and both were negative. A peritoneal fluid ADA value of over 30 IU/L has been reported to have a sensitivity of 93%, a specificity of 96%, and a positive predictive value of 93% in the diagnosis of AT. False-positive values have been noted in malignant ascites and collagen disease.[9,11] It was found significantly high in 3 out of 4 patient in a pediatric study.[11] However, there are not enough data in children. We could not measure ADA in our patients. Serum CA-125 levels on patients with TP are as high as ovarian cancers associated with peritoneal infiltration. In limited number of study, serum CA-125 levels have returned to normal after treatment.[6,12] We analyzed CA-125 in one of our patients and was detected with high level. This level approximately decreased to normal (from 183 U/ml to 35 U/ml) in one month after initiation of the treatment. Ultrasonography and CT were useful but not enough. Suffice to say that most cases of TP are not based on clinical or radiological grounds alone. Positive radiological findings that we use in the diagnosis were present in all of our patients, but they were not enough to rule out other diseases. Laparoscopy with direct biopsy is an excellent diagnostic method and must be considered for every patient with unexplained ascites.[13,14] Laparotomy or laparoscopy were applied to all of our patients and after pathologic examination specimens' diagnosis was made definite.

In a study covering 82 adults, a diagnostic delay of 11-127 days was detected and only 2 of 6 dead cases were diagnosed by autopsy.[15] Patient who presents with ascites was diagnosed within 2 weeks, patient presenting with hepatitis was diagnosed at the end of one month and mimicking Crohn disease at the end of 2 months. If there is no high suspicion, studies relevant to AT diagnosis may be delayed. Although it comes in mind, direct visualization of the bacillus for definitive diagnosis may not be possible all the time. Gain probability in culture is low and requires a long period. None of the diagnostic tools like PPD, ESR, ADA, PCR, CA-125, US and CT were unfortunately diagnostic or exclusive. In spite of recent technical advances, for definite diagnosis of AT, histopathologic evaluation of specimens obtained by laparotomy or laparoscopy is usually performed. However, probable complications of these procedures should be considered.

In conclusion, our study implicates that AT may mimic other diseases, diagnosis may be difficult and time consuming despite all recent advances, however, treatment usually give very good results after diagnosis. Erythrocyte sedimentation rate and CA-125 are valuable markers for diagnosis, but accordingly, these are rather valuable response to the treatment. We believe that there is a need of easy, rapid, acceptable, highly sensitive and specific alternative tools relevant to diagnosis.

References

1. Munoz F M, Starke J R. Mycobacterial Infections: Tuberculosis (Mycobacterium tuberculosis). In:Behrman ER, Kliegman MR, Jenson BH, editors. Nelson Textbook of Pediatrics, 17th ed. Philadelphia (PA). WB Saunders Co; 2004. pp. 958-972.
2. Demir K, Otken A, Kaymakoglu S, Dincer D, Besisik F, Cevikbas U, et al. Tuberculous peritonitis-reports of 26 cases, detailing diagnostic and therapeutic problems. ***Eur J Gastroenterol Hepatol*** 2001; 13: 581-585.
3. Al Muneef M, Memish Z, Al Mahmoud S, Al Sadoon S, Bannatyne R, Khan Y. Tuberculosis in the belly: a review of forty-six cases involving the gastrointestinal tract and peritoneum. ***Scand J Gastroenterol*** 2001; 36: 528-532.
4. Tzoanopoulos D, Mimidis K, Giaglis S, Ritis K, Kartalis G. The usefulness of PCR amplification of the IS6110 insertion element of M. tuberculosis complex in ascitic fluid of patients with peritoneal tuberculosis. ***Eur J Intern Med*** 2003; 14: 367-371.
5. Hillebrand DJ, Runyon BA, Yasmineh WG, Rynders GP. Ascitic fluid adenosine deaminase insensitivity in detecting tuberculous peritonitis in the United States. ***Hepatology*** 1996; 24: 1408-1412.
6. Mass MR, Comert B, Saglamkaya U, Yamanel L, Kuzhan O, Ateskan U, et al. CA-125; a new marker for diagnosis and follow-up of patients with tuberculous peritonitis. ***Dig Liver Dis*** 2000; 32: 595-597.
7. Hopewell PC. Overview of clinical tuberculosis. In: Bloom BR, editor. Tuberculosis, pathogenesis, protection and control, 1st ed. Washington (DC): American Society for Microbiology 1994. pp. 25-46.
8. Chow KM, Chow VC, Szeto CC. Indication for peritoneal biopsy in tuberculous peritonitis. ***Am J Surg*** 2003; 185: 567-573.
9. Saczek KB, Schaaf HS, Voss M, Cotton MF, Moore SW. Diagnostic dilemmas in abdominal tuberculosis in children. ***Pediatr Surg Int*** 2001; 17: 111-115.
10. Shawar RM, El-Zaatari F, Nataraj A, Clarridge JE. Detection of Mycobacterium tuberculosis by two-step polymerase chain reaction and nonisotopic hybridization methods. ***J Clin Microbiol*** 1993; 31:61-65.
11. Sathar MA, Simjee AE, Coovadia YM, Soni PN, Moola SA, Insam B, et al. Ascitic fluid gamma interferon concentrations and adenosine deaminase activity in tuberculous peritonitis. ***Gut*** 1995; 36: 419-421.

12. Vardereli E, Kebapçi M, Sariçam T, Pasaoglu O, Acikalin M. Tuberculous peritonitis of the wet ascetic type: clinical features and diagnostic value of image-guided peritoneal biopsy. ***Dig Liver Dis*** 2004; 36: 199-204.
13. Hossain J, Kinirons M, Lewis. Laparoscopy does have a role in tuberculous peritonitis. ***Br Med J*** 1996; 313: 1145-1146.
14. Gurkan F, Ozates M, Bosnak M, Dikici B, Bosnak V, Tas MA, et al. Tuberculous peritonitis in 11 children: clinical features and diagnostic approach. ***Pediatr Int*** 1999; 41: 510-513.
15. Lingenfelser T, Zak J, Marks IN, Stayn E, Halkett J, Price KS. Abdominal tuberculosis: still a potentially lethal disease. ***Am J Gastroenterol*** 1993; 88: 744-750.