

# Whole lung lavage with intermittent double lung ventilation

## A modified technique for managing pulmonary alveolar proteinosis

Raees Ahmed, MD, FCCP, Mobeen Iqbal, MD, FCCP, Sayed H. Kashef, MBBS, Mohammed I. Almommen, MBBS, FRCS.

---

### ABSTRACT

Whole lung lavage is still the most effective treatment for pulmonary alveolar proteinosis. We report a 21-year-old male diagnosed with pulmonary alveolar proteinosis by open lung biopsy and who underwent whole lung lavage with a modified technique. He showed significant improvement in clinical and functional parameters. The technique of intermittent double lung ventilation during lavage procedure keeps the oxygen saturation in acceptable limits in patients at risk for severe hypoxemia and allows the procedure to be completed in a single setting.

Saudi Med J 2005; Vol. 26 (1): 139-141

---

**P**ulmonary alveolar proteinosis (PAP) is a rare disease of the lung characterized by filling of the alveoli with a periodic acid-Schiff (PAS)-positive proteinaceous material. The filling of alveoli with proteinaceous material impairs gas exchange and causes hypoxemia and other clinical manifestations. The standard treatment of idiopathic variety of PAP is whole lung lavage (WLL) with normal saline.<sup>1</sup> Several modifications of the original technique described by Ramirez et al<sup>2</sup> have been successfully tried in patients with different degree of pulmonary impairment.

We report an interesting case of PAP of idiopathic variety who underwent bilateral WLL in a single setting with intermittent double lung mechanical ventilation. We think that by employing

intermittent double lung ventilation, we were able to prevent severe hypoxemia during the procedure.

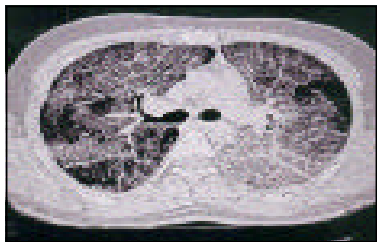**Case Report.** A 21-year-old previously healthy Saudi male was admitted to another hospital due to worsening dyspnea and cough for 4 weeks. He was treated with oral antibiotics for upper respiratory tract infection without any improvement. The patient, who was a student, denied any exposure to industrial dusts. He had a history of smoking for 6 years. He also denied any history of recent travel, alcohol abuse and use of recreational drugs. He was single and had no risk factors for human immunodeficiency virus infection. Chest x-ray (CXR) showed bilateral airspace disease.

---


From the Department of Medicine (Ahmed, Iqbal, Kashef), King Abdul Aziz National Guard Hospital, Alhasa, and the Department of Cardio Thoracic Surgery (Almommen), King Fahad Hospital, Hofuf, Kingdom of Saudi Arabia.

Received 19th July 2004. Accepted for publication in final form 27th September 2004.

Address correspondence and reprint request to: Dr. Mobeen Iqbal, Consultant Pulmonologist / Intensivist, Department of Medicine, King Abdul Aziz National Guard Hospital, PO Box 2477, Alhasa, 31982, Kingdom of Saudi Arabia. Tel. +966 (3) 5910000 ext. 3446. Fax. +966 (3) 5910001. E-mail: iqmob@yahoo.com



**Figure 1** - High resolution computed tomogram showing thickened interlobular septa and alveolar shadowing mimicking crazy paving appearance.



**Figure 2** - Eosinophilic and acellular material distending the alveolar spaces, staining positive for periodic acid Schiff's reagent.

Arterial blood gases (ABG) revealed severe hypoxemia (pO<sub>2</sub> 55 mm Hg) with high alveolar arterial gradient (A-a gradient) on FiO<sub>2</sub> 1. High resolution computed tomography of chest showed diffused alveolar shadowing with thickened intralobular structures and interlobular septa with air bronchograms mimicking crazy paving appearance (**Figure 1**). His routine investigations were only significant for elevated lactate dehydrogenase level (552 IU). Sputum microbiology including tuberculosis was negative. Routine immune work-up was unremarkable. Pulmonary function tests (PFTs) revealed severe restrictive ventilatory impairment. The patient clinically deteriorated and underwent limited thoracotomy and lung biopsy, which showed a picture of eosinophilic and acellular material distending the alveolar spaces, which stained positive for PAS reagent consistent with PAP (**Figure 2**). He was transferred to our hospital for further management. Based on his histopathology and clinical worsening, the decision for whole lung lavage (WLL) was made. In the operating room, the patient was intubated with double lumen endotracheal tube (ET) by the anesthesiologist. A flexible fiber optic bronchoscope was used to confirm proper tube position. The right lung was degassed for one minute and normal saline at body temperature was instilled from one liter reservoir bag, suspended at the height of approximately 2 feet above the bed. During the first 5 cycles, the patient was double-lung ventilated intermittently at the end of every cycle. Initially the recovered fluid was white, thick and creamy. Total of 9 cycles were required for the right lung before the effluent was completely clear. The left lung was lavaged the same way using 10 cycles to get the clear effluent. The technique of intermittent double lung ventilation was also used for the left side for the first 5 cycles. During the

procedure the patient's position was constantly changed to obtain the maximum passive recovery of fluid. Chest percussion was performed with the help of a vibrator by a trained respiratory therapist throughout the procedure.

After completion of the procedure, which took approximately 6 hours, the patient was re-intubated with single lumen ET tube, connected to mechanical ventilator and was transferred to the intensive care unit. Post WLL CXR showed gradual improvement, with immediate clinical improvement in FiO<sub>2</sub> requirement and A-a gradient. Patient was extubated on day 4 of post WLL. Subsequent PFTs showed significant improvement. His CXR and ABG on room air, repeated 2 weeks post procedure, were completely normal. He was counselled to quit smoking and was followed up as an outpatient.

**Discussion.** In recent years, a lot of research has been carried out on the pathogenesis of PAP. Most investigators postulate a decreased clearance of surfactant from the air spaces by alveolar macrophages, a process that may be dependent on granulocyte-macrophage colony stimulating factor (GM-CSF).<sup>3,4</sup> The postulated mechanism for the efficacy of WLL was the removal of abnormal surfactant protein and antibody against GM-CSF. The current standard of care is to perform WLL bilaterally in the same setting. The lavage is usually supplemented with positional changes and chest percussion therapy to maximize fluid return. In severely hypoxemic patients, lavage technique has been combined successfully with extra corporeal membrane oxygenation and high frequency jet ventilation in selected patients.<sup>5,6</sup> In a modified technique described by Bingisser et al<sup>7</sup> partially saline filled lung was manually ventilated to maximize the removal of proteinaceous material in a patient refractory to multiple sessions of

conventional lung lavage. Recently, fiber optic bronchoscopy has been used for sequential therapeutic lobar lavage in patients with PAP. Such technique was found to be successful in milder forms of disease and in patients with severe hypoxemia.<sup>8</sup>

The lavage technique utilized in our patient differed from Bingisser et al<sup>7</sup> in the sense that we regularly employed double lung mechanical ventilation for the first 5 cycles on both sides. Moreover, we mechanically ventilated both lungs at the end of drainage cycle while Bingisser et al<sup>7</sup> manually ventilated the lung after filling with 500 cc normal saline. This prevented not only severe hypoxemia but also enhanced the removal of proteinaceous material from alveoli. The physiological reason for improving oxygenation during this technique may be explained on the basis of better ventilation perfusion match in the lavaged lung due to intermittent ventilation.

In conclusion, idiopathic PAP should be kept in mind when evaluating patients with dyspnea and persistent bilateral infiltrates. The treatment of choice is whole lung lavage, which can be accomplished in a single setting. The technique of intermittent double lung ventilation may be used in patients at risk for developing severe hypoxemia during the lavage procedure.

## References

1. Perez IV A, Rogers RM. Enhanced alveolar clearance with chest percussion therapy and positional changes during whole-lung lavage for alveolar proteinosis. *Chest* 2004; 125: 2351-2356.
2. Ramirez RJ, Schultz RB, Dutton RE. Pulmonary alveolar proteinosis: a new technique and rationale for treatment. *Arch Intern Med* 1963; 112: 419-431.
3. Mazzone PJ, Thomassen MJ, Kavuru MS. Pulmonary alveolar proteinosis: Recent advances. *Seminars in Respiratory and Critical Care Medicine* 2002; 23: 115-126.
4. Trapnell BC, Whitsett JA, Nakata K. Pulmonary alveolar proteinosis: mechanism of disease. *N Eng J Med* 2003; 349: 2527-2538.
5. Cohen ES, Elpern E, Silver MR. Pulmonary alveolar proteinosis causing severe hypoxemic respiratory failure treated with sequential whole-lung lavage utilizing venovenous extracorporeal membrane oxygenation: A case report and review. *Chest* 2001; 120: 1024-1026.
6. Nakamura T, Ogasawara T, Shinjo K, Sako C, Suzuki M. Pulmonary alveolar proteinosis successfully treated by a modified lavage technique using high-frequency jet ventilation. *Nihon Koryu Gakkai Zasshi* 2001; 39: 514-518.
7. Bingisser R, Kaplan V, Zollinger A, Russi EW. Whole-lung lavage in alveolar proteinosis by a modified lavage technique. *Chest* 1998; 113: 1718-1719.
8. Cheng SL, Chang HT, Lau HP, Lee LN, Yang PC. Pulmonary alveolar proteinosis: treatment by bronchofiberscopic lobar lavage. *Chest* 2002; 122: 1480-1485.