for treatment and 23% for diagnosis. Although the reason for referral were written in 56.3% of the cases, it was inappropriate in 27.2% of the documents. Those were comparable with the results of Jaralla[2] who found that 25% of the reasons for referral was inappropriate.

Most referred cases needs to be checked at the center before referral. This emphasizes the fact that missing components are important since most of the cases referred to the medical pediatrics, and other department could have been managed at the public health care units. The vital signs, and basic investigations and the treatment given should be recorded before referring such cases. In our study, the vital signs were not recorded in 92.3%, which was greater than the 81% found by McGlade et al.[4] The investigations were not recorded in 83% of the cases, although facilities were available in the laboratory of the health institution. An example to these are the general and microscopic examinations, which were available but not recorded in the cases of malaria and the fasting blood sugar level was not recorded for diabetic patients. Kieran et al[4] found that 82% of the investigation were not recorded. There are some cases of trachoma referred to the ophthalmology clinic. Although trachoma diagnosis does not need sophisticated facilities but only skill. The health professionals who did not diagnose trachoma therefore, did not offer treatment available in the public health care units. Both oral sulphonamide and tetracycline eye ointment are always available in all unit pharmacies.

The outcome of poor quality referral letters will lead to the overload of cases that could have been managed at the centers. The health professionals will gradually lose their medical knowledge and skills, while patients might lose confidence in their health care providers. Poor referral letters will lose their value as an important means of communication between physicians at the centers and other units in the hospitals. This will end in the direct and indirect financial outlay by the referred patient. Therefore, health professionals need encouragement to improve the quality of their referral letters. It is also essential to train health professionals to write ideal referral letters and similarly train health care providers to improve their skills in managing the cases at their centers. Health professional should be advised to use properly their units laboratory and pharmacy facilities before referral. They have to design and distribute a standardized "fill-in-space" card and provide facilities for typing referral letters. This recommendations can be carried out by the ministry of health.

Received 31st May 2004. Accepted for publication in final form 26th July 2004.

From the Department of Obstetrics and Gynecology (Dafallah), Department of Public Health (Yousif), Department of Community Medicine and Health Education (Idris), Faculty of Medicine, University of Gezira, Wad Medani, Sudan. Address correspondence and reprint requests to Dr. Saad E. Dafallah, Associate Professor, Department of Obstetrics and Gynecology, Faculty of Medicine, University of Gezira, PO Box 20, Wad Medani, Sudan. Tel. +249 (511) 43415.

References

1. Westerman RF. A study of communication between general practitioners and specialist. ***Br J Gen Pract*** 1990; 40: 445-449.
2. Jarallah J. The quality of referral letters in two health centers in Riyadh. ***Ann Saudi Med*** 1991; 11: 658-662.
3. Grace JF, Armstrong D. Reasons for referral to hospital, extent of agreement between the perception of patients, general practitioner and consultant. ***Fam Med*** 1986; 653: 143-147.
4. McGlade KJ, Bradley T, Murphy GJ, Lundy GJ. Referral to hospital by general practitioners: a study of compliance and communication. ***Br Med J*** 1988; 297: 1246-1248.

Uterine prolapse immediately after labor

Mesut A. Unsal, *MD,* ***Ulku Zengin,*** *MD,*
Mehmet Ozeren, *MD,* ***Hasan Bozkaya,*** *MD.*

Uterine prolapse during pregnancy is a relatively rare complication. Furthermore, its occurrence during labor or early postpartum period is exceedingly rare.[1] While uterine prolapse during pregnancy is a well known entity, there is no information regarding uterine prolapse at labor so far. Although occurring during labor and having similar appearance to uterine inversion, the clinical prognosis is not as serious as uterine inversion.

A 30-year-old Caucasian woman, gravida 2 para 2, was presented to our emergency clinic with soft tissue prolapse at the vaginal introitus immediately after labor. There was no preceding history of uterine prolapse in her pregnancy. She uneventfully delivered a 3200 g male infant in the car on a countryside road to a local hospital. Four years ago, she had an uncomplicated delivery of a full term 3300 g infant. Her general condition was good. On physical examination, there was no palpable mass in the abdomen. Initially, the mass was thought to be an inverted uterus, but pelvic examination revealed a complete uterine prolapse with the cervix outside the introitus according to the grading scheme of Baden et al.[2] The uterus and cervix were edematous, desiccated, dark blue-red and covered with bloody secretions (**Figure 1**). Her vital signs and complete blood count evaluation were normal. Prophylactic antibiotics were started with

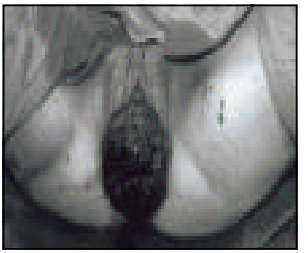

Figure 1 - The uterus and cervix that is edematous, desiccated, dark blue-red and covered with bloody secretions.

clindamycin 600 mg intravenously 4 times daily and gentamycin 80 mg intravenously 3 times daily. Tetanus vaccine and immunoglobulin were also administered. Her prolapsed uterus was manually reduced to its normal position and then 1% oxytocin solution infusion was started to promote uterine contractility. She was placed at Trendelenburg position with strict bed rest. On the second day, oxytocin was stopped and methylergobasine 0.125 mg 3 times daily was started and continued for 3 days, per orally. She was discharged on the 8th postpartum day and no prolapse of the uterus was noted during the follow up period of 6 months.

The cause of uterine prolapse is unclear, but in several predisposing factors (such as, childbirth trauma, congenital and developmental weakness, and the influence of menopause), failure of the supportive ligaments leading to prolapse of the uterus and vaginal vault is thought to be the most important factor. Although the diagnosis of uterine prolapse is usually based on clinical signs and symptoms, it is clinically important to differentiate it from acute uterine inversion. The classical signs of acute total uterine inversion are: shock incompatible with the quantity of blood loss, absence of uterine fundus on abdominal examination and no visualization of the cervix.[3] Our case was hemodynamically stable and the cervix was visible, which confirmed uterine prolapse. Delayed treatment leads to impaired lymphatic and venous drainage, resulting in acute edema of the protruding uterus and cervix, thus, its reduction is difficult without general anesthesia. Delayed treatment also result in mechanical trauma that causes ulceration and infection of the edematous cervix and even severe urinary tract infection due to acute urinary retention.[4] Considering that the woman had delivered the baby under non-sterile condition, prophylactic antibiotics and tetanus immunization were used, without delay in diagnosis.

Differently from acute uterine inversion, manual manipulation without general anesthesia before the development of excessive edema, slight Trendelenburg position with bed rest is the treatment modality in successful reduction of prolapse, and this will protect the patient from above discussed complications. Agents such as oxytocin or methylergobasine are then given to produce uterine contraction to prevent a second prolapse. Since perineal descent on straining is almost always evident immediately after vaginal delivery and returns to normal position during the subsequent 2 months,[5] a control examination 2 months after vaginal delivery was recommended, reminding that on this case, there is a possibility of recurrence on the next pregnancies.

Received 30th June 2004. Accepted for publication in final form 27th September 2004.

From the Department of Gynecology and Obstetrics, Karadeniz Technical University, Trabzon, Turkey. Address correspondence and reprint requests to Dr. Mesut A. Unsal, Department of Gynecology and Obstetrics, Faculty of Medicine, Karadeniz Technical University, Trabzon 61080, Turkey. Tel. +90 (462) 3775494. Fax. +90 (462) 3775498. E-mail: mesutunsal@meds.ktu.edu.tr

References

1. Schinfeld JS. Prolapse of the uterus during pregnancy: a report of two cases and review of management. ***Am J Obstet Gynecol*** 1977; 12: 587-588.
2. Bland DR, Earle BB, Vitolins MZ, Burke G. Use of the Pelvic Organ Prolapse staging system of the International Continence Society, American Urogynecologic Society, and Society of Gynecologic Surgeons in perimenopausal women. ***Am J Obstet Gynecol*** 1999; 181: 1324-1327; discussion 1327-1328.
3. Hostetler DR, Bosworth MF. Uterine inversion. ***J Am Board Fam Pract*** 2000; 13: 120-123.
4. Piver MS, Spezia J. Uterine prolapse during pregnancy. ***Obstet and Gynecol*** 1968; 32: 765-769.
5. Tsunoda A, Shibusawa M, Kamiyama G, Kusano M, Shimuzu Y, Yanaihara T. The effect of vaginal delivery on the pelvic floor. ***Surg Today*** 1999; 29: 1243-1247.

Spontaneous bacterial peritonitis due to *Hafnia alvei* in a patient with peritoneal mesothelioma

Fusun Z. Akcam, *MD,* ***Mehmet Isler,*** *MD,*
Omer R. Tarhan, *MD,* ***Hasan E. Eroglu,*** *MD.*

Spontaneous bacterial peritonitis (SBP) is a frequent and severe complication of cirrhotic patients with ascites. It has also been reported in patients with chronic active hepatitis, acute viral hepatitis, congestive heart failure, metastatic malignant disease, systemic lupus erythematosus, lymphedema, and rarely without any underlying disease.[1] Most patients with SBP have symptoms