

Al-Aqeel Sewairi syndrome, a new autosomal recessive disorder with multicentric osteolysis, nodulosis and arthropathy

The first genetic defect of matrix metalloproteinase 2 gene

Aida I. Al-Aqeel, MD, FRCP.

ABSTRACT

Objective: We report a distinctive autosomal recessive multicentric osteolysis in Saudi Arabian families with distal arthropathy of the metacarpal, metatarsal and interphalangeal joints, with ultimate progression to the proximal joints with decreased range of movements and deformities with ankylosis and generalized osteopenia. In addition, they had large, painful to touch palmar and plantar pads, Hirsutism and mild dysmorphic facial features including ptosis, a narrow nasal bridge, bulbous nose and micrognathia.

Methods: Using a genome-wide search for microsatellite markers from 11 members of the family from the Armed Forces Hospital and King Faisal Specialist Hospital and Research Centre, Riyadh, Kingdom of Saudi Arabia, localized the disease gene to chromosome 16q12-21. Haplotype analysis with additional markers narrowed the critical region to 1.2cM and identified the matrix metalloproteinase 2 (MMP-2), (gelatinase A, collagenase type IV, EC 3.4, 24,24) gene as a disease candidate at Mount Sinai School of Medicine, New York, United States of America in April 2000.

Results: Some affected individuals were homoallelic

for a nonsense mutation (TCA>TAA) in codon 244 of exon 5, predicting the replacement of a tyrosine residue by a stop codon in the first fibronectin type II domain (Y244X). Other affected members had a missense mutation in exon 2 arginine 101-histidine (R101H) leading to no MMP-2 enzyme activity in serum or fibroblast or both of affected individuals. In other affected members, a non-pathogenic homoallelic GT transversion resulted in the substitution of an aspartate with a tyrosine residue in codon 210 of exon 4 (D210Y). The MMP-2-null mouse has no developmental defects, but are small, which may reflect genetic redundancy.

Conclusion: The discovery that deficiency of this well-characterized gelatinase/collagenase results in an inherited form of an osteolytic and arthritic disorder provides an invaluable insights for the understanding of osteolysis and arthritis and is the first genetic evidence that MMP2 deficiency is important in growth and development.

Saudi Med J 2005; Vol. 26 (1): 24-30

From the Department of Pediatrics, Armed Forces Hospital, Riyadh, Kingdom of Saudi Arabia.

Received 18th February 2004. Accepted for publication in final form 27th March 2004.

Address correspondence and reprint request to: Dr. Aida I. Al-Aqeel, Consultant Pediatrician, Inborn Errors of Metabolism, Endocrinology and Genetics, Department of Pediatrics, Armed Forces Hospital, PO Box 7897, Riyadh 11159, Kingdom of Saudi Arabia. Tel. +966 (1) 4791000 Ext. 6845. Fax. +966 (1) 4762121. E-mail: aidaibrahim@hotmail.com

The multicentric osteolysis disorders are a group of inherited disorders of the bone characterized by progressive bone and joint destruction leading to skeletal deformities with functional impairment. They can be autosomal recessive and dominant with or without nephropathy and mental retardation.¹ These disorders are classified by the international skeletal dysplasia society into 4 groups (Table 1).² They are notable for interphalangeal joint erosions that mimic severe juvenile rheumatoid arthritis (online mendelian inheritance in man (OMIM) 166300, 259600, 259610, and 277950). The development of a multicellular organism is dependent upon an extracellular matrix (ECM), which facilitates the organization of cells into tissues and organs.³ The turnover of ECM is carried out by specialized proteinases. Among these are Matrix metalloproteinase (MMPs).⁴ Matrix metalloproteinase are a family of zinc and calcium dependent endopeptidases that are active in neutral pH, which also degrades non-matrix proteins.^{5,6} Disruption of their activity leads to many disease processes.³ Matrix metalloproteinase 2 gene (MMP-2) encodes a member of the MMPs that degrades matrix proteins and are important mediators of connective tissue remodeling.⁷ Matrix metalloproteinase 2 is involved in hydrolysis of gelatin and type IV collagens, the major structural component of the basement membrane, as well as elastin, laminin, fibronectin, aggrecan and fibrillin.⁷ It is believed to be involved in normal collagen turnover⁷ and tumor cell invasiveness.⁸ Matrix metalloproteinase 2 gene increased activity has been implicated in many disease processes, for example

arthritis,^{9,10} tumor invasion and metastasis,¹¹ and angiogenesis.¹² However, no disease process has been implicated with MMP-2 deficiency. The identification of this unique molecular defect in MMP2 gene, is the first genetic evidence that defect in proteolysis of the ECM results in osteolysis, nodulosis and arthropathy, and provides insights into the roles of MMP-2 and the ECM in the pathophysiology of bone and joint development.

Methods. Clinical features. Two offspring of a consanguineous Saudi Arabian family with 6 affected members in 3 branches of the family where parents are first cousins were reported,^{13,14} both of them develop symptoms in the first year of life. Other 5 affected members were reported in other Saudi Arabian families where parents are also first cousins.¹⁵ All these patients develop symptoms in the first 2 years of life with progressive painful swellings of the interpharyngeal joints of the hands and feet, which progressively involved the more proximal joints with increasing age with decreased range of movement and deformities of the hands, feet, wrists and other joints. There were flexion contractures of interphalangeal joints with fusiform swelling and tenderness of the hands, feet, wrists and ankles.¹³⁻¹⁵ (Figures 1 & 2) These patients have mild dysmorphic features with proptosis, bulbous nose, narrow nasal bridge and hypertelorism.¹³⁻¹⁵ They also have generalized hirsutism,¹⁴ some of them are mildly mentally retarded.¹⁵ (Figure 1) A striking feature of the syndrome was the development of painful subcutaneous pads on the

Table 1 - International skeletal dysplasia registry classification of the multicentric osteolyses.

Types of multicentric osteolysis	Mode of inheritance	OMIM	Present at birth	Chromosomal locus
Multicentric predominantly carpal and tarsal in the hand				
Multicentric carpal-tarsal osteolysis with and without nephropathy. Shinohara carpal-tarsal osteolysis	AD	166300		
Multicentric predominantly carpal-tarsal and interphalangeal				
Francis syndrome	AR	221800		
Winchester syndrome	AR	277950		
Torg syndrome	AR	259600		
Whyte Hemingway carpal-tarsal phalangeal osteolyses	AD	-		
Al-Aqeel Sewairi syndrome	AR	605156		16q ²³
Predominantly distal phalanges				
Hadju-Cheney syndrome	AD	102500		
Giacci familial neurogenic acroosteolyses	AR	201300		
Mandulo acral syndrome	AR	-		
Predominantly involving diaphyses and metaphyses				
Familial expansible osteolysis	AD	174810	+	18q ¹¹⁻²²
Juvenile hyaline fibromatosis	AR	228600		
OMIM - online mendelian inheritance in man, AR - autosomal recessive, AD - autosomal dominant				

hands and feet which develop when these children start to walk and progressively increasing. Magnetic resonance imaging of these nodules shows rim enhancement near the margins, which suggest fibro collagenous nature¹⁴ (Figure 2) scarring with keloid formation was noted after the biopsy of these nodules. (Figure 1) Laboratory evaluations including complete blood count, serum chemistries, kidney, liver, bone, rheumatology panels, serum and urine metabolic studies including enzyme studies for Farber lipogranulomatosis were all normal.^{14,15} Twenty-four hour urine collection for creatinine clearance, proteinuria and urinary electrolytes were normal with normal renal ultrasound and functional scan. Radiological evaluation of these children have revealed generalized osteopenia, fusiform swelling of fingers with hyperextension of metacarpal phalangeal joints and flexion of intraphalangeal joints, osteolysis of carpal and tarsal bones, which progressively lead to their destruction and metacarpal, metatarsal, phalangeal and interphalangeal joints with increasing age as well as ankylosis of the other joints, with cortical thinning, epiphyseal enlargement and loss of joint space with pelvic distortion^{3,14} (Figure 2). Joint biopsy reveals a normal synovium with no evidence of inflammation, while biopsy of the nodule showed fibrous fatty tissue.¹⁴ (Figures 3 & 4) Linkage analysis on genomic DNA from blood samples obtained after informed consent. Cell culture and zymography were carried out by standard procedures.¹⁶

Results. Using polymerase chain reaction-based microsatellite markers, a genome wide search for homozygosity by descent was performed on 3 affected Saudi Arabian families. The disease gene was localized to chromosome 16q12, with a maximum lod score of 4.59 for marker D16S3253. Haplotype analysis narrowed the critical region to 13 cM interval between markers D16S3396 and GATA67G11. Further, haplotype analysis narrowed the critical region to 1.2 centimorgan (cM) region that spans the gene encoding MMP-2.¹⁶⁻¹⁸ In one family, all affected individual are homo allelic for a nonsense mutation (TCA TAA) in codon 244 of exon 5 of the gene, predicting the replacement of tyrosine residue by a stop codon (Y244X).^{14,16-18} In the second family as G A transition in codon 10 of exon 2, predicting the replacement of an arginine with histidine (R101H).^{15,16} In the third family no inactivating mutations were found in the exonic sequences of the gene, such mutation might be present in the promoter or intrinsic sequences.^{15,16} However, a non-pathogenic homoallelic G T polymorphism resulted in the substitution of an aspartate with tyrosine residue (D210Y), which was also present in 50 unaffected members of the tribe.^{15,16} all affected members had no serum and fibroblastic MMP-2

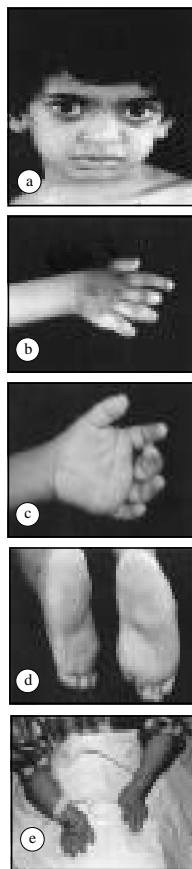


Figure 1 - The clinical features showing (a) Index patient at 4 years. Note the bilateral proptosis, narrow nasal bridge, bulbous nose and small chin. (b) Fusiform swelling of fingers with flexion of interphalangeal joints and hyperextension of metacarpophalangeal joints. Note the hirsutism of the dorsum on the hand and arm. Keloid formation at the site of nodule biopsy. (c & d) Subcutaneous painful nodules at the palmar and plantar aspects of the hands and feet. (e) Another patient at the age of 20 years. Note the deformed hands, with elbows and wrists distorted with flexion of elbows and foreshortening of all fingers.

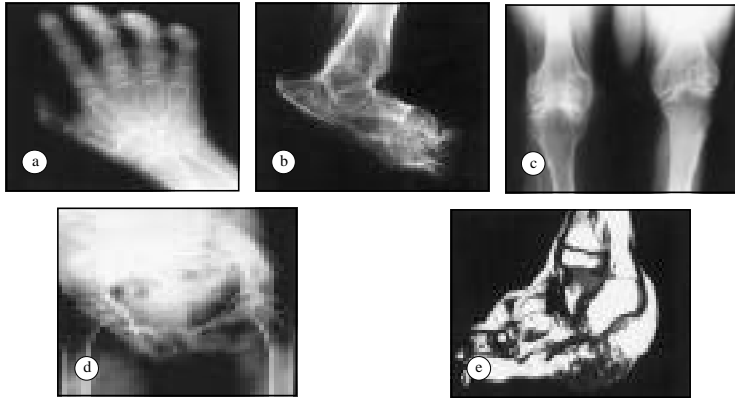


Figure 2 - Radiologic features showing (a) hands (index patient at 4-years), with osteopenia, fusiform swelling of fingers and osteolysis of the carpal, metacarpal, bones and interphalangeal joints. Note the proximal tapering, distal notching of the metacarpal bones, with severe cortical thinning and undermineralization with apparent increase in the caliber of the metacarpal bones. Shadowing by the subcutaneous palmar nodules is evident. Another patient at the age of 20-years. (b) Feet with complete chaotic destruction and loss of all tarsal bones, ankylosis of the ankle joint, metatarsal phalangeal joints, distal tapering of the metatarsals with loss of fifth digit and overlying tissue. Marked osteopenia with thickening of subcutaneous tissues over the tibia fibula. (c) Knees are markedly osteopenic with cortical thinning, epiphyseal enlargement, and reduced joint space. (d) Pelvis is markedly distorted, both hips are osteopenic, with irregularities of the femoral heads, protruding acetabula but no erosive changes. (e) Magnetic resonance imaging of the left foot (index patient), low signal intensity of the large subcutaneous nodules, with rim of enhancement extending all around the nodule in the immediate subcutaneous tissue on T2 sequences.

gelatinolytic activity, while parents, heterozygote siblings, had half-normal levels of MMP-2 activity (Figures 5 & 6).¹⁶⁻¹⁸

Discussion. Inherited multicentric, osteolysis, nodulosis and arthropathy (MONA), nodulosis, arthropathy, osteolysis, idiopathic osteolysis-Saudi type, Al-Aqeel Sewairi Syndrome (OMIM) # 605156¹⁹ is a distinctive autosomal recessive multicentric osteolysis disorder in which crippling arthritis is associated with carpal and tarsal resorption, severe osteoporosis, distinctive facies, and palmar and plantar subcutaneous nodules. It was recently identified by 2 independent groups in eleven affected offspring of 6 consanguineous Saudi Arabian Families.¹³⁻¹⁵ Since the first description of the "vanishing bone" disease by Jackson,²⁰ a number of clinically distinguished forms have been described.²¹ These disorders differ from each other in the mode of transmission, clinical features, and the extent and anatomical distribution of osteolysis.^{1,21} On these basis the International Skeletal Dysplasia Registry has classified them into four groups.² (Table 1) The group with carpal, tarsal,

and interphalangeal joint destruction include Torg (OMIM # 259600), Francois (OMIM # 221800), Winchester (OMIM # 277950), and Whyte Hemingway syndrome.² It also includes MONA or Al-Aqeel Sewairi syndrome (OMIM # 605156),¹⁹ as the features of this syndrome overlap with many phenotypic features of these syndromes, mainly Torg.¹⁴ The matrix metalloproteinase (MMPs) also called matrixins, a family of zinc and calcium dependent and membrane, associated endopeptidase that are active at neutral Ph. Each member has specificity for a subset of extracellular matrix (ECM) molecules; collectively they catalyze the proteolysis of all components of ECM³ as well as other extracellular non-matrix proteins.²² The expression of most matrixins is transcriptionally regulated by growth factors, hormones, cytokines, and cellular transformation.^{23,24} To date 22 MMPs are identified.^{22,25}

The development of a multicellular organism is dependent upon an ECM, which facilitates the organization of cells into more complex functional units: tissues and organs. The extracellular matrix is the glue that holds cells together, and provides

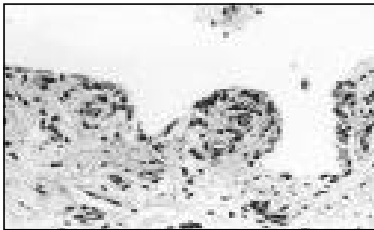


Figure 3 - Biopsy of the metacarpal phalangeal joint showing normal synovium with normal mesothelium.

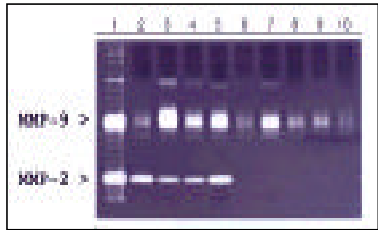


Figure 5 - Gelatin zymography of control and affected serum samples. Lane 1, MMP2 and MMP9 zymography standards (Chemicon International); 2 serum from an unaffected, unrelated individual; 3-5, sera from unaffected parents and siblings; 6-10, sera from affected children. MMP - matrix metalloproteinase. (Source: *Nature Genetics* 2001; 28: 261-265)



Figure 4 - Biopsy of the nodule on the dorsum of the hand showing fibrofatty tissue.




Figure 6 - Gelatin zymography of control and patient fibroblast conditioned medium. Lane 1, mixture of MMP2 and MMP9 zymogram standards; 2, serum from unrelated, unaffected individual; 3 and 4, sera from 2 affected members. MMP - matrix metalloproteinase. (Source: *Nature Genetics* 2001; 28: 261-265)

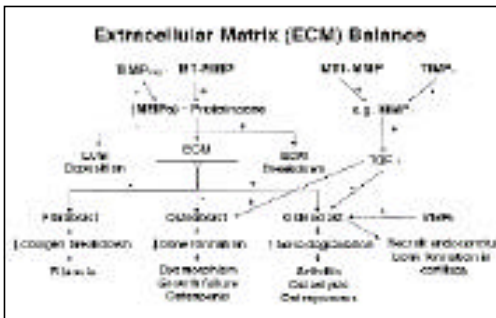


Figure 7 - Matrix metalloproteinases regulation and extracellular matrix balance. MT - membrane type, MMPs - matrix metalloproteinases, TIMPs - tissue inhibitors metalloproteinases, TGF- - transforming growth factor beta, ECM - extracellular matrix.

texture, strength and integrity to the tissues. Diversity in tissue function depends not only upon diversity in cell types but also upon diversity in the composition of the ECM. Bone, for example, is comprised of one type of ECM; that of lung and brain is quite different. It has become increasingly apparent that the ECM harbors informational cues that direct cell behavior. In fact, the interaction of a cell with its ECM regulates some of the most fundamental cellular processes, such as growth, survival, differentiation, motility, signal transduction and changing shape.²⁶ Matrix metalloproteinase participate in many normal biological processes (for example embryonic development, blastocyst implantation, organ morphogenesis, nerve growth, ovulation, cervical dilatation, postpartum uterine involution, endometrial cycling, hair follicle cycling, bone remodeling, wound healing, angiogenesis, apoptosis, for example)^{11,12,22,27-29} and pathological processes (for example arthritis, cancer, cardiovascular disease, nephritis, neurological disease, breakdown of blood brain barrier, periodontal disease, skin ulceration, gastric ulcer, corneal ulceration, fibrosis of the liver and lung.^{11,22,25,27,30,31} Matrix metalloproteinase are regulated at different levels. These MMPs are synthesized as pre pro-enzymes and secreted as active pro-MMPs in most cases.^{25,32-34} Which are activated by MT-MMPs (Membrane type matrix metalloproteinases). However, inhibition of MMPs is by endogenous tissue inhibitors (TIMPs). Currently, 4 of them are known. Membrane type (1)-MMP is a membrane associated matrix metalloproteinase that is highly expressed in osteocartilaginous and musculotendinous structure³⁵ and may function as a pericellular activator of MMP-2 in atrimeric complex with TIMP-2 and MMP-2.³⁶⁻³⁸ (Figure 7) MMP-2 is thought to regulate the activity of a critical growth factor, transforming growth factor-Beta (TGF- β). TGF- β -signaling mediates the coupling of the reciprocal activities of bone formation and resorption by influencing the maturation of osteocyte and enhancing the activity of osteoclasts.³ Physiologically TGF- β , may coordinate osteoclast activity by recruiting osteoclasts to existing site of resorption. Pathologically TGF- β -induced osteoclast recruitment may be critical for expansion of primary and metastatic tumors in bone.³⁹ Plasmin, elastase, MMP-9 and MMP-2 activates TGF- β by proteolytically cleaving the latent associated peptide, for example latent TGF- β -binding protein (LTBp1) to produce 125-165-Kda fragment which is the physiological mechanism for the release of active TGF- β from ECM-bound stores.^{40,41} Lack of MMP-2 may therefore affect bone formation and homeostasis through modulating the level of active TGF- β . (Figure 7) The ECM

remodeling is important for morphogenesis and homeostasis. The balancing act of ECM deposition and break down is very critical, therefore, MMP-2 deficiency leads to an imbalance between the breakdown and deposition of the ECM.¹ Although MMP-2 null mice have no developmental defects (which may reflect genetic redundancy), mice with targeted inactivation of the MT1-MMP gene have many of the same features as people with multicentric osteolysis and arthritis syndrome.⁴² As the MT1-MMP activates MMP-2, it is not surprising that deficiency in either of these enzymes-albeit in different species can result in similar defects. Deficiency of MT1 in mice results in a decrease of collagen breakdown by fibroblasts in the skin and osteoblasts, a decrease in bone formation, and an increase in the number of osteoclasts (especially at ectopic sites). Tissue fibrosis may therefore be attributed to impaired function of fibroblasts, arthritis and osteolysis to increased osteoclastic activity; and craniofacial dysmorphism and osteopenia to impaired function of osteoblasts (Figure 7).

Where it is tempting to treat these disorders, there is no specific treatment available for the multicentric osteolysis. Our patients responded well to prednisolone 5-10 mg OD and methotrexate 5 mg q/weekly with improvement of their joints pain, contracture and nodulosis with normal growth while osteolysis did not improve but was non-progressive. Their osteopenia responded well to pamidronate 2 mg/kg 2 monthly infusions. However, some patients reported bone pain, which required them to discontinue the infusion. Other future treatment research strategies, for example targeted enzyme therapy with MMP-2 as MMP-2 deficiency is found in these patients, or the use of TGF- β as MMP-2 activates TGF- β , or the use of MT1-MMP or TIMP-2 as they activate MMP-2 in a trimeric complex are still to be explored. The discovery of this new disease entity represents the first hereditary disease resulting from MMP-2 deficiency and is the first genetic evidence that the proteolysis of the ECM mediates human growth and development.

References

1. Urlus M, Roosen P, Lammens J, Victor J, De Smet L, Molenaers G, et al. Carpal tunnel osteolysis. Case report and review of the literature. *Genet Couns* 1993; 4: 25-36.
2. Lachman RS. International nomenclature and classification of the osteochondrodysplasias. *Pediatr Radiol* 1997; 28: 737-744.
3. Vu Thiennu H. Don't mess with the matrix. *Nat Gen* 2001; 28: 202-203.
4. Yu AE, Murphy AN, Stetler-Stevenson WG. In: Matrix Metalloproteinases. Academic Press, San Diego Parks (CA): WC and Mecham; 1999. p. 85-113.
5. Agnihortri R, Crawford HC, Haro H, Matrisian LM, Havrda MC, Liaw L. Osteopontin, a novel substrate for matrix metalloproteinase-3 (stromelysin-1) and matrix metalloproteinase-7 (matrilysin). *J Biol Chem* 2001; 276: 28261-28267.

6. McCawley LJ, Matisian LM. Matrix metalloproteinases: they're not just for matrix anymore! *Curr Opin Cell Biol* 2001; 13: 534-540.
7. Creemers LB, Jansen ID, Docherty AJ, Reynolds JJ, Beertsen W, Everts V, Gelatinase A (MMP-2) and cysteine proteinases are essential for the degradation of collagen in soft connective tissue. *Matrix Biol* 1998; 17: 35-46.
8. Chen WT. Proteases associated with invadopodia, and their role in degradation of extracellular matrix. *Enzyme Protein* 1996; 49: 59-71.
9. Brinckerhoff CE. Joint destruction in arthritis: metalloproteinases in the spotlight. *Arthritis Rheum* 1991; 34: 1073-1075.
10. Glegg PD, Carter SD. Matrix metalloproteinase-2 and -9 are activated in joint diseases. *Equine Vet J* 1999; 31: 324-330.
11. Stetler-Stevenson WG. The role of matrix metalloproteinases in tumor invasion, metastasis and angiogenesis. *Surg Oncol Clin N Am* 2001; 10: 383-392.
12. Sang QX. Complex role of matrix metalloproteinases in angiogenesis. *Cell Res* 1998; 8: 171-177.
13. Al Aqeel A, Sewairi W. An autosomal recessive syndrome with nodular arthropathy and acrolysis. *Am J Hum Gen* 1999; 65: A140.
14. Al Aqeel A, Sewairi W, Edress B, Gorlin RJ, Desnick R, Martignetti J. Inherited Multicentric osteolysis with arthritis: A variant resembling Torg Syndrome in a Saudi family. *Am J Med Gen* 2000; 93: 11-18.
15. Al Mayouf SM, Majeed M, Hugosson C and Bahabri S. New form of idiopathic osteolysis: nodulosus, arthropathy and osteolysis (NAO) syndrome. *Am J Med Genet* 2000; 93: 5-10.
16. Martignetti JA, Al Aqeel A, Sewairi W, Boumah CE, Kambouris M, Mayouf S, et al. Mutation of the matrix metalloproteinase 2 gene (MMP2) causes a multicentric osteolysis and arthritis syndrome. *Nat Gen* 2001; 28: 261-265.
17. Al-Aqeel AI, Al Sewairi WM, Desnick RJ. Al Aqeel Syndrome, a new autosomal recessive disorder with multicentric osteolysis and arthritis with a novel mutation of matrix metalloproteinase 2 gene (MMP-2). *AJHG* 2001; 69: 592.
18. Martignetti JA, Al Aqeel AI, Al Sewairi W, Boumah CE, Kambouris M, Mayouf S, et al. The first matrix metalloproteinase disease: MMP-2 deficiency results in a multicentric osteolysis syndrome. *AJHG* 2001; 69: 189.
19. Al-Aqeel AI. Al-Aqeel Sewairi syndrome, a new autosomal recessive disorder with multicentric osteolysis, nodulosus, arthropathy (MONA), OMIM #605156. In: Atlas of Metabolic Diseases. London (UK): Arnold Health Sciences. (In press)
20. Jackson JBS. A boneless arm. *Boston Med Surg J* 1838; 18: 368-369.
21. Rosenbaum T. Idiopathic multicentric osteolysis. *Am J Roentgenol* 1976; 126: 23-31.
22. Morgunova E, Tuuttila A, Bergmann U, Isupov M, Lindqvist Y, Schneider G, et al. Structure of human pro-matrix metalloproteinase-2: activation mechanism revealed. *Science* 1999; 284: 1667-1670.
23. Nagase H. In: Zinc Metalloproteinase in Health and Disease. Hooper NM, editor. London (UK): Taylor and Francis; 1996. p. 153-204.
24. Fini ME, Cook JR, Mohan R, Brinckerhoff CE. In: Matrix metalloproteinases. Parks WC, Mechner, RP, editors. San Diego (CA): Academic Press; 1998. p. 299-356.
25. Matrix metalloproteinases and TIMPS. Woessner JF, Nagase H, editors. Chap. XIII. Oxford (UK): Oxford University Press; 2000. p. 223.
26. Werb Z and Chin JR. Extracellular matrix remodeling during morphogenesis. *Ann N Y Acad Sci* 1998; 857: 101-108.
27. Schnaper HW, Grant DS, Stetler-Stevenson WG, Fridman R, D'Orazi G, Murphy AN, et al. Type IV collagenase(s) and TIMPs modulate endothelial cell morphogenesis in vitro. *J Cell Physiol* 1993; 156: 235-246.
28. Pilcher BK, Wang M, Qin XI, Parks WC, Senior RM, Welgus HG. Role of matrix metalloproteinases and their inhibition in cutaneous wound healing and allergic contact hypersensitivity. *Ann N Y Acad Sci* 1999; 878: 12-24.
29. Bord S, Horner A, Hembry RM, Compston JE, Stromelysin-1 (MMP-3) and Stromelysin-2 (MMP-10) expression in developing human bone: potential roles in skeletal development. *Bone* 1998; 23: 7-12.
30. Birkedal-Hansen H. Role of matrix metalloproteinases in human periodontal diseases. *J Periodontol* 1993; 64: 474-484.
31. Cockett ML, Murphy G, Birch ML, O'Connell JP, Crabbe T, Millican AT et al. Matrix metalloproteinases and metastatic cancer. *Biochem Soc Symp* 1998; 63: 295-313.
32. Van Wart HE and Birkedal-Hansen H. The cysteine switch: a principle of regulation of metalloproteinase activity with potential applicability to the entire matrix metalloproteinase gene family. *Proc Natl Acad Sci USA* 1990; 87: 5578-5582.
33. Morgunova E, Tuuttila A, Bergmann U, Isupov M, Lindqvist Y, Schneider G, et al. Structure of human pro-matrix metalloproteinase-2: activation mechanism revealed. *Science* 1999; 284: 1667-1670.
34. Brew K, Dinakarpandian D, Nagase H. Tissue inhibitors of metalloproteinases: evolution, structure and function. *Biochim Biophys Acta* 2000; 1477: 267-283.
35. Butler GS, Will H, Atkinson SJ, Murphy G. Membrane-type-2 matrix metalloproteinase can initiate the processing of progelatinase A and is regulated by the tissue inhibitors of metalloproteinases. *Eur J Biochem* 1997; 244: 653-657.
36. Stetler-Stevenson WG, Kruttsch HC and Liotta LA. Tissue inhibitor of metalloproteinase (TIMP-2): A new member of the metalloproteinase inhibitor family. *J Biol Chem* 1989; 264: 17374-17378.
37. Strongin AY. Mechanism of cell surface activation of 72kDa type IV collagenase. Isolation of the activated form of the membrane metalloproteinase. *J Biol Chem* 1998; 273: 871-880.
38. Butler GS. The TIMP2 membrane type 1 metalloproteinase "receptor" regulates the concentration and efficient activation of progelatinase A. A kinetic study. *J Biol Chem* 1998; 273: 871-880.
39. Pilkington MF, Sims SM, Dixon SJ. Transforming growth factor-beta induces osteoclast ruffling and chemotaxis: potential role in osteoclast recruitment. *J Bone Miner Res* 2001; 7: 1237-1247.
40. Dallas SL, Rosser JL, Mundy GR, Bonewald LF. Proteolysis of latent transforming growth factor-beta (TGF-beta)-binding protein-1 by osteoclasts. A cellular mechanism for release of TGF-beta from bone matrix. *J Biol Chem* 2002; 277: 21352-21360.
41. Yu Q, Stamenkovic I. Cell surface-localized matrix metalloproteinase-9 activates TGF-beta and promotes tumor invasion and angiogenesis. *Genes Dev* 2000; 14: 163-176.
42. Holmbeck K, Bianco P, Caterina J, Yamada S, Kromer M, Kuznetsov SA, et al. MT1-MMP-deficient mice develop dwarfism, osteopenia, arthritis and connective tissue disease due to inadequate collagen turnover. *Cell* 1999; 99: 81-92.