

The immunohistochemical approach to determine the origin and possible function of the juxtaoral organ in dogs

Meltem Bahcelioglu, MD, Engin Calguner, PhD, Deniz Erdogan, PhD, Cigdem Elmas, PhD, Rabet Gozil, PhD, Semih Keskil, MD, PhD, Dural Kadioglu, PhD.

ABSTRACT

Objective: In this study, we applied immunohistochemical techniques on the functionally little known organ of Chievitz (juxtaoral organ [JOO]) in dogs to determine its origin and possible function.

Methods: The term abortive materials of 6 Doberman dogs were used for experimental procedures in July 2002 to June 2003 at Gazi University Faculty of Medicine, Ankara, Turkey, after routine light microscopic tissue preparation, the sections were stained with Masson's trichrome stain. In order to elucidate the function-related origin of the organ, we used epidermal growth factor (EGF-r), transforming growth factor (TGF-) and nerve growth factor (NGF-β) immunohistochemical stains.

Results: We observed a very strong and widespread immunoreactivity of EGF-r and TGF-a on simple

squamous capsular cells. We detected nerve growth factor-β positivity in granular form both in simple squamous capsular cells and in neighboring connective tissue. However, we did not detect EGF-r reactivity on parenchymal cells except a weak immunoreactivity on central ones. We noticed transforming growth factor- in most of the parenchymal cells while we observed NGF-β strongly in all the parenchymal cells.

Conclusion: These results may point out that the JOO may be of mesothelial or epithelial origin. Having NGF-positive granules and close relationship with blood vessels may imply a neurosecretory function. We believe that our study may add new perspectives to the function of the JOO.

Saudi Med J 2005; Vol. 26 (10): 1529-1534

The juxtaoral organ (JOO) (also known as the organ of Chievitz or buccotemporal organ) was first described in 1885 as a strand of epithelium located along the buccal sulcus of a human embryo.¹ The JOO is a normal structure of the cheek and found bilaterally, composed of both epithelial parenchyma and supporting mesenchyme. The JOO is not grossly apparent, but with a dissecting microscope, it can be visualized as a flat, white solid, strand of tissue resembling a nerve. As a small fusiform

structure; the JOO measures 0.7-1.7 cm in length and 0.1-0.2 cm in width, interposed between the buccotemporal fascia and pterygoid muscles, and innervated by 2-4 branches of the buccal nerve (**Figures 1a & 1b**).¹⁻⁵ According to Zenker,⁶ it first appears in embryos 0.75-1.2 cm in length, at a site of early oral cavity where, some authors claim, closely associated buccal nerve gives rise to it. Some suggested kinship to the parotid gland on the basis of genetic studies; however, no valid connec-

From the Department of Anatomy (Bahcelioglu, Calguner, Gozil, Kadioglu), Histology and Embryology (Erdogan, Elmas), School of Medicine, Gazi University, Ankara, and the Department of Neurosurgery (Keskil), School of Medicine, Kirikkale University, Kirikkale, Turkey.

Received 27th March 2005. Accepted for publication in final form 3rd July 2005.

Address correspondence and reprint request to: Dr. Meltem Bahcelioglu, Associate and Research Fellow, Department of Anatomy, Faculty of Medicine, Gazi University, Besevler 06500, Ankara, Turkey. Tel. +90 (312) 2024618. Fax. +90 (312) 2124647. E-mail: meltemb@gazi.edu.tr

tion was found either between JOO and the parotid and oral cavity epithelium.^{6,7} There were suggestions also that the parenchyma of JOO might rise from Schwann cells of squamous metaplasia.⁸ Microscopically, the JOO is composed of an epithelial parenchyma embedded in an organized connective tissue stroma rich in nerves.^{1,9} The parenchyma is encased by a connective tissue envelope of 3 layers. The thin inner connective tissue capsule (stratum fibrosum internum) is composed predominantly of dense collagen and a few elastic fibers and separated from the parenchyma by a basal membrane. The middle layer (stratum nervosum) is made up of loose connective tissue rich in myelinated and non-myelinated nerve fibers, as well as a variety of slow and fast adapting sensory receptors. A dense, outer collagen capsule (stratum fibrosum externum), envelops the entire organ, and is connected to the buccotemporal fascia. Within these connective tissue layers, there are variable numbers of mast cells, lymphocytes and cells containing melanin pigment. The parenchyma is represented by a long, continuous mass of epithelial cells, which appear as multilobulated, circumscribed nests of cells in histologic sections. Epithelial cells may resemble non-keratinizing squamous epithelium or columnar glandular-like cells with clear cytoplasm.^{1,5,9-17} Also, Hultenschmidt et al¹⁷ demonstrated in JOO the marked innervation and vascular supply of the direct surroundings. There have been several reports with various human and animal materials on the origin and functional/clinical significance of this unique organ.^{1-4,9,12,18,19} However, the functional significance of the JOO remains controversial. Some authors considered it to be a rudimentary structure that remained after embryologic development without any function. Some suggested that the JOO had potential to become differentiated during development and might have functions such as, secretory activity, neuroreceptor or sensory functions. There were reports also on its possible neuroepithelial or meningoepithelial origin.^{3,4,12,14,16,19} Immunohistochemically, some authors investigated the JOO with light-chain cytokeratin (KL-1), cytokeratin 19, desmin, S-100 protein, vimentin, epithelial membrane antigen (EMA), glial fibrillary acidic protein (GFAP) and neuroendocrine markers (chromogranin, synaptophysin and neuron-specific enolase).^{1,5,10,18} We preferred to investigate the organ with epidermal growth factor receptor (EGF-r), transforming growth factor alpha (TGF- α) and nerve growth factor beta (NGF- β). Epidermal growth factor is a 53 amino acid polypeptide of 6 kDa molecular weight and has a mitogenic effect on epithelial and mesothelial cells. Transforming growth factor alpha is a 50 amino acid mitogenic polypeptide of 5.5 kDa that is structurally and biologically homologous to EGF and competes for binding to same receptor. Transforming growth factor alpha expression has

been identified in many different tissues such as human keratinocytes and human and rodent mammary epithelial cells.²⁰ Nerve growth factor is a good neural biomarker, which has been found to stain also angiofibromas of the head and neck region.²¹ This biomarker is a neurotropic factor that promotes differentiation and growth of peripheral and central nerve cells, and is essential for the maintenance of nerve cell function and activity. It is a protein of 140kDa composed of 3 subunits: α , β and γ -NGF. Nerve growth factor activity is mediated by high affinity and low affinity cell surface glycoprotein receptors.²⁰ The aim of this study was to elucidate the question of JOO's origin and function by using immunohistochemical techniques using the biomarkers such as EGF-r, TGF- α and NGF- β .

Methods. The term abortive materials of 6 Doberman dogs were obtained from the Faculty of Veterinary Sciences, Ankara University, Ankara, Turkey. The experimental protocol was approved by the Local Ethical Committee for animal studies and conducted at the Faculty of Medicine, Gazi University in July 2002 to June 2003.

Light microscopy. Immediately after surgical removal, juxtaoral organs were fixed in 10% neutral formalin for approximately 72 hours. They were dehydrated in an increasing serial dilutions of ethanol, and embedded in paraffin for conventional histological diagnosis. Cross sections (3-4 μ) were mounted on polylysine-coated slides, deparaffinize with xylene and rehydrated. Sections were stained with Masson's trichrome stain and immunohistochemically with EGF-r, TGF- α and NGF- β (Leica Jung SM 2000 microtome, Olympus BH-2 light microscope with Olympus C-35AD-4 camera).

Immunohistochemical staining. Endogenous peroxidase activity was blocked in 0.1% hydrogen peroxide (Fisher Scientific, Melrose Park, IL) for 10 minutes and sections were incubated with saponin to assist binding of primary antibody to epitopes. Epitopes were stabilized by application of serum blocking solution (Goat serum, Part#JA 1296-EA, Oncogene Science, Manhasset, New York, USA) for 20 minutes. Sections were incubated with antibody overnight at +4°C. Epidermal growth factor receptor rabbit polyclonal antibody Ab-4 (100 μ g/ml) (Lot#DO8571-1, Cat# PC19-100UG, Oncogene Science, Manhasset, New York, USA), TGF- α mouse monoclonal antibody Ab-2 (Cat # GF 10-100 μ g/ml, Lot # 409401-5, Oncogene Science, Manhasset, New York, USA) and human NGF- β (Product # N-1408, Sigma, USA) were used. They were diluted 1:20 in phosphate buffered saline (PBS) (for EGF-r and NGF- β) or in tris buffered saline (TBS) (for TGF- α). The secondary antibody, a 1% diluted biotin labeled anti rabbit total Ig

(Biotinylated antibody, Part# JA 1090-EA, Oncogene Science, Manhasset, New York, USA) was applied for 30 minutes at room temperature. A negative control was run by using normal rabbit IgG, (Lot# DO2131-4, Cat# NI01-100UG, Oncogene Science, Manhasset, New York, USA), instead of primary antibody. After washing with PBS or TBS, avidin-biotin-complex-peroxidase (ABC, Part #JA 1235-EA, Oncogene Science, Manhasset, New York USA) was applied to slides. 3-amino-9-ethylcarbazole (AEC) kit (Neomarker, Labvision, USA) was used as the chromogen. Afterwards, the slides were counterstained with hematoxylin for 1 minute, dehydrated in graded ethanols and mounted in a conventional medium (Mikroskopie Entellan #740212765, Merck, Germany). The intensity of the immunoperoxidase reaction was classified as follows: negative (-), when the cells were devoid of any detectable expression; slightly positive (+); moderately positive (++) and strongly positive (+++).

Results. Light microscopic examination of dog JOO revealed a collagen-fiber rich connective tissue capsule, stained blue with Masson's trichrome stain, enveloping the organ (**Figures 2 & 3**). Parenchyma was represented by continuous mass of epithelial cells (**Figure 2**). Epithelial cells may resemble nonkeratinizing squamous epithelium or round glandular-like cells with clear cytoplasm (**Figure 3**). Some of centrally located cells with pale cytoplasm formed so-called light centers whereas others exhibited a dark appearance (**Figure 3**). In some areas, epithelial sprouts formed "ductlike structures" containing empty lumen. The parenchyma was surrounded with an organized connective tissue envelope which included collagen fibers and simple squamous capsular cells. Moreover, very clear space between the connective tissue capsule and cluster of parenchymal cells were obvious. Further, fine fibers of connective tissue with rich capillaries and connective tissue cells were seen surrounding the structures (JOO) (**Figure 3**). In sections stained immunohistochemically with EGF-r; simple squamous capsular cells seemed to have reacted strongly with EGF-r though a slightly positive immunoreactivity was shown by parenchymal cells (especially the central ones) of the JOO (**Figure 4**). In TGF- stained sections; the parenchymal cells and surrounding layers of capsule cells were clearly observed. The TGF- reaction was noticed more strongly in peripheral parenchymal cells and slightly in central ones. Reaction was seemed to be cytoplasmic in the central parenchymal cells, whereas it was both cytoplasmic and membranous in the peripheral ones. A widespread cytoplasmic membrane expression was seen in the simple squamous

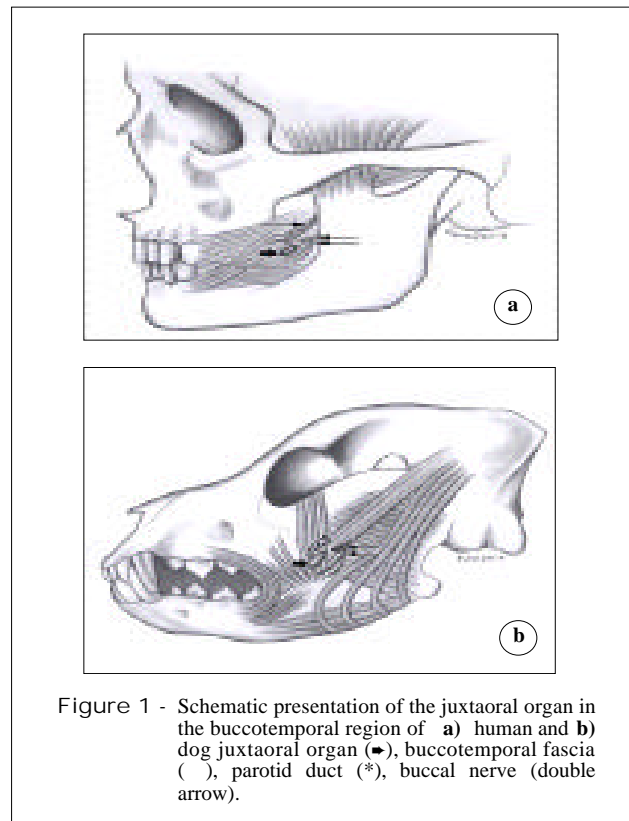


Figure 1 - Schematic presentation of the juxtaoral organ in the buccotemporal region of a) human and b) dog juxtaoral organ (●), buccotemporal fascia (), parotid duct (*), buccal nerve (double arrow).

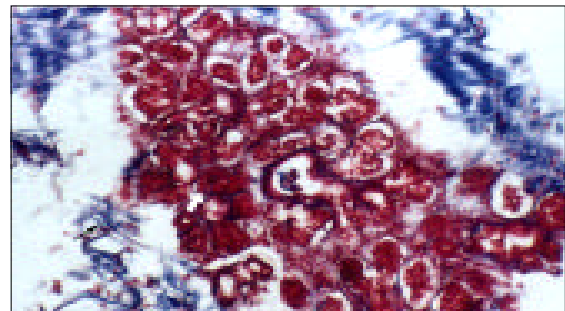


Figure 2 - Juxtaoral organ with Masson's trichrome stain. Parenchyma (white arrow) and stroma (black arrow) are seen. Original magnification x 200.

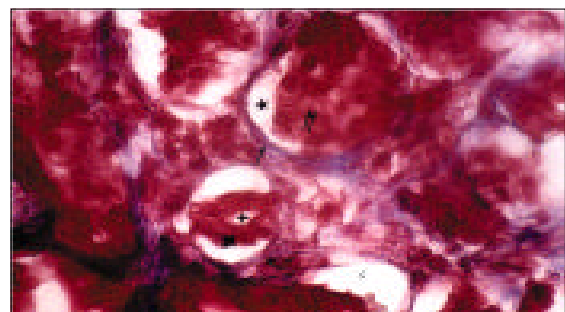


Figure 3 - Juxtaoral organ with Masson's trichrome stain. Parenchymal cells (●), capsule (), a space (*) between the capsule and parenchymal cells, parenchymal cells with round nuclei (●), central less dense cells (double arrow), lumen (+), capillary (c). Original magnification x 400.

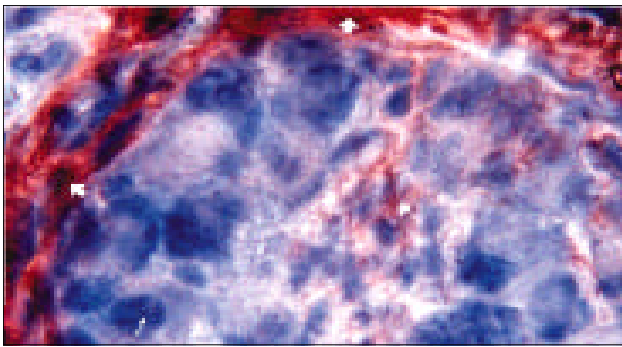


Figure 4 - Epidermal growth factor receptor immunostaining (counterstain with hematoxylin and eosin): Parenchymal cells (white thin arrow), capsular cells (white big arrow), a widespread cytoplasmic expression (white big arrow), weak expression on some parenchymal cells (*). Original magnification x 1000.

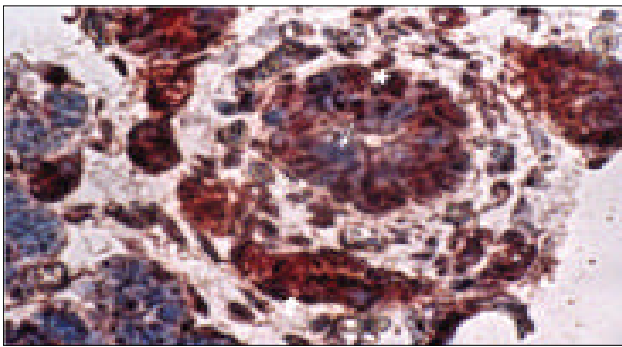


Figure 5 - Transforming growth factor alpha immunostaining (counterstain with hematoxylin and eosin); the parenchymal cells and the layers of sheath surrounding the parenchymal cells (→), peripheral cells of the parenchyma (*), weak transforming growth factor alpha expression of parenchymal cells (white thin arrow), the widespread membrane expression in the simple squamous capsular cells (double arrow). Original magnification x 400.

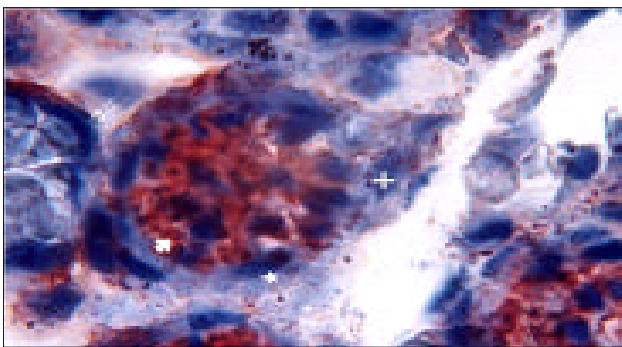


Figure 6 - Nerve growth factor beta immunostaining (counterstain with hematoxylin and eosin); widespread cytoplasmic expressions of parenchymal cells (white big arrow) but no expression is seen in the capsular cells (*), close relation of the capsular cells with blood vessels (double arrow). Occasional granular nerve growth factor beta expression is observed in the neighbor connective tissue (+). Original magnification x 1000.

Table 1 - Distribution of immunoreactivity pattern in different cells of juxtaoral organ (JOO).

Cells in JOO	Intensity of antibodies pattern		
	EGF-r	TGF-α	NGF-β
Parenchymal cells	-/+	++	+++
Squamous capsular cells	+++	+++	++

- = when the cells were devoid of any detectable expression;
 + = slightly positive, ++ = moderately positive,
 +++ = strongly positive

cells of connective tissue capsule (**Figure 5**). In NGF-β immunostaining applied group, cytoplasmic and granular appearance of expression was shown by the capsular cells, though widespread cytoplasmic expression was observed in all cells of JOO's parenchymal cells. Nerve growth factor beta positive small granules were detectable also in neighboring connective tissue and these granules had very close relationship with blood vessels (**Figure 6**). Our intensity inventions of immunoreactivity are summarized in **Table 1**.

Discussion. Several investigators claimed that the JOO was neuroepithelial in structure and may well be misdiagnosed for neoplastic tissue of the retromolar trigone soft tissue in oral cancer surgery.^{14,22-26} Some authors speculated that the parenchyma might arise from Schwann cells that had undergone squamous metaplasia.¹ According to others, the arachnoid cell nests in cranial nerve sheaths are the source of the organ of Chievitz and are meningoepithelial rather than neuroepithelial.^{19,27} Zenker,⁶ on the other hand suggested that the JOO represents an anlage of the parotid gland. This was supported by genetic studies showing the development of both the JOO and parotid were affected by the same mutations.²⁸ However, it was shown that the JOO had no true connection with the parotid duct or with the epithelium of the oral cavity.⁹ Mandl et al,¹⁰ in an immunohistochemical and EM study, examined light-chain cytokeratin (KL-1), cytokeratin 19, desmin, chromogranin, neuron-specific enolase and S-100 protein in JOO. He showed that with the application of cytokeratin (polykeratin) 19, epithelial cells were lightly stained whereas neuroepithelial and connective tissue cells were not, and accordingly claimed, like some other authors, that the organ may have mechanoreceptor function.^{10,29} Other authors have shown that JOO cell nests had also become positive with vimentin,

weakly reactive with epithelial membrane antigen (EMA) and negative with S-100 protein, glial fibrillary acidic protein (GFAP) and neuroendocrine markers (chromogranin, synaptophysin and neuron-specific enolase).^{1,5,18}

We observed a slightly positive immunoreactivity with EGF-r in parenchymal cells especially the central ones, though the capsular cells showed very strong reaction. The parenchymal cells and simple squamous capsular cells were clearly stained with TGF- β , and all parenchymal and capsular cells of JOO with NGF- β . The parenchymal cells showed strong immunoreactivity with NGF- β , whereas immunoreactive positive granules were detected on the cytoplasm of capsular cells and on the neighboring connective tissue. Lischka,³⁰ observed that the denervation of the buccal nerve results in a loss of nervous structures and parenchymal atrophy, with accompanying hypertrophy of the contralateral non-denervated JOO which in turn may well imply that, the buccal nerve provides some trophic function for the organ parenchyma. Besides, hypophysectomy in rats also results in a parenchymal loss (up to 11-26%), leading to the conjecture that the pituitary gland also has some influence over this organ.¹³ Zenker et al,³¹ suggested that the high enzymatic activity in the parenchymal cells of JOO might point out high metabolic activity in these cells. Meanwhile, the intimate relationship between parenchyma and nonmyelinated nerves, as well as the presence of neurosecretory-like granules within cells, suggests a possible neurosecretory function of the JOO.¹ The NGF- β immunoreactive positive granules, which we observed, would be interpreted as in accordance with these findings.

On the other hand, some authors believed that the JOO represents a mechanosensory with different qualities of perception, somewhat analogous to a Pacinian corpuscle and takes part in various activities of the lateral wall of the oral cavity such as deglutition, sucking, mastication, speech, protecting reflexes and wall tonus.^{1,29} Although the function(s) of JOO is (are) not much understood, our results at least suggest that, the JOO may be of the epithelial origin because, most of its cells were stained by EGF-r and TGF- β , or it may be the neural origin since the NGF- β positivity of the parenchymal cells and the presence of NGF- β positive granules on squamous cells of the capsule. This neurosecretory-like granule strongly suggests a possible neurosecretory function of the JOO because of their very close relationship with blood vessels.

We hope all these possibilities mentioned above may add new perspectives to better understand the origin and function of the juxtaoral organ.

Acknowledgment. This work was supported by a grant from Research Foundation (Project code no. 01/ 2002 -60), Gazi University, Turkey. The authors express their profound gratitude to their medical illustrator, Tuna Ferit Hidayetoglu, for his original artwork.

References

- Pantanowitz L, Balogh K. Significance of the juxtaoral organ (of Chievitz). *Head & Neck* 2003; 25: 400-405.
- Kaspar E, Leibl W. Zur Makroskopischen Anatomie des juxtaoralen organs. (On the gross anatomy of the juxtaoral organ). *Anat Anz Bd* 1965; 116: 340-344.
- Benninghoff. Anatomie Band 1. Baltimore: Urban & Schwarzenberg; 1994. p. 789.
- Sternberg SS. Histology for Pathologists. 2nd ed. New York: Lippincott-Raven Publishers; 1997. p. 376-377.
- Pantanowitz L. Immunophenotype of the juxtaoral organ. *Int J Oral Maxillofac Surg* 2004; 33:113.
- Zenker W. Juxtaoral organ (Chievitz's organ). Morphology and clinical aspects. Baltimore: Urban & Schwarzenberg; 1982.
- Ramsay AJ. Persistence of the organ of Chievitz in the human. *Anat Rec* 1935; 63: 281-293.
- Lutman GB. Epithelial nests in intraoral sensory nerve endings simulating perineural invasion in patients with oral carcinoma. *Am J Clin Pathol* 1974; 61: 275-284.
- Pantanowitz L, Tschen JA. Organ of Chievitz. *Ear Nose Throat* 2004; 83: 230.
- Mandl L, Nerlich A, Pankratz H, Hübner G. Das juxtaorale (Chievitz-Organ)-ein sensibles organ in der buccotemporalregion? *Pathologe* 1993; 14: 205-209.
- Salzer GM, Stockinger L, Zenker W. Das juxtaorale organ. *Verh Anat Ges* 1965; 115: 479.
- Mayr R, Salzer GM. Elektronenmikroskopische Untersuchungen am Juxtaoralen organ des Menschen. *Z Zellforsch Mikrosk Anat* 1967; 81: 135-154.
- Salzer GM, Zenker W. Veränderungen am juxtaoralen Organ der Ratte nach Hypophysectomie. *Z Zellforsch Mikrosk Anat* 1968; 84: 72-86.
- Krammer EB, Lischka MF. Über die bedeutung der Kenntnis des Juxtaoralen Organs in der Mundhöhlenpathologie und -chirurgie. *Wiener Klinische Wochenschrift* 1974; 86: 639-643.
- Geist ET, Adams TO, Carr RF. The organ of Chievitz: its importance in the microscopic diagnosis of oral carcinoma. *J Oral Med* 1984; 39: 177-179.
- Kleiss C, Kleiss E. Morphogenetic aspects of the juxtaoral organ (Chievitz'organ) in the human. *Z. Mikrosk Anat Forsch* 1985; 99: 59-74.
- Hultenschmidt D, Vogel J, Stoll P. Das Chievitz'sche organ (juxtaorales organ): Morphologische und immunhistochemische Untersuchungen. *Dtsch Zahn Mund Kieferheilkd Zentralbl* 1991; 79: 565-570.
- Bénateau H, Rigau V, Comoz F, Benchemam Y, Galateau F, Compère JF. Tumour of the juxtaoral organ. *Int J Oral Maxillofac Surg* 2003; 32: 101-103.
- Vadmal MS, Rossi MB, Teichberg S, Hajdu SI. Intraoral tumor of Chievitz in a child. *Pedia Dev Path* 1998; 1: 230-233.
- Elmas C, Erdogan D, Ozogul C. Expression of growth factors in fetal human olfactory mucosa during development. *Growth Dev Aging* 2003; 67: 11-25.
- Zhang PJ, Weber R, Liang HH, Pasha TL, LiVolsi VA. Growth factors and receptors in juvenile nasopharyngeal angiofibroma and nasal polyps. An immunohistochemical study. *Arch Pathol Lab Med* 2003; 127: 1480-1484.

22. Leibl W, Pflüger H, Kerjaschki D. A case of nodular hyperplasia of the juxtaoral organ in man. *Virchows Arch A Path Anat Histol* 1976; 371: 389-391.
23. Tschén JA, Fechner RE. The juxtaoral organ of Chievitz. *Am J Surg Pathol* 1979; 3: 147-150.
24. Kristensen S, Tveteras K, Friedmann I, Thomsen P. Nasopharyngeal Warthin's tumour: A metaplastic lesion. *J Laryngol Otol* 1989; 103: 616-619.
25. Soucy P, Cimone G, Carpenter B. An unusual intraoral mass in a child: The organ of Chievitz. *J Pediatr Surg* 1990; 25: 1200.
26. Oxford GE, Jonsson R, Olofsson J, Zelles T, Humphreys-Beher MG. Elevated levels of human salivary epidermal growth factor after oral and juxtaoral surgery. *J Oral Maxillofac Surg* 1999; 57: 154-158.
27. Kershisnik M, Callender DL, Batsakis JG. Extracranial, extraspinal meningiomas of the head and neck. *Ann Otol Rhinol Laryngol* 1993; 102: 967-970.
28. Gruneberg H. Exocrine glands and the Chievitz organ of some mouse mutants. *J Embryol Exp Morphol* 1971; 25: 247-261.
29. D'Andrea V, Malinovsky L, Biancari F, Spyrou M, Dibra A, Malinowska V, et al. The Chievitz juxtaaprotid organ. *G Chir* 1999; 20: 213-217.
30. Lischka M. Das juxtaorale organ der ratte nach denervierung. *Z Anat Entwickl Gesch* 1969; 129: 268-273.
31. Zenker W, Mayr R, Widhalm S, Salzer GM. Einige Histochemische Untersuchungen am Chievitzschen Organ. *Acta Anat* 1961; 45: 164-176.