

# Acute small bowel obstruction due to bilharziasis

*Rahman Gul, MBBS, FRCSEd, Kamran Khalid, FRCSI, FRCSEd,  
Mohammad F. Al-Rajhi, MBBS, Hayan A. Bismar, MBBS, CABS.*

---

### ABSTRACT

Schistosomiasis remains a major world health problem. The disease presents with protean manifestations in the endemic areas. Small bowel schistosomiasis leading to acute intestinal obstruction is an extremely rare clinical presentation. The disease may mimic peritoneal tuberculosis or carcinomatosis intra-operatively. Small bowel bilharziasis leading to obstruction has not been reported in the recent indexed English literature. This report describes a 50-year-old Yemeni male presenting with acute small bowel obstruction due to schistosomiasis. We review the pathological changes in the intestine following schistosomal infection and discuss diagnosis and treatment. We emphasize the importance of histopathology on all surgical specimens.

Saudi Med J 2005; Vol. 26 (10): 1624-1626

---

Schistosomiasis (bilharziasis) is a major world health problem with significant economic and public health consequences. The disease is endemic in 74 countries and approximately 200 million people are infected worldwide, of whom 120 million are symptomatic and 20 millions have severe disease. China is reported as the most affected country in Asia with an estimated 900,000 infected people and in the Middle East, Yemen has the highest number of involved population.<sup>1</sup> All 3 *Schistosoma* species are known to affect the bowel. *Schistosoma mansoni* (*S. mansoni*) and *Schistosoma japonicum* (*S. japonicum*) eggs affect the whole alimentary tract from duodenum to rectum.<sup>2</sup> In endemic areas, all age groups are affected and present with varied clinical manifestations. Small bowel obstruction due to intestinal schistosomiasis is an extremely rare clinical condition. Extensive Medline search revealed only one case in a 10-year-old girl in the English literature.<sup>3</sup> This report describes a Yemeni male presenting with acute

small bowel obstruction due to schistosomiasis. We review the pathological changes in the intestines following schistosomal infection and discuss the treatment modalities.

**Case Report.** A 50-year-old Yemeni male was admitted through the Accident and Emergency Department at Riyadh Medical Complex with generalized abdominal pain, occasional vomiting, abdominal distention, and constipation of one day duration. He had been having similar attacks of pain, on and off, for the last 2 years, relieved by various medications. There was no history of fever, diarrhea, melena or loss of weight. He underwent a laparotomy 4 years earlier for a fire arm injury. Another laparotomy, with small bowel resection, was performed for intestinal obstruction 2 years prior to the index admission. Both surgeries were performed at another hospital and no detailed operation notes or histopathology reports were

---

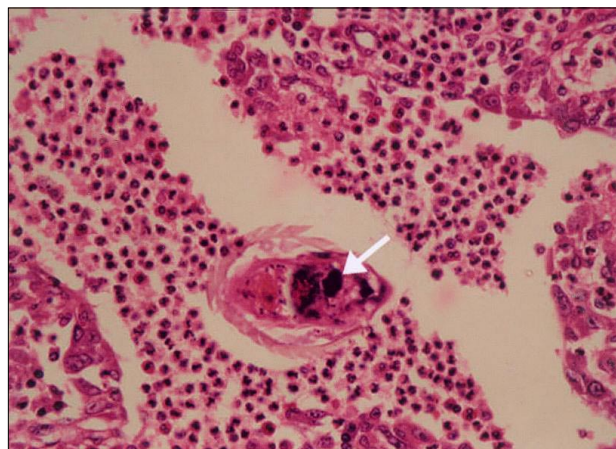
From the Department of General Surgery, College of Medicine, King Saud University Unit, Riyadh Medical Complex, Riyadh, Kingdom of Saudi Arabia.

Received 12th April 2005. Accepted for publication in final form 18th June 2005.

Address correspondence and reprint request to: Dr. Kamran Khalid, Honorary Clinical Tutor and Senior Registrar, King Saud University Unit, Riyadh Medical Complex, PO Box 331267, Riyadh 11373, Kingdom of Saudi Arabia. E-mail: kkkhawaja@hotmail.com

available. Physical examination revealed normal vital signs. Abdominal examination showed a midline scar with a reducible incisional hernia through the lower part. The abdomen was slightly distended with minimal tenderness in the periumbilical region. There was no guarding or rigidity. Bowel sounds were exaggerated and rectal examination was unremarkable. Laboratory investigations revealed hemoglobin, 13 gm% and white cell count of  $10 \times 10^3/L$ , slight eosinophilia and normal biochemistry. Abdominal x-ray showed scattered gas-fluid levels and mildly distended loops of small bowel. Initial management was conservative on the lines of sub-acute adhesive small bowel obstruction. After 48 hours, he became more tachycardic with increasing abdominal distension. Exploratory laparotomy disclosed distended loops of small bowel with multiple pale nodules on serosal surface, omentum and peritoneal surfaces. One loop of distal ileum was stuck to the pelvic floor with dense adhesions. Gentle releasing of the loop revealed a tight stricture along with serosal nodules and thickened adjacent mesentery. The findings were grossly consistent with abdominal tuberculosis. Segmental resection and anastomosis was performed and biopsy from omentum was obtained. Postoperative course was complicated by wound infection necessitating open drainage. Histopathology of the resected specimen and omentum showed *S. mansoni* eggs in muscularis propria with inflammatory cells and fibrosis in the wall of ileum along with transmural inflammation, consistent with small bowel bilharziasis (Figure 1). Extensive work up for the disease revealed indirect hemagglutination (IHA) test for bilharzia as positive with 1/1406 dilution. No ova could be detected in repeated urine and stool specimens. Abdominal ultrasonography showed normal hepato-biliary and urinary systems. He was subsequently treated with a single course therapy of praziquantel 40 mg/kg. He was discharged in good condition. Over a 6 month follow up, he is doing well with no recurrent symptoms.

**Discussion.** Bilharziasis remains one of the most prevalent parasitic infections with an estimated 652 million of the world population at risk of infection.<sup>4</sup> Intestinal schistosomiasis (*S. mansoni*) is endemic in 54 countries, including the Arabian Peninsula, Egypt, Libya, Sudan, sub-Saharan Africa, Brazil, some Caribbean islands, Suriname, and Venezuela.<sup>5</sup> *Schistosoma japonicum* is mostly found in China, Indonesia, Philippines, and Thailand, whereas *Schistosoma haematobium* (*S. haematobium*) is more prevalent in the Middle East and most of the African countries.<sup>1,2</sup> Many of the control programs or interventions undertaken over the last 20 years have been with bilateral donor



**Figure 1** - Microscopic appearance of the small bowel showing bilharzial egg (white arrow) with surrounding mononuclear inflammatory cells and fibrous tissue (Bilharzioma) (x200).

funding, the major source being the World Bank providing health sector credits to many countries. Saudi Arabia, along with Iran, Iraq, Morocco, Puerto Rico, and Venezuela, is an exception where local resources were utilized for the control of the disease.<sup>1</sup> The disease usually affects children and young adults, though no age is immune.<sup>6</sup> Both *S. mansoni* and *S. japonicum* are known to produce granulomatous inflammatory lesions (bilharzioma) in the colon along with pericolic infiltration, leading to stenosis of the affected bowel. These "bilharziomas" may sometimes mimic abdominal tuberculosis (tuberculomas) or carcinomatosis peritonei.<sup>7</sup> Bilharzioma refers to a localized pseudo-tumor of *Schistosoma* ova or egg shells surrounded by inflammatory cells and extensive fibrosis. Such granulomas predominantly occur in omentum, peritoneal surfaces, and mesenteric lymph nodes, and infrequently the bowel wall.<sup>3</sup> Deposition of ova in gut wall incites inflammation leading to diarrhea and bleeding from ulceration. Grossly, these appear as elevated granules with overlying petechial hemorrhages. The distal colon is affected more than the proximal colon. Large ovum load in the submucosa associated with hyperplasia leads to polyp formation in the large bowel. These inflammatory polyps are usually directly related to intensity of infection and the concentration of eggs are highest in polyps then elsewhere.<sup>3</sup> Cheever and Andrade<sup>8</sup> reported such polyps in 9.1% of autopsies on asymptomatic infected children. Ulceration of mucosa overlying the polyps results in diarrhea and bleeding leading to fluid and protein deficiency.<sup>9</sup> Polyps may become the leading point for intussusception.<sup>3</sup> When the ovum load is even greater, these become deposited in all layers of the bowel wall with eventual thick

fibrosis, specially involving the subserosal tissues, leading to luminal narrowing and strictures of bowel. Thick fibrotic and granulomatous reaction resulting in mucosal destruction and marked thickening of the bowel wall strongly mimics carcinoma, regional ileitis or other granulomatous enteritis.<sup>3,6,10</sup> The small bowel, when involved, is not as severely affected as the large bowel.<sup>3</sup> In the early stages, specific therapy with praziquantel may resolve some granulomas, but others may progress to cause extensive fibrosis and strictures leading to various bowel complications. Such late complications are less responsive to specific treatment.<sup>3,10</sup> Early diagnosis and treatment in the asymptomatic stage is important. In endemic areas, praziquantel is highly effective against all the 3 species. When given as a single dose to stool positive people, 85% achieve complete cure.<sup>3</sup> Patients should be followed up with stool and urine analysis for ova and serum IHA titers.

This report describes bilharzial obstruction of small bowel closely resembling abdominal tuberculosis in an adult male. Schistosomiasis must be considered in the differential diagnosis as a rare cause of small bowel obstruction in endemic regions.

**Acknowledgment.** The authors would like to express sincere thanks to Dr. Wafaa Al-Halabi Al-Shakweer, Consultant Histopathologist, for providing the photo micrograph of the case.

## References

1. Chitsulo L, Engels D, Montresor A, Savioli L. The global status of Schistosomiasis and its control. *Acta Trop* 2000; 77: 41-51.
2. Cotron RS, Kumar V, Robbins SL, editors. Pathologic Basis of the Diseases. 5th ed. Philadelphia: WB Saunders Company; 1994. p. 371-372.
3. Ali AE, Ismail BM, Khogali FR. Small intestinal obstruction due to Bilharzioma. *East Afr Med J* 2003; 80: 603-605.
4. Utroska JA, Chen MG, Dixon H, Yoon S, Helling-Borda M, Hogerzeil HV, et al. An estimate of global needs for praziquantel within schistosomiasis control programmes. Geneva: WHO; 1989. p. 102.
5. Urbani C, Toure A, Hamed AO, Albanico M, Kane I, Cheikna D, et al. Parasitoses intestinales et schistosomiasis dans la vallee du fleuve Senegal en Republic. *Med Trop* 1997; 57: 157-160.
6. Farhan NE, Raheem M, Badawy A, Zuberi SR, Matbouli SA. Recto sigmoid Bilharzioma causing intestinal obstruction. *J Pediatr Surg* 1997; 32: 631-633.
7. El-Afifi S. Intestinal bilharziasis. *Dis Colon Rectum* 1964; 7: 1-13.
8. Cheever AW, Andrade ZA. Pathological lesions associated with *Schistosoma mansoni* infection in man. *Trans R Soc Trop Med Hyg* 1967; 61: 626-639.
9. Lehman JS, Farid Z, Bassily S. Intestinal protein loss in schistosomal polyposis of colon. *Gastroenterology* 1970; 59: 433-436.
10. Lyer HV, Abaci IF, Rehnke EC, Enquist IF. Intestinal obstruction due to schistosomiasis. *Am J Surg* 1985; 149: 409-411.