

Reconstruction techniques in renal injury

Ali F. Akay, MD, Hayrettin Sahin, MD, Yusuf Nergiz, MD, Ugur Aflay, MD, Mehmet K. Bircan, MD.

ABSTRACT

Objective: Kidney repair reconstruction techniques are controversial. The conventional technique is suturing, but this is usually with further loss of viable tissue as it promotes scarring. In this animal model, we investigated the parenchymal effect of different sutures and methods.

Methods: We carried out this study in the year 2000 in the Animal Laboratory of Dicle University, Diyarbakir, Turkey. We used 40 New Zealand white rabbits in this study, randomized into 5 groups. We separated the left kidney from Gerota's fascia, and performed standard lacerations with incisions 5 mm deep and 10 mm in length. We performed no reconstruction procedure in group 1, and used homeostatic collagen powder in group 2. We primarily sutured the lacerations with chromic gut (4/0) in group 3, and sutured the kidney in group 4 with polyglactin (4/0). We wrapped the kidney with a

polyglactin mesh in group 5. We sacrificed 2 rabbits in each group postoperatively on day 2, 15, 45 and 90, and performed left nephrectomy for histological investigation, and assessed interstitial inflammation.

Results: While group 5 established the best results, the other 4 groups had similar intermediate results. The pseudocapsule was visible macroscopically in the polyglactin mesh group. We could see mononuclear cell infiltration, dilatation of tubules, atrophy of tubules, and interstitial fibrosis in all groups except group 5.

Conclusion: In this animal model, we found that the most appropriate repair material for kidney surgery was polyglactin mesh.

Saudi Med J 2005; Vol. 26 (11): 1750-1754

Renal laceration occurs either by various traumas, or iatrogenically during kidney surgery. Where necessary, there is reconstruction of the lacerations with different methods, sutures, or both. The goal of this reconstruction is to salvage the kidney with preservation of viable parenchyma and to control bleeding. The kidney is a fragile organ, which bleeds easily. The 2 most significant challenges facing the urological surgeon during kidney surgery include bleeding control, and collecting system repair.¹ Reconstruction after trauma or during kidney surgery is complex and requires sophisticated surgical skills. This is not always possible, especially during emergency cases. So, this condition forces the technology to develop an alternative method for reconstruction, which is safe, quick, and easy to apply. Recently, several

publications described the use of surgical devices that help to achieve hemostasis during kidney surgery, including argon beam coagulator, ultrasonic, microwave tissue coagulator, radio frequency tissue ablation, laser, and fibrin glues.² However, there is no accepted ideal method of suture and reconstruction, so in this study we aimed to research the efficacy and effects of different sutures and methods upon renal parenchyma.

Methods. This study was carried out in the year 2000 at the Animal Laboratory of Dicle University, Diyarbakir, Turkey. Veterinarians and trained personnel provided comprehensive care for the animals throughout the study period. Forty New Zealand white-rabbits, each weighing 2-4 kg was

From the Department of Urology (Akay, Sahin, Aflay, Bircan) and the Department of Histology (Nergiz), Dicle University School of Medicine 21280 Diyarbakir, Turkey.

Received 16th February 2005. Accepted for publication in final form 22nd August 2005.

Address correspondence and reprint request to: Dr. Ali F. Akay, Dicle Universitesi Tıp Fakultesi, Uroloji Anabilim Dalı, 21280-Diyarbakir, Turkey. Tel. +90 (412) 2488219. Fax. +90 (412) 2488440. E-mail: aliak@dicle.edu.tr

used and divided into 5 groups. All interventions were completed under general anesthesia following intramuscular application of 45 mg/kg ketamine HCl plus 5 mg/kg diazepam. All rabbits received a preoperative antibiotic (cefazolin) intramuscularly of one dose. We applied the middle pole of the kidney as graded IV penetrating injury. The left kidneys of the rabbits were completely mobilized and lacerated 10 mm in length and 5 mm in depth by number 11 scalpel in the middle lobe. The mobilize kidney of 8 rabbits were not injured and observed as a control group. The remaining 32 kidneys were reconstructed with various methods. group 1: control group (no reconstruction), group 2: collagen powder was applied to lacerations, group 3: lacerations were repaired with interrupted suture by 4/0 chromic gut suture, group 4: lacerations were repaired with interrupted suture by 4/0 polyglactin suture, group 5: kidney wrapped with a polyglactin mesh (PM). An elliptical shaped PM (vicryl mesh, Ethicon®) with an elliptical hole in the center with pursestring 3/0 polyglycolic acid sutures placed at both outer and inner edges of the graft were prepared. The inner hole of the PM was placed around the hilus, and both pursestring sutures were tied simultaneously until the graft firmly surrounded the kidney in the presence of active bleeding. The hilus was not compressed. Hematocrit values were checked in all animals on the first hour and first day postoperatively. Two animals of each group were sacrificed at 48 hours, and the 15th day, 45th day

and 90th days. After sacrifice, the left kidneys were removed for macroscopic and histopathological evaluation with light microscope. Those kidneys were fixed by application of a 10% formalin and paraffin inclusion method. During pathological examination, sections from what appeared to be lacerations were also carefully obtained. Five micrometers thick paraffin block sections were dyed by hematoxylin and eosin and tubulointerstitial morphology was scored as described by Modi et al.³

Results. None of the rabbits were lost postoperatively. **Table 1** summarizes the hematocrit values of all groups. Macroscopic evaluation at the 48th postoperative hour in the control and collagen powder group showed perirenal hematoma. In the other groups, only the sutures were observed without any pathological condition. On the 15th postoperative day, hematoma was organized in the control group. Fibrosis was seen in the collagen powder group. Granulation occurred in the chromic gut and polyglactin group. The kidney was wrapped by a pseudocapsule in the PM group. On the 45th postoperative day, organized hematoma was still seen in the control group. No material or pathology was seen in the chromic gut and collagen powder group. The pseudocapsule was visible in the PM group. The kidney was fixed to surrounding tissues in all groups but mostly in PM group. On the 90th postoperative day, macroscopically everything in the chromic gut, a collagen powder and control group was normal, other than fixation of the kidney to perirenal tissues. The pseudocapsule surrounding the kidney was significantly more visible than before in the PM group. The polyglactin sutures were totally absorbed. Microscopic examination on the 90th postoperative day showed thickening of the renal capsule and interstitial fibrosis in the control group (**Figure 1**). No absorbed collagen powder material was seen with diffuse fibrosis observed in the collagen powder group (**Figure 2**). Granulation of tissue around the sutures, and diffuse necrosis

Table 1 - Hematocrit values.

Groups	Preoperative values (%)	Postoperative values (%)	
		1st hour	1st day
Group 1	44	40	38
Group 2	42	40	40
Group 3	46	44	44
Group 4	42	42	44
Group 5	48	48	46

Table 2 - Tubule interstitial morphology results of groups at the postoperative 90th day.

Groups	Intertubular edema	Vacuolization of tubules	Mononuclear Cells infiltration	Dilatation of tubules	Atrophy of tubules	Interstitial fibrosis	Necrosis
Control group	+++	+++	++	+++	+++	+++	+++
Collagen powder group	++	+++	+++	++	++	+++	-
Chromic gut group	++	++	+	++	+	+	+++
Polyglactin group	++++	++	++	+++	+	+++	-
Polyglactin mesh group	+	+	-	-	-	-	-

Tubule interstitial morphology as described by Modi et al.³
 (-) - grade 0, non damage (good morphology), (+) - grade I damage, (++) - grade II damage,
 (+++) - grade III damage, (++++) - grade IV damage (bad morphology).

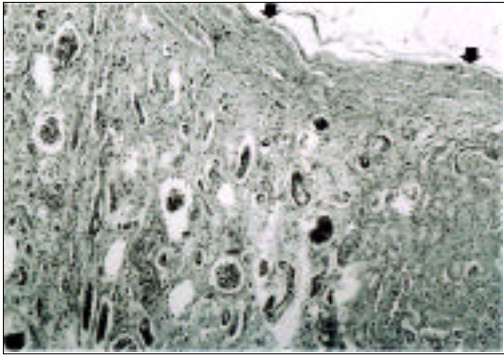


Figure 1 - Microscopic examination of the renal capsule and interstitial fibrosis (arrows) in the control group. (Hematoxylin and eosin $\times 40$).

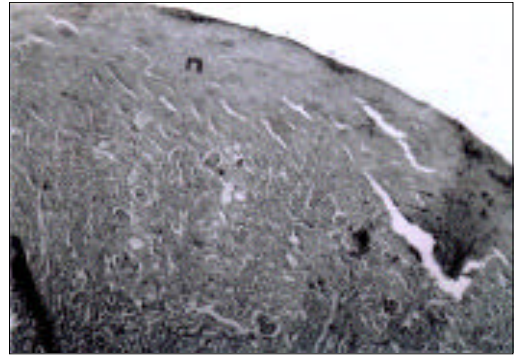


Figure 3 - Microscopic examination of the outer cortex in the chronic gut group. n - diffuse necrosis. (Hematoxylin and eosin $\times 100$).

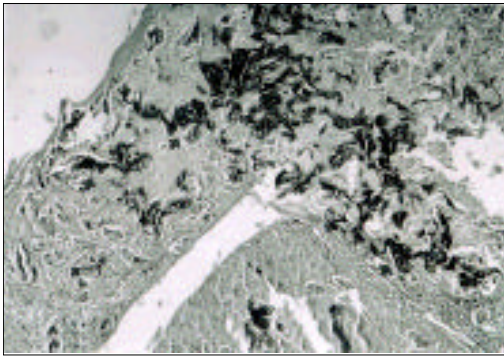


Figure 2 - Microscopic examination showing perirenal hematoma in the collagen powder group (Hematoxylin and eosin $\times 40$).



Figure 4 - Microscopic examination showing diffuse fibrosis and interstitial edema of the glomerules of the polyglactin group. f - diffuse fibrosis. (Hematoxylin and eosin $\times 100$).

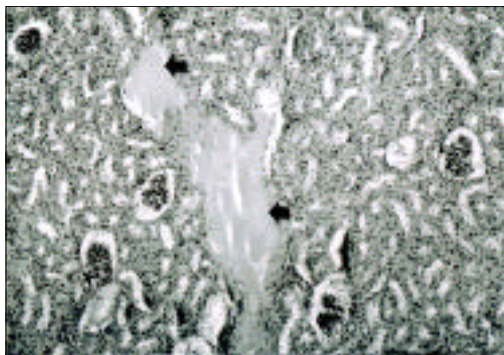


Figure 5 - Microscopic examination showing local interstitial edema (arrows) of the polyglactin mesh group (Hematoxylin and eosin $\times 40$).

was observed in the outer cortex of the chronic gut group (**Figure 3**). Diffuse fibrosis and interstitial edema were seen in most of the glomerules of the polyglactin group (**Figure 4**). Local interstitial edema was seen in the PM group (**Figure 5**). **Table 2** summarizes the tubulointerstitial morphology of all groups on the 90th postoperative day.

Discussion. There have been studies on the various materials and different techniques used for

reconstructing injured kidneys, with many more still developing. We can divide all these studies into 2 groups. First is the diverse new suture materials, second is the new technologic applications such as tissue glues, laser, and photocoagulators. It is possible to find very valuable information on sutures in a detailed review of Edlich et al.⁴ As they command absorbable suture usage is mandatory in the urinary system to prevent calculus formation. They reported that the breaking strength of synthetic absorbable sutures (polyglactin, polydioxanone) is

superior to chromic gut in sterile urine, but this is the opposite in infected urine.⁴ Cohen et al⁵ made similar reports in their research. They reported that the more risky one is the polydioxanone for calculus formation.⁵ Frazier et al⁶ studied a tissue glue butyl cyanoacrylate for reconstructing the kidney. They found that the method was safe, easy and quick in application. However, it requires further safety tests before use in humans.⁶ They declared that these problems will be solved in time, and application of this material during endoscopic procedures will become possible. Holmes et al⁷ studied a different type of tissue glue, developed from fibrin (Tisseel).⁷ It is effective for reconstructing kidneys, but the heat evolved during application and late reabsorption is a major disadvantage. Kouba et al¹ and Griffith et al⁸ evaluated fibrin glue repair upon an animal model. They reported safety, ease of use and efficiency, and the fibrin sealant appears to be an appropriate adjunct for managing challenging renal injuries. In another study, Hick et al⁹ recommended that FloSeal gelatin matrix hemostatic sealant provided effective hemostasis after complex renal injury with and without preliminary vascular control.⁹ Grainger et al¹⁰ studied a very different technology in reconstructing radial nephrotomies: sapphire crystal infrared photocoagulator. They compared this with PM, and found each method safe, easy, and quick in application. However, photocoagulator was not efficient for bleeding from the capsule. The main disadvantage of the coagulator is that it slips away from the nephrotomy site because the operator is required to look away from the probe during application, to protect his retina from the damage by high intensity light during the operation. Kontos et al¹¹ investigated the efficacy and safety of radiofrequency ablation as a kidney-preserving hemostatic technique for grade IV renal trauma, and found this an efficient and safe hemostatic method. Can et al¹² compared PM, collagen powder, collagen sponge and Surgicel in blunt traumas. With the exception of surgical, they found all these methods effective in recovery. Lee et al¹³ and Lau et al¹⁴ researched PM for repair of severely injured kidneys in an experimental study, and found this may also be suitable for uncontrollable bleeding during non extirpative kidney surgery.

As we found none of these methods ideal, this inspired us to conduct this study. We studied different materials that we found in our country. We tried to find the most effective method by scoring the microscopic and macroscopic differences of these materials in both the short and long term upon the renal parenchyma. In **Table 2**, we summarized that the best reconstructed group was the PM group, and thus should be the preferential choice. Yerdel et al¹⁵ supports this, where they applied PM by a

different but more effective technique. Mounzer et al¹⁶ found that PM created a new fibrous capsule around kidney, and reported that PM can help in repairing injured kidneys by securing hemostasis and serving as a scaffold for the formation of a new capsule, agreeing with our study. Easy and quick applications are other advantages, which make PM the most preferential choice in kidney reconstruction. The disadvantages are cost and difficulties in delivery, especially in Turkey. One other disadvantage is the firm fibrosis that develops around kidney, which is more significant than in the other groups, and may make follow-up surgery impossible.

There were no differences in hematocrit values of the groups, probably due to the small lacerations.

Conservative management is well recognized for lower grades of renal injury (I to III), however, in high-grade renal injury (grade IV and V), the role of conservative management remains controversial.¹⁷ In our study, recovery of the control group was inferior to the other groups, which we think occurred because of the grade IV kidney trauma used.

In conclusion, we found PM the easiest, most efficient, safest, and quickest technique in reconstructing kidney surgery or trauma. This technique also improves recovery. We believe that in the future new techniques may alter these findings as the development of technology in this area increases.

References

1. Kouba E, Tornehl C, Lavelle J, Wallen E, Pruthi RS. Partial nephrectomy with fibrin glue repair: measurement of vascular and pelviciceal hydrodynamic bond integrity in a live and abattoir porcine model. *J Urol* 2004; 172: 326-330.
2. Huang SH, Chiu AW, Lin CH, Liu CJ, Huan SK, Lee BS, et al. Efficacy of ultrasonic tissue dissector and tissue glue for laparoscopic partial nephrectomy in a porcine model. *Int Surg* 2003; 88: 199-204.
3. Modi KS, Schreiner GF, Purkerson ML, Klahr S. Effects of probucol in renal function and structure in rats with subtotal kidney ablation. *J Lab Clin Med* 1992; 120: 310-316.
4. Edlich FR, Rodeheaver GT, Thacker JG. Considerations in the choice of sutures for wound closure of the genitourinary tract. *J Urol* 1987; 137: 373-379.
5. Cohen EL, Kirschenbaum A, Genn JF. Preclinical evaluation of PDS synthetic absorbable suture vs chromic surgical gut in urologic surgery. *Urology* 1987; 30: 369-372.
6. Frazier HA, O'connell KJ, Wagner GN, Clark MA. Sutureless renal repair after low-velocity ballistic trauma. *J Urol* 1988; 139: 115-118.
7. Holmes SAV, James M, Whitfield HN. Potential use of tissue adhesive in urinary tract surgery. *Br J Urol* 1992; 69: 647-650.

8. Griffith BC, Morey AF, Rozanski TA, Harris R, Dalton SR, Torgerson SJ, et al. Central renal stab wounds: treatment with augmented fibrin sealant in a porcine model. *J Urol* 2004; 171: 445-447.
9. Hick EJ, Morey AF, Harris RA, Morris MS. Gelatin matrix treatment of complex renal injuries in a porcine model. *J Urol* 2005; 173: 1801-1804.
10. Grainger R, Webb DR, Alken P, Thüroff J, Fitzpatrick JM. The sapphire crystal infrared photocoagulator and polyglactin (Vicryl) mesh: Two new alternatives to the suturing of radial nephrotomies. *Br J Urol* 1986; 58: 484-487.
11. Kontos M, Felekouras E, Drakos E, Pikoulis E, Mitropoulos D, Staikou C, et al. Radiofrequency tissue ablation in an experimental model of grade IV renal trauma: a preliminary report. *Surg Endosc* 2005; 19: 249-253.
12. Can H, Dönmez T, Kale M, Yenilmez A, Kulan S, Varderele E, et al. An experimental study related with the effects of the hemostatic agents (vicryl mesh, collagen powder, collagen sponge, surgical) in blunt renal trauma. Proceedings from the 14th Congress of Turkish Urological Society; 20-23 October 1996. Marmaris, Turkey; *Turkish Journal of Urology* 1996; 3: 122.
13. Lee SS, Cheng CL, Yu DS, Chang SY, Ma CP. Vicryl mesh for repair of severely injured kidneys: an experimental study. *J Trauma* 1993; 34: 406-410.
14. Lau JL, Fowler JE Jr, Stobnicki M, Ray V, Forrest R. Polyglycolic acid mesh in experimental renal trauma. *J Urol* 1986; 136: 715-718.
15. Yerdel MA, Koksy C, Karayalçın K, Kuzu A, Aoyama M, Anadol E. Use of polyglycolic acid mesh with a new double pursestring technique in renal trauma: an experimental study. *Injury* 1993; 24: 158-160.
16. Mounzer AM, McAninch JW, Schmidt RA. Polyglycolic acid mesh in repair of renal injury. *Urology* 1986; 28: 127-130.
17. Rogers CG, Knight V, MacUra KJ, Ziegfeld S, Paidas CN, Mathews RI. High-grade renal injuries in children--is conservative management possible? *Urology* 2004; 64: 574-579.