

### Hemolytic uremic syndrome associated with *Streptococcus pneumoniae*

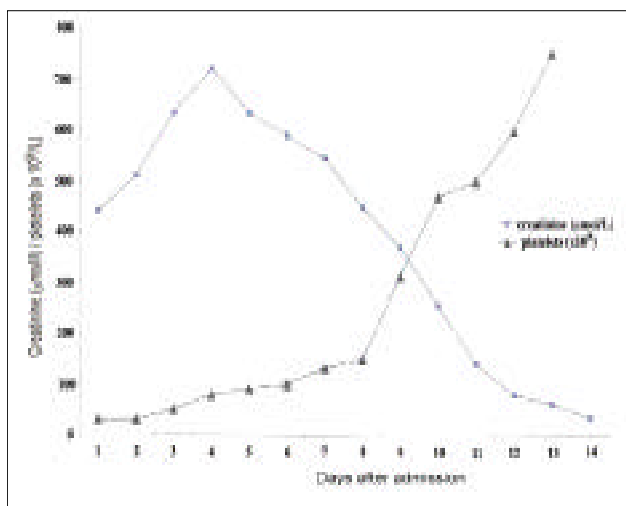
Zaher F. Zaher, CABP, SBP,  
Hammad O. Alshaya, FRCPC, FRCP (UK),  
Jameela A. Kari, MD, FRCP (UK).

The hemolytic uremic syndrome (HUS) is characterized by the simultaneous occurrence of the triad of acute renal insufficiency, microangiopathic hemolytic anemia and thrombocytopenia. The HUS is the most common cause of acute renal failure in infants and young children in western countries. It could be classified into diarrhea positive, D+ (typical) or diarrhea negative, D- (atypical) HUS. In Europe and North America, the typical HUS is the most significant complication of infection by verocytotoxin (VT) producing *Escherichia coli* (VTEC), usually of serotypes O57: H7. While in some developing countries like Bangladesh, South Africa, and Zimbabwe, a severer form of (D+) HUS was reported following *Shigella* dysentery. The atypical (D-) HUS has a worse outcome and could be recurrent. It might be inherited in an autosomal dominant or recessive disorder, like factor H deficiency and hypocomplementemia or associated with other infections like *Streptococcus pneumoniae* (*S. pneumoniae*)<sup>1</sup> or as a complication of using chemotherapy. The (D+) HUS was described in few studies from the Arab world.<sup>2</sup> Similarly, familial HUS was described in children from Saudi Arabia,<sup>3</sup> Kuwait, and Bedouin-Arab of Palestine. However, no case of *S. pneumoniae*-induced HUS was reported from the Arab world. The HUS associated with *S. pneumoniae* is a rare condition but well described in the literature as serious disease, which carries an increased risk of mortality and renal morbidity<sup>1,4,5</sup> compared with (D+) HUS. Pediatricians should be aware that this combination could have devastating complications in the pediatrics population.

A previously well 4-year-old boy was admitted with fever and impaired level of consciousness. He was treated initially with a 3-day course of oral azithromycin as a case of upper respiratory tract infection, before his presentation to us. However, he continued to be febrile and lethargic. On admission, he was drowsy, blood pressure 113/41 mm Hg, temperature 38°C, respiratory rate 30/minute and pulse 138 beats/minute. He looked very sick with labored breathing. There were no rash, and the rest

of systemic examination was unremarkable. He was ventilated and commenced on intravenous ceftriaxone for suspected meningitis. Lumbar puncture (LP) was not carried out initially as the patient was unstable. His initial investigation showed normal hemoglobin (Hb) 11.8 g/dl, and high white blood cell (WBC) 29.6 x 10<sup>9</sup>/L, with 41% neutrophil (12.14 x 10<sup>9</sup>/L). He had low platelets 26 x 10<sup>9</sup>/L, normal prothrombin time 14.6 (11-15), slightly prolonged partial thromboplastin time 50.6 (23-36), very high D dimer 5595, and high fibrinogen degradation products 320 (<5). He had high C reactive protein (CRP) 226, and disturbed liver function tests: aspartate transaminase 441 (15-37 U/L); alanine aminotransferase 118 (30-65 U/L) and lactate dehydrogenase 2574 (150-50 U/L). His chest radiograph showed partial collapse of the right lung with pleural effusion. His initial serum creatinine was 3.4 mg/dl = 299 µmol/L (35-80 µmol/L) and his serum urea was 44 (3-6 mmol/L).

On the second day of admission, he passed dark urine and the analysis of urine revealed hematuria with numerous red blood cells. His urine output (UOP) decreased, and he became oliguric with a progressive increase in his serum creatinine to 5 mg/dl (440 µmol/l), and to 8.2 mg/dl (721 µmol/l) on the fourth day (Figure 1). He became anuric and his Hb dropped to 5.3 gm/dl. He received blood transfusion of unwashed packed red blood cells and unwashed platelets. He was commenced on automated peritoneal dialysis (APD), which continued for 11 days until his UOP improved as well as his serum creatinine (Figure 1). The LP was carried out on the fifth day of his illness and revealed high WBCs in the cerebrospinal fluid (CSF) (6550/high powered field with 28% polymorphs), high protein (2.5 gram/l), and the glucose were 3.1 mmol/l (blood glucose was 5 mmol/L). The CSF culture was negative; however, the latex agglutination specific to *S. pneumoniae* was positive. On the sixth day of the illness, the antibiotic was changed to meropenem as there was no improvement clinically. The patient improved gradually, extubated after 7 days of ventilation and his platelets returned to normal level after 9 days (Figure 1). His renal function also improved and stayed so after discontinuation of APD. He was discharged from the hospital after 4 weeks. His results at discharge: a serum creatinine 49 µmol/L, Hb 9 g/dl, platelets 735 x 10<sup>9</sup>/L. He was reviewed in the clinic 3 months later when a dramatic neurological recovery was observed and he maintained a normal



**Figure 1** - The change in serum creatinine ( $\mu\text{mol/L}$ ) and platelets ( $\times 10^9/\text{L}$ ) during the disease course. Dialysis started on the 4th day of admission for 11 days.

kidney function with creatinine of  $50 \mu\text{L}$ , urea  $4.2$  ( $3-6 \text{ mmol/l}$ ), platelets  $470 \times 10^9/\text{L}$  ( $150-500 \times 10^9/\text{L}$ ), and Hb  $12.3 \text{ gm/dl}$ .

We report a case of atypical HUS associated with invasive pneumococcal infection presented with pneumonia and meningitis. This serious condition with high mortality and morbidity had been described as a rare cause of HUS in the western medical literature.<sup>1,4-5</sup> Brandt et al,<sup>6</sup> described 12 children with HUS associated with *S. pneumoniae* infection, he described that pneumonia with empyema was the most common precipitating illness (67%), *S. pneumoniae* meningitis was present in 17% of children, pneumonia with bacteremia in 8%, and both pneumonia and meningitis in 8% (similar to our case). The pneumococcal organism produces an enzyme (neuraminidase), which can expose an antigen (T-antigen) present on erythrocytes, platelets, and glomeruli. Antibodies to the T-antigen, normally found in human serum, bind the exposed T-antigen, and the resultant antigen-antibody reaction (T-activation) can lead to HUS and anemia.<sup>4</sup> All *S. pneumoniae* organisms produce neuraminidase. However, not all pneumococcal infection results in T activation.<sup>4</sup> Therefore, it is important to diagnose red cell activation once it is suspected. Early detection of T- antigen is beneficial, as it will result in avoidance of transfusion of unwashed blood. Unfortunately, detection of T-antigen is not available to our services. Our patient had severe

illness and required ventilation and dialysis. This is similar to previous reports of *S. pneumoniae*-induced HUS, which are known to be a cause of severe acute hematological disease including disseminated intravascular coagulation or renal disease, leading to death in 29-50% of cases.<sup>5</sup> Long term prognosis is also guarded, Nathanson et al<sup>5</sup>, reported that out of 11 patients, 4 died during the acute phase, among the 7 survived patients, 5 developed end-stage renal failure (ESRF) 4-17 years later. In contrast, Krysan and Flynn,<sup>1</sup> documented in their comprehensive literature review that out of 38 well-documented cases of *S. pneumoniae*-associated HUS, only 3 of which progressed to ESRF, including, their reported case, which was transplanted successfully. They observed that children who progressed to ESRF had a greater duration of oligo-anuria compared with cases who did not progress to ESRF.<sup>1</sup> They also stressed on the significant adverse effect of unwashed blood products, and a possible influence of female gender on outcome.<sup>1</sup> As the use of blood products containing immunoglobulin M may aggravate this disorder, early recognition of HUS with *S. pneumoniae* neuraminidase production may lead to improved patient outcome through the judicious use of blood products. Our patient has received unwashed blood before identifying the *S. pneumoniae* by agglutination test. However, we observed no deterioration in clinical condition or aggravation of hemolysis. This may support the view of Nathanson<sup>5</sup> in his report, were 7 out of 11 patients transfused unwashed red blood cells and none exhibited a life-threatening disease or worsening of hemolytic anemia. He concluded that despite the theoretical risk, an adverse effect of unwashed blood transfusions containing limited amounts of plasma remains to be demonstrated in *S. pneumoniae*-induced HUS. Furthermore, some investigators recently have questioned the risk of transfusing plasma in patients demonstrating T-activation and others have suggested that these events are the result of infection with a verocytotoxin-producing strain of *S. pneumoniae*, and not the result of neuraminidase activity.<sup>4</sup> Our patient was oliganuric and needed only 11 days of dialysis, while the reported mean duration of dialysis on such patients is 32 days.<sup>5</sup> This may also have influenced the favorable outcome of our patient. Recent reports described an increased association of *S. pneumoniae* and HUS<sup>4</sup> and therefore, there is a need for more awareness among pediatricians about this serious condition.

# Clinical Notes

Received 30th April 2005. Accepted for publication in final form 12th July 2005.

From the Department of Pediatrics, King Abdul-Aziz University Hospital, Jeddah, Kingdom of Saudi Arabia. Address correspondence and reprint requests to Dr. Jameela A. Kari, Department of Pediatrics, King Abdul-Aziz University Hospital, PO Box 80215, Jeddah 21589, Kingdom of Saudi Arabia. Tel. +966 55677904. Fax. +966 (2) 6732410. E-mail: jkari@doctors.org.uk

## References

1. Krysan DJ, Flynn JT. Renal transplantation after *Streptococcus pneumoniae*-associated hemolytic uremic syndrome. *Am J Kidney Dis* 2001; 37: E15.
2. Al-Eisa A, Al-Hajeri M. Hemolytic uremic syndrome in Kuwaiti Arab children. *Pediatr Nephrol* 2001; 16: 1093-1098.
3. Mattoo TK, Mahmood MA, Al-Harbi MS, Mikail I. Familial, recurrent hemolytic-uremic syndrome. *J Pediatr* 1989; 114: 814-816.
4. Cochran JB, Panzarino VM, Maes LY, Tecklenburg FW. Pneumococcus-induced T-antigen activation in hemolytic uremic syndrome and anemia. *Pediatr Nephrol* 2004; 19: 317-321.
5. Nathanson S, Deschenes G. Prognosis of *Streptococcus pneumoniae*-induced hemolytic uremic syndrome. *Pediatr Nephrol* 2001; 16: 362-365.
6. Brandt J, Wong C, Mihm S, Roberts J, Smith J, Brewer E, et al. Invasive pneumococcal disease and hemolytic uremic syndrome. *Pediatrics* 2002; 110: 371-376.