

Cardiotoxicity resembling myocardial infarction that occurs during chemotherapy with 5-fluorouracil

Mehmet Gul, MD, Akif Duzenli, MD, Metin Bircan, MD,
Basar Cander, MD, Sedat Koçak, MD,
Kurtulus Ozdemir, MD.

The antimetabolite, 5 Fluorouracil (5-FU), is a common chemotherapeutic agent used in the treatment of solid cancer of the chest, ovarian, cervix, gastrointestinal system, prostate gland and bladder. The most common side effects of this drug are stomatitis, nausea, vomiting, diarrhea and bone marrow depression.¹ Cardiotoxicity due to 5-FU is unusual, but with serious adverse effect. There are no descriptions yet, of the mechanism of cardiotoxicity. Cardiotoxic effects that occur infrequently develop due to coronary artery spasm.^{2,3} In this presentation we analyzed the symptoms that occur after chemotherapy with 5-FU in a young patient who has no other problems.

A 40-year-old woman, diagnosed with descending colon adenocarcinoma was planned for treatment with 5-FU as 5 cure. We started treatment with 5-FU, 15 mg/kg/2 hours. Squeezing chest pain developed at the first cure of the treatment. The chest pain radiated to the left arm, accompanied with sweating, nausea, and vomiting. Peaked T wave of approximately 15 mm in V3-V6 of the precordial leads, suggesting hyperacute myocardial infarction was established on ECG (**Figure 1**). Thus, we discontinued 5-FU infusion and administered glycerol trinitrate infusion (0.1 mg/min). The glycerol trinitrate infusion was increased up to 2 mg/min. After 30 minutes the chest pain resolved, the peaked T wave flattened and negative T waves developed. However, the chest pain recurred, and a similar peaked T wave on ECG was determined despite glycerol trinitrate infusion being continued. Therefore, a bolus of verapamil was administered in addition to the glycerol trinitrate infusion. After 20 minutes, the chest pain resolved and the ECG was completely normal. She was followed in the intensive care unit for 2 days, but chest pain did not recur. There was no history of no risk factors including hypertension, smoking, family history and diabetes mellitus. The cardiovascular examination was normal. Blood pressure was 120/80 mm Hg, and heart rate was 75 beat/minute. According to laboratory tests, creatin kinase-myocardial band (CK-MB) (normal range 0.3-4 ng/ml) and troponin I (normal range 0.0-0.03 ng/ml) values were normal, total cholesterol 133 mg/dl (normal range 130-240

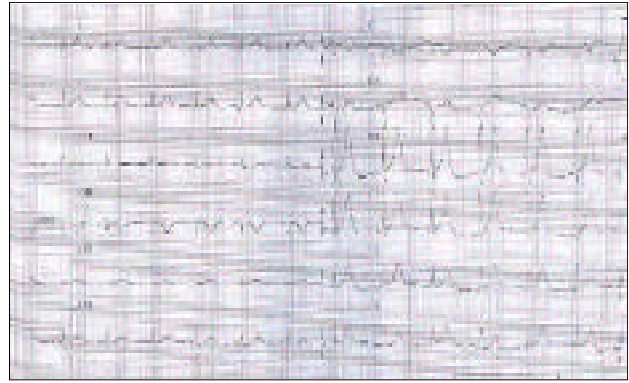


Figure 1 - Electrocardiography shows the peaked T wave during chest pain.

mg/dl), triglyceride 57 mg/dl (normal range 40-160 mg/dl), high-density lipoprotein 40 mg/dl (normal range 30-70 mg/dl), low-density lipoprotein 82 mg/dl (normal range 70-150 mg/dl). Other biochemical and hematologic findings were also normal. Left ventricular functions on ECG examination and exercise test on the third day were assessed as normal. Coronary angiography was performed to detect coronary artery disease.

This case indicates that vasospasm can be an important outcome of chemotherapy with 5-FU, and we should consider vasospasm in a patient with ECG findings suggestive of hyperacute myocardial infarction undergoing chemotherapy. Severe 5-FU cardiotoxicity is unusual, but documented. A previous study¹ reports intravenous infusion of the drug to cause angina, myocardial infarction, acute pulmonary edema, supraventricular and ventricular arrhythmias, and sudden death. Although the incidence of angina related to application of 5-FU is between 1.2-18%, severe or life threatening cardiotoxicity, as ST segment elevation on ECG or ventricular arrhythmias, is rarer, with an incidence of approximately 0.55%.^{2,3}

Cardiac adverse effects occur commonly at the first cure of the treatment, and diminish on discontinuation of the drug. The mechanism of toxicity is not known, but it focuses on the potential vasospastic effect of the drug.⁴ This present case also suggests that the cause of ECG changes along with chest pain is vasospasm. Clinicians have not widely identified 5-FU cardiotoxicity, however, there are publications on induction of coronary vasospasm by 5-FU prevented by prophylactic calcium channel blockers.⁴ In this case, the typical chest pain and ECG abnormalities resolved by intravenous glycerol trinitrate, aspirin and calcium

Clinical Notes

channel blocker. Moreover, the normal coronary angiography supports vasospasm as the mechanism of cardiotoxicity.

In a prospective clinical trial,⁵ investigating cardiotoxicity related to the application of high dose infusion of 5-FU (600-1000 mg/m²/day), results reported the cardiotoxicity rate as 7.6%. In the same trial, 65% of the patients experienced cardiotoxicity ST segment deviation and inverted T wave. The literature rarely reports the incidence of cardiotoxicity related to application of 5-FU in the early age group (20-40 years), however, previous studies describe other complications of 5-FU, without ischemic symptoms and findings. Due to the effective method of treatment, and prophylaxis of cardiotoxicity of 5-FU application, patients administered 5-FU must be selected carefully, with discontinuation of infusion on the detection of any symptoms or findings of ischemia. This case demonstrates that parenteral calcium channel blockers, in addition to glycerol trinitrate, are also effective in the treatment of symptoms considered to occur due to vasospasm.

Although the life-threatening vasospasm effects of 5-FU application rarely occur, we should carefully monitor patients. On detection of ischemic signs or findings, we should discontinue the drug

and initiate glycerol trinitrate and a calcium channel blocker.

Received 11th April 2005. Accepted for publication in final form 13th August 2005.

From the Department of Emergency Medicine (Gul, Bircan, Cander, Koçak) and the Department of Cardiology (Duzenli, Ozdemir), Faculty of Medicine, Selçuk University, Konya, Turkey. Address correspondence and reprint requests to Dr. Mehmet Gul, Emergency Medicine Department, Meram Medical Faculty of Selçuk University, Meram 42080, Konya, Turkey. Tel. +90 (332) 2237242. Fax. +90 (332) 2236182. E-mail: mehmetgul156@yahoo.com

References

1. De Forni M, Armand JP. Cardiotoxicity of chemotherapy. *Curr Opin Oncol* 1994; 6: 340-344.
2. Keefe DL, Roistacher N, Pierri MK. Clinical cardiotoxicity of 5-fluorouracil. *J Clin Pharmacol* 1993; 33: 1060-1070.
3. Luwaert RJ, Descams O, Majois F, Chaudron JM, Beauduin M. Coronary artery spasm induced by 5-fluorouracil. *Eur Heart J* 1991; 12: 468-470.
4. Mizuno Y, Hokamuro Y, Kimura T, Kimura Y, Kaikita K, Yasue H. A case of 5-fluorouracil cardiotoxicity simulating acute myocardial infarction. *Jpn Circ J* 1995; 59: 303-307.
5. De Forni M, Malet-Martino MC, Jaillais P, Shubinski RE, Bachaud JM, Lemaire L, et al. Cardiotoxicity of high-dose continuous infusion fluorouracil: a prospective clinical study. *J Clin Oncol* 1992; 10: 1795-1801.