

# Influence of ovariectomy and flutamide treatment on vaginal tissue and body weight

Berna G. Saruhan, PhD, Davut Ozbag, PhD, Yakup Gumusalan, MD, Nurullah Ozdemir, PhD.

---

## ABSTRACT

**Objective:** To determine the effect of flutamide on vaginal histology, and to ascertain whether flutamide regulates body weight gain in the ovariectomized rat model.

**Methods:** We chose 36 sexually mature female Wistar-Albino rats in this study. The study took place in the Department of Medical Science Application and Research Center of Dicle University, Diyarbakir, Turkey, in 2002. We divided the model rats into 3 groups: group 1 - control group, group 2 - sham-operated group and group 3 - bilaterally ovariectomized group. In addition, we gave flutamide to group 3.

**Results:** We found that the body weight was higher in the ovariectomized rats than the control rats. Furthermore, the body weight decreased a little after

flutamide therapy. The thickness in the vaginal epithelium of the control group decreased, moreover, the appearance of stromal tissue was rather loose. After flutamide applications, infiltration of the stromal cells increased, the vaginal epithelial layer thickened and became keratinized. Microscopic papillae and anatomical processes appeared in the flutamide treated group.

**Conclusion:** We observed that the antiandrogen drug flutamide is hormonally active and may exhibit estrogenic-antiestrogenic activity in rats. Our study may be a source for further research examining the relationship between the androgen receptor antagonist flutamide and reproductive function in female rats.

Saudi Med J 2005; Vol. 26 (12): 1897-1903

---

Flutamide, an androgen receptor antagonist, and finasteride, a 5 $\alpha$  reductase inhibitor, are antiandrogens used in human clinical practice. Flutamide, used commonly for the treatment of prostate cancer, is also widely used in research on endocrine disruptors.<sup>1</sup> Suppressive effects of flutamide on sexual maturation and behavior have been reported in rats when administered during the perinatal period or to offspring immediately after birth.<sup>2-8</sup> Chemicals that modulate the transcriptional activity of androgen receptor can be divided into 2 structural (steroidal and nonsteroidal) and 2 functional (androgenic and antiandrogenic) classes. Steroidal androgens, mainly testosterone and its derivatives, have been used clinically as

replacement therapies for androgen-deficiency.<sup>9-10</sup> Antiandrogens are used to counteract the undesirable actions of excessive androgens (example, to treat acne, hirsutism, male-pattern baldness, and androgen-dependent prostates hyperplasia and carcinoma).<sup>11-12</sup> Nonsteroidal antiandrogens, such as flutamide, nilutamide, and bicalutamide, are often referred to as 'pure antiandrogens' because they bind exclusively to the androgen receptor, and therefore, are devoid of antigonadotropic, antiestrogenic and progestational effects. These agents are advantageous over steroidal antiandrogens in terms of specificity, selectivity and pharmacokinetic properties.<sup>13</sup> Antiandrogens are widely used in the treatment of

---

From the Departments of Histology and Embryology (Saruhan), Departments of Pharmacology and Toxicology (Ozdemir), Veterinary Medicine Faculty, University of Dicle, Diyarbakir, and the Department of Anatomy (Ozbag, Gumusalan), University of Sutcu Imam, Kahramanmaraş, Turkey.

Received 30th May 2005. Accepted for publication in final form 3rd October 2005 .

Address correspondence and reprint request to: Dr. Berna G. Saruhan, Departments of Histology and Embryology, Faculty of Veterinary Medicine, University of Dicle, Diyarbakir, Turkey. Tel. +90 (412) 2488020 ext. 8627. Fax. +90 (412) 2488021. E-mail: bsaruhan@dicle.edu.tr

women with various hyper-androgenic conditions, including polycystic ovary syndrome, idiopathic hirsutism, acne, seborrhea and hair loss.<sup>13-15</sup> In recent years, there has been growing interest in the development of nonsteroidal modulators for steroid hormone receptors as therapeutic agents. In addition to the above-discussed nonsteroidal antiandrogens, selective estrogen receptor modulators and nonsteroidal modulators for progesterone receptor have been successfully developed.<sup>16-20</sup>

Anabolic-androgenic steroids (AAS) are synthetic derivatives of testosterone that has been abused by athletes in an attempt to improve athletic performance.<sup>21</sup> In contrast to AAS abused by adolescent males, which have remained at a steady level since 1991, AAS abused by adolescent females has actually increased during this same time period.<sup>22</sup> The AAS abused by females has been associated with several adverse effects, including menstrual abnormalities and reproductive dysfunction.<sup>23-25</sup> Studies have been focused on the adverse effects of AAS abuse in adult females.<sup>23-26</sup> However, the physiological effects of AAS abuse by adolescent females are largely unknown, and there are concerns regarding some of the effects, which might be permanent.<sup>24</sup> In rat models, there is overwhelming evidence that puberty can be advanced by estrogen and aromatically androgens.<sup>27-28</sup> Menopause metabolic syndrome may in part be attributable to estrogen deficiency, and may be reversible with estrogen replacement therapy or hormone replacement treatment.<sup>29</sup> Previous studies have shown that administration of androgens to ovariectomized rats inhibits estrogen-induced sexual receptivity. Example to this are testosterone propionate, dihydrotestosterone propionate, and 3 androstanediol inhibit the induction of sexual receptivity by estradiol benzoate.<sup>30-31</sup> Recently, synthetic androgens, such as 17 -methyltestosterone, stanozolol and nandrolone decanoate, have also been shown to inhibit estrogen-induced sexual receptivity in ovariectomized rats.<sup>32</sup> Evidence that the androgen receptor is involved in the androgenic inhibition of sexual receptivity has been provided by studies using flutamide, an androgen receptor antagonist.<sup>33</sup> Flutamide has been shown to block the inhibitory effects of naturally occurring androgens on estrogen-induced sexual receptivity in ovariectomized rats.<sup>34</sup> More recently, however, it was shown that flutamide failed to block the inhibitory effects of dihydrotestosterone on sexual receptivity induced by short-term treatment with unesterified estradiol-17 E<sub>2</sub> in combination with progesterone.<sup>35</sup>

Recent studies confirmed previous observations that estrogen deficiency significantly increased the weight gain in ovariectomized rats, an effect that

was attenuated by estrogen treatment.<sup>36</sup> Compared to nonsteroidal androgens, which were only recently conceptualized, nonsteroidal antiandrogens were used clinically for many years.

Nonsteroidal antiandrogens were extensively reported; some of these (namely, flutamide<sup>3</sup> and bicalutamide<sup>4</sup>) are successfully used in clinics for the treatment of androgen receptors dependent prostate cancer. There are 3 nonsteroidal antiandrogens that are currently available bicalutamide, flutamide and nilutamide. These drugs antagonize the actions of androgens at the receptor level and thereby inhibit tumor growth. Nonsteroidal antiandrogens block the negative feedback mechanism that regulates testosterone levels.<sup>37</sup>

We aim to explore the effects of ovariectomy and treatment with flutamide on vaginal tissue in this study.

**Methods.** Thirty-six, 3-month-old Wistar-Albino female rats, each weighing approximately 200-210 g, obtained from the Department of Medical Science Application and Research Center of Dicle University, Diyarbakir Turkey were used in this study. The rats were acclimated to the local vivarium conditions (22°C and 12h/12h light-dark cycle) for 2 months. They were singly housed in 34 cm x 47 cm x 17 cm cages during the experimental period. All rats were allowed free access to water and a pelleted commercial diet containing 0.97% calcium, 0.85% phosphorus, and 1.0.5 IU/g of vitamin D3. The rats were divided into 3 groups of 12.

Animals in group 1 (control group) was also established with administration of carrier A [1:3 mixture of 100% ethanol and 0.9% saline W/V (Boots Co., Australia)] each day for 3 days. The animals of this group did not receive ovariectomy nor did they receive flutamide treatment. Carrier A injection was given to create the stress environment as in the 2 other animal groups. Surgical ovariectomy was performed to group 2 and 3 rats.

**Ovariectomy.** All rats in group 2 and 3 were food-deprived prior to surgery. For the ovariectomies, the rats were anesthetized by intraperitoneal injection of Ketamine (50 mg/kg body wt. Parke-Davis) and xylazine HCL 2% (100 mg/kg body weight Rompun - Bayer).<sup>38</sup> Bilateral ovariectomies were performed in 24 animals using a dorsal approach in a sterile surgical theater. After bilateral ovariectomy, the rats were allowed to recover for 6-8 weeks before treatment. The control rats (Group 1) were subjected to a sham operation in which the ovaries were exteriorized but left intact. Group 2 was designated as sham-operated group. The rats were subcutaneously injected with

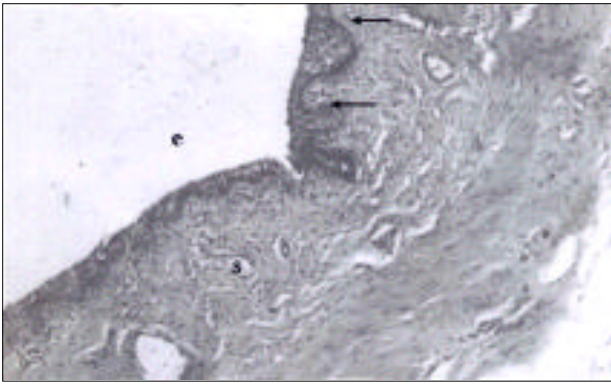


Figure 1 - The appearance of vaginal epithelium (e) (microscopic papilla (→) and stroma (s) was normal in the control group. (Hematoxylin-eosin, original magnification x 100).



Figure 3 - Vaginal epithelium of experimental rat given flutamide. Increased in the thickness of the epithelium layer and keratinized epithelium (→). (Hematoxylin-eosin, original magnification x 200).




Figure 2 - Vaginal epithelium of sham-operated group animals showing typical atrophied appearance of the epithelium non-keratinized (black arrows), and disappearance of microscopic papilla, the appearance of stromal tissue was rather loose (white arrows). (Hematoxylin-eosin, original magnification x 100).

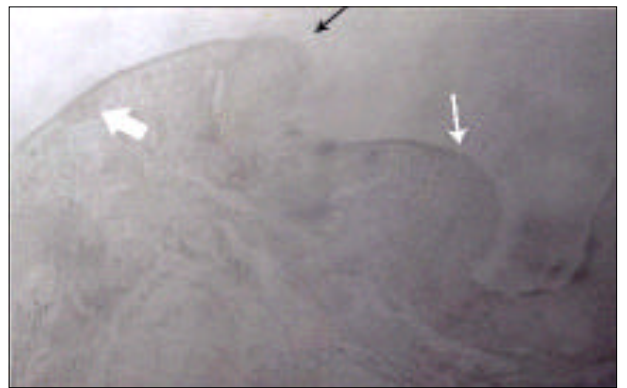


Figure 4 - Increased in the thickness of the epithelium layer (↔), keratinized (white thin arrow) and appearance of microscopic papilla and papillary process (white thick arrow), can be seen. (Hematoxylin-eosin, original magnification x 200).




Figure 5 - Increased in the thickness of the epithelium layer, keratinized (black arrow) and appearance of microscopic papilla (white arrows), infiltration of the stromal cells (star) was increased. (Hematoxylin-eosin, original magnification x 100).

Table 1 - Comparison of weights of the body.

Groups	At the start of experiment	After 2 months (ovx)	Following 3 days of drug administration
Group 1 (n=12)	204.83 ± 1.1 <sup>a</sup>	222.08 ± 0.70 <sup>a</sup>	222.08 ± 0.7 <sup>a</sup>
Group 2 (n=12)	203.50 ± 0.96 <sup>a</sup>	284.58 ± 2.71 <sup>b,d</sup>	284.58 ± 2.71 <sup>b,d</sup>
Group 3 (n=12)	205 ± 1.03 <sup>a</sup>	284.58 ± 2.60 <sup>c,d</sup>	279.75 ± 1.59 <sup>c,d</sup>
Means within a column not followed by the same letter differ significantly ( $p=0.05$ ).			

Table 2 - Comparison of the live weight means of the control group with other groups after the second month.

Groups	At the start of experiment	After 2 months
Group 1 (n=12)	204.83 ± 1.1 <sup>a</sup>	222.08 ± 1.2 <sup>a</sup>
Group 2, 3 (n=24)	203.33 ± 0.71 <sup>a</sup>	284.58 ± 1.8 <sup>b</sup>
Means within a column not followed by the same letter differ significantly ( $p=0.05$ )		

equivalent amount 0.1 ml of a 1:3 mixture of benzyl alcohol and peanut oil (carrier B), each day for 3 days. Carrier B injection was given in order to create the stress environment as in the 2 other animal groups. Group 3 was designated as sham-operated and flutamide group. Animals in this group were given oral gavage 10 mg /100g flutamide (Eulexin 250 mg tablet) each day for 3 days.

After approximately 2 months of ovariectomy, the animals were anesthetized and killed by cardiac exsanguinations. The pelvic region was seen to be far too much fatty at autopsy. Vaginae were removed, fixed in formalin fluid and embedded in paraffin. Five-micron sections were cut using a Leica RM 2125 RT and the sections were stained with hematoxylin-eosin. The stained sections were later evaluated with light microscopy.

In all experiments, body weights were measured daily using top-loading balance and the person measuring the body weight was blinded to each treatment group. Food intake was determined by estimating the amount of food consumed by the mice throughout the treatment period.

**Statistical analysis.** Data are expressed as mean ± SEM. Statistics were calculated using Minitab. The analysis of variance (ANOVA) test followed by Fisher's was used to compare the differences between groups.<sup>16</sup>

**Results. Vaginal histology.** We observed no pathology in the vaginal epithelium of the control

group. The lumen of the vagina was lined by a thick stratified squamous non-keratinized epithelium. The lamina propria of mucosa is composed of a loose fibro elastic connective tissue containing a rich vascular supply in its deeper regions (**Figure 1**).

In the sham-operated group, the thickness in the vaginal epithelium (typical atrophied appearance of the epithelium) decreased and disappearance of microscopic papilla, moreover, the appearance of stromal tissue was rather loose (**Figure 2**).

We observed increase in the thickness of the epithelium and keratinization, appearance of microscopic papilla and papillary processes in the flutamide treated group. After flutamide applications, infiltration of the stromal cells increased (**Figure 3-5**).

As a result, bilateral ovariectomy was determined to cause atrophy in vaginal epithelium of rats. When flutamide was administered later, thickening and keratinization due to hyperplasia in vaginal epithelium were observed. In this study, we found out that the antiandrogen drug flutamide is hormonally active and may exhibit estrogenic-antiestrogenic activity.

**Body Weight.** Our results show that body weight significantly increased in ovariectomized rats. Comparison of the starting means of the control group and other 24 animals at the start of trial were found to be insignificant (**Table 1**). Comparison of the live weight means of control group with the other animals after the second month (post ovariectomy) were found to be significant (**Table 2**) ( $p<0.05$ ). According to the Fisher Tukey test, the difference between the last weight means of animal groups having only ovariectomy and then whether receiving the drug or without receiving the drug was found to be insignificant (**Table 1**). The differences between the weight means of animal groups 1 and 2, and also groups 1 and 3 were found to be significant following the administration of the drug (**Table 1**) Paired t-test; the given drug did not cause any difference in the same weight of animals before and after the administration of the drug combinations following Tukey Checking test (**Table 1**).

In this trial, paired t-test was performed in order to clarify whether the administration of the drug was

effective in those animals, and it was determined that administration of the drug was not effective on body weight ( $p > 0.05$ ) ( $-4.83 \pm 2.31$ ).

We observed that the body weight increased significantly in the ovariectomized rat. Furthermore, the body weight decreased a little after flutamide therapy.

**Discussion.** It is well known that vaginal tissues in different animal species, including human vaginal tissue, respond to the action of endogenous or exogenous estrogens. Estrogen receptors (ER) have been reported in vaginal tissues of various species, namely, rabbits, mouse and humans.<sup>39</sup> The lamina epithelialis thickness of vagina in rats and domestic animals are less than humans. Furthermore, the form of cell on the surface is related with cycles. Exogenous estrogens have teratogenic and carcinogenic effects on the developing female genital tract of both laboratory animals and humans.<sup>40</sup> Steroidal and nonsteroidal estrogens such as diethylstilbestrol elicit adverse effects. Certain triphenylethylene compounds, such as clomiphene, tamoxifen, and nafoxidine are hormonally active and may exhibit antiestrogenic activity. However, in many species, including subhuman primates, these compounds also have significant estrogenic activity.<sup>41</sup> Moreover, in developing rodents, clomiphene and tamoxifen elicit the development of genital tract lesions similar to those usually associated with exposure to exogenous estrogens.<sup>42</sup>

Flutamide is a nonsteroidal antiandrogen that conceivably exerts its major effects by blocking the nuclear binding of androgens to their receptors.<sup>43</sup> Some androgens are known to exert both estrogenic/antiestrogenic and progestational effects in female rats.<sup>44-46</sup> The studies presented here were carried out to evaluate this effect of flutamide, a potent androgen, which has potential use in male contraception and hormone replacement therapy. The physiological role of androgen action in females is not clear.<sup>47</sup> In males, however, the ratio of androgen to estrogen is considered important to protect them from the feminizing effects of estrogen.<sup>48</sup> Several studies have demonstrated that, histologically, the vaginal epithelium showed stratification and cornification in flutamide treated rats. In those rats, vaginal epithelium was hypertrophied and gave the appearance of stratification.<sup>49</sup>

Endometrial and vaginal epithelium undergoes specific transformations under the influence of gestagens. Oral administration of 1 mg flutamide to ovariectomized rats induced antiestrogenic effect on vaginal epithelium. Full antiestrogenic response was observed in rat vaginal tissue after oral administration of flutamide.<sup>50</sup> Antiestrogens may be

more or less as hormonally active as estradiol depending on parameter and dose. The vaginal epithelium showed stratification and cornification in estradiol treated rats. In tamoxifen treated rats, vaginal mucosa was slightly hypertrophied and gave the appearance of stratification.<sup>49</sup> The effect of flutamide on the antiestrogenic effect was investigated in ovariectomized rats. When flutamide was given, the flutamide effect induced vaginal cornification. In this study, we observed the antiandrogen drug flutamide was hormonally active in the vaginal epithelium similar to antiestrogens. In earlier studies to establish the relationship between flutamide administration and ovariectomy, we observed that ovariectomy estrogens and antiestrogens can cause some histopathologic changes in female genital system.<sup>51,52</sup> In this study, we determined that flutamide eliminated the problems experienced following ovariectomy.

Recent research has reported that the body weight was higher in the ovariectomized rats than the intact rats.<sup>53</sup> In another experimental study, it was observed that ovariectomy increased body weight.<sup>54</sup> Further studies have shown that body weight significantly increased in ovariectomized rat.<sup>55</sup> These results support the hypothesis that alternation of estrogen status may be related to the development of obesity. Estrogen not only participates in the regulation of body weight, but also modulates insulin sensitivity.<sup>56</sup>

## References

1. Balk P. Androgen receptor as a target in androgen-independent prostate cancer. *Urology* 2002; 60: 132-138.
2. Clemens LG, Gladue BA, Coniglo LP. Prenatal endogenous androgenic influences on masculine sexual behaviour and genital morphology in male and female rats. *Horm Behav* 1978; 10: 40-53.
3. Brand T, Slob AK. Perinatal flutamide and mounting and lordosis behaviour in adult female Wistar and Sprague-Dawley rats. *Behav Brain Res* 1991; 44: 43-51.
4. Zimmerberg B, Farley MJ. Sex differences in anxiety behaviour in rats: Role of gonadal hormones. *Physiol Behav* 1993; 54: 1119-1124.
5. Lund TD, Salyer DL, Fleming DE, Lephart ED. Pre- and postnatal testosterone and flutamide effects on sexually dimorphic nuclei of the rat hypothalamus. *Brain Res Dev Brain Res* 2000; 120: 261-266.
6. Gladue BA, Clemens LG. Androgenic influences on feminine sexual behaviour in male and female rats: Defeminization blocked by prenatal androgen treatment. *Endocrinology* 1978; 103: 1702-1709.
7. Matusczyk JV, Larsson K. Sexual preference and feminine and masculine sexual behaviour of male rats parentally exposed to antiandrogen or antiestrogen. *Horm Behav* 1995; 29: 191-206.
8. Miyata K, Yabushita S, Sukata T, Sano M, Yoshino H, Nakanishi T, Okuda Y, Matsuo M. Effects of perinatal exposure to flutamide on hormones and androgen dependent organs in F1 male rats. *J Toxicol Sci* 2002; 27: 19-33.

9. Wu FC. Testicular steroidogenesis and androgen use and abuse. *Baillieres Clin Endocrinol Metab* 1992; 6: 373-403.
10. Bagatell CJ, Bremner WJ. Androgens in men-uses and abuses. *N Engl J Med* 1996; 334: 707-714.
11. Neumann F. Pharmacology and clinical use of antiandrogens: a short review. *Ir J Med Sci* 1982; 151: 61-70.
12. McLeod DG. Antiandrogenic drugs. *Cancer* 1993; 71: 1046-1049.
13. Neri R, Peets E, Watnick A. Anti-androgenicity of flutamide and its metabolite Sch 16423. *Biochem Soc Trans* 1979; 7: 565-569.
14. Cockshott ID, Copper KJ, Sweetmore DS, Blacklock NJ, Dennis L. The pharmacokinetics of casodex in prostate cancer patients after single and during multiple dosing. *Eur Urol* 1990; 18: 10-17.
15. Teutsch G, Goubet F, Battmann T, Bonfils A, Bouchoux F, Cerede E, et al. Nonsteroidal antiandrogens: synthesis and biological profile of high-affinity ligands for the androgen receptor. *J Steroid Biochem Mol Biol* 1994; 48: 111-119.
16. Hamann LG, Winn DT, Pooley CL, Tegley CM, West SJ, Farmer LJ, et al. Nonsteroidal progesterone receptor antagonists based on a conformationally-restricted subseries of 6-aryl-1,2-dihydro 2,2,4 trimethylquinolines. *Bioorg Med Chem Lett* 1998; 8: 2731-2736.
17. Mitlak BH, Cohen FJ. Selective estrogen receptor modulators: a look ahead. *Drugs* 1999; 57: 653-663.
18. Weryha G, Pascal-Vigneron V, Klein M, Leclere J. Selective estrogen receptor modulators. *Curr Opin Rheumatol* 1999; 11: 301-306.
19. Zhi L, Tegley CM, Kallel EA, Marschke KB, Mais DE, Gottardis MM, et al. 5 Aryl-1,2-dihydrochromenol (3,4) flquinolines: a novel class of nonsteroidal human progesterone receptor agonist. *J Med Chem* 1998; 41: 291-302.
20. Zhi L, Tegley CM, Pio B, West SJ, Marschke KB, Mais DE et al. Nonsteroidal progesterone receptor antagonists based on 6-thiophenehydroquinolines. *Bioorg Med Chem Lett* 2000; 10: 415-418.
21. Wilson JD. Androgen abuse by athletes. *Endocrine Reviews* 1988; 9: 181-199.
22. Bahrke MS, Yesalis CE, Brower KJ. Anabolic-androgenic steroid abuse and performance enhancing drugs among adolescents. *Child Adolesc Psychiatr Clin N Am* 1998; 7: 821-838.
23. Strauss RH, Liggett MT, Lanese RR. Anabolic steroid use and perceived effects in ten weight-trained women athletes. *JAMA* 1985; 253: 2871-2873.
24. Strauss RH, Yesalis CE. Additional effects of anabolic steroids on women. In: Yesalis CE, editor. *Anabolic Steroids in Sport and Exercise*. Champaign IL: Human Kinetics Publishers; 1993. p. 151-160.
25. Yesalis CE, Barsukiewicz CK, Kopstein AN, Bahrke MS. Trends in anabolic-androgenic steroid use among adolescents. *Arch Pediatr Adolesc Med* 1997; 151: 1197-1206.
26. Copeland J, Peters R, Dillon P. A study of 100 anabolic-androgenic steroid users. *Med J Aust* 1998; 168: 311-312.
27. Ramirez VD, Sawyer CH. Advancement of puberty in the female rat by estrogen. *Endocrinology* 1965; 76: 1158-1189.
28. Ojeda SR, Urbanski HF. Puberty in the rat. In: Knobil E, Neil JD, editors. *The Physiology of Reproduction*, 2nd ed. New York: Raven Press; 1994. p. 363-409.
29. Knop RH. Risk factors for coronary artery disease in women. *Am J Cardiol* 2002; 89: 28-34.
30. Baum MJ, Sodersten P, Vreeburg JTM. Mounting and receptive behaviour in the ovariectomized female rats: Influence of estradiol, dihydrotestosterone, and genital anesthetization. *Horm Behav* 1974; 5: 175-190.
31. Dohanich GP, Clemens LG. Inhibition of estrogen activated sexual behaviour by androgens. *Horm Behav* 1983; 17: 366-373.
32. Blasberg ME, Clark AS. Anabolic androgenic steroid effects on sexual receptivity in ovariectomized rats. *Horm Behav* 1997; 32: 201-208.
33. Simard J, Luthy I, Guay J, Belanger A, Labrie F. Characteristics of interaction of the antiandrogen flutamide with the androgen receptor in various target tissues. *Mol Cell Endocrinol* 1986; 44: 261-270.
34. Erskine MS, Marcus JI, Baum MJ. Effect of antiandrogen and 5 reductase inhibitor on hormone induced sexual behaviour during pregnancy in the rat. *Biol Reprod* 1980; 23: 767-775.
35. Erskine MS. Effect of 5 dihydrotestosterone and flutamide on the facilitation of lodosis by LHRH and naloxone in estrogen primed female rats. *Physiol Behav* 1989; 45: 753-759.
36. Lerner LJ, Hilf R. Effects of hormone antagonists on morphological and biochemical changes induced by hormonal steroids in the immature rat uterus. *Recent Prog Horm Res* 1964; 20: 721-726.
37. Donghua Y, Yali HE, Minoli A. Key structural features of nonsteroidal ligands for binding and activation of the androgen receptor. *Mol Pharmacol* 2003; 63: 211-223.
38. Karnam RP, Pao LW, Calogero D. Effects of surgical ovariectomy on rat salivary gland function. *Arch Oral Biol* 1993; 38: 779-784.
39. Furr BJA, Jordan VC. The pharmacology and clinical uses of tamoxifen. *Pharmacol Ther* 1984; 25: 127-130.
40. Taguchi O, Cunha GR, Robboy SJ. Experimental study of the effect of diethylstilbestrol on the development of the human female reproductive tract. *Biol Res Pregnancy Perinatol* 1983; 4: 56-58.
41. Clark JH, McCormack SA, Kling R. Effect of clomiphene and other triphenylethylene derivatives on the reproductive tract in the rat and baboon. *Hormones and Cancer*. New York: Raven Press; 1980. p. 295.
42. Taguchi O, Nishizuka Y. Reproductive tract abnormalities in female mice treated neonatally with tamoxifen. *Am J Obstet Gynecol* 1985; 151: 675-677.
43. Simard J, Luthy I, Guay J. Characteristic of interaction of the antiandrogen flutamide with the androgen receptor in various target tissues. *Mol Cell Endocrinol* 1986; 44: 261-270.
44. Lerner LJ. Hormone antagonists, inhibitors of specific activities of estrogen and androgen. *Recent Prog Horm Res* 1964; 20: 435-490.
45. Lerner LJ, Hilf R. Effects of Hormone antagonists on morphological and biochemical changes induced by hormonal steroids in the immature rat uterus. *Recent Prog Horm Res* 1964; 20: 435-490.
46. Gonzalez M, Diddi B, Komisaruk CB. Differential effects of testosterone and dihydrotestosterone on the diverse uterine tissues of the ovariectomized rat. *Endocrinology* 1972; 20: 1129-1132.
47. Lyon MF, Glenister PH. Evidence from tfm/o that androgen is inessential for reproduction in female mice. *Nature* 1974; 247: 366-367.

48. Guerami A, Griffin JE, Kovacs WJ. Estrogen and androgen production rates in the two brothers with Reinfenstein syndrome. *J Clin Endocrinol Metab* 1990; 71: 247-251.
49. Beri R, Kumar N. Estrogenic and progestational activity of 7-methyl-19 nortestosterone a synthetic androgen. *J Steroid Biochem Mol Biol* 1998; 67: 275-283.
50. Fekete G. Chemistry pharmacology and clinical pharmacology of oral contraceptives. *Ther Hung* 1968; 16: 1-8.
51. Saruhan BG, Nergiz Y. Histological Effect of Estrogens and Anti-estrogens on uterine epithelium in estrogen deficiency induced rats. *Journal of Dicle Medicine* 2002; 29: 1-2.
52. Saruhan BG, Nergiz Y. Histological Effect of Estrogens and Anti-estrogens on vaginal epithelium in estrogen deficiency induced rats. *The Chamber of Medicine of Istanbul, Journal of Clinical Development* 2003; 16: 1-5.
53. Park SM, Park CH, Wha JD. A high carbohydrate diet induces insulin resistance through decreased glucose utilization in ovariectomized rats. *Korean J Intern Med* 2004; 19: 87-92.
54. Blaustein JD, Gentry RT, Roy EJ. Effects of ovariectomy and estradiol on body weight and food intake in gold thioglucose treated mice. *Physiol Behav* 1976; 17: 1027-1030.
55. Mei LL, Xia X, Wei QR. Influence of ovariectomy and 17-estradiol treatment on insulin sensitivity, lipid metabolism and post ischemic cardiac function. *Int J Cardiol* 2004; 97: 485-493.
56. Saglam K, Polat Z, Yilmaz IM. Effects of postmenopausal hormone replacement therapy on insulin resistance. *Endocrine* 2002; 18: 211-214.