

# A rare presentation of hydatid cyst

Nuran Sabir, MD, Basak Yildirim, MD, Banu Cetin, MD, Mustafa Sengul, PhD, Erkan Alatas, MD.

---

## ABSTRACT

Hydatid disease, although known to occur in most body areas, is extremely rare in the female reproductive system. There are different modes of presentation for the disease; however, we report and discuss a case presented with cystic vesicles passing through the vagina, which is considered as a rare presentation for secondary involvement of the uterus and both ovaries. We confirmed diagnosis with radiological examinations and serological tests. We operated on the patient, and studied the excised cysts microscopically. The gynecologist should be aware of hydatid cyst when vaginally passing a grape like vesicle is presented by the patient.

Saudi Med J 2005; Vol. 26 (12): 1986-1988

---

**E**chinococcosis caused by *Echinococcus species*, which is carried by canines such as dogs and wolves. The disease may result from the development of expanding parasite cysts in visceral organs. Hydatid disease is prevalent worldwide, including Middle East, India, Africa, South America, New Zealand, Australia, Turkey, and Southern Europe.<sup>1,2</sup> The hydatid cysts of *Echinococcus granulosus* (*E. granulosus*) in humans most commonly occur in the liver (55-70%) followed by the lungs (18-35%), and other uncommon locations such as brain, bone, muscles, adrenals and spleen accounting for approximately 10% of the cases.<sup>1,3,4</sup> Symptoms are often absent and in many cases detected incidentally by imaging studies. Hydatid cysts present with many different clinical signs and these symptoms are usually due to mass effect of the enlarging cysts. In the liver, enlarging cysts may produce abdominal pain and swelling or may obstruct the biliary system, leading to jaundice. Suppuration is among the other complications and is caused by bacterial infections. The formation of the purulent material results with parasite death and conversion into a pyogenic abscess.<sup>1</sup> Lung cysts can cause partial bronchial obstruction, with recurrent pulmonary infections.

Cyst leakage or rupture may sometimes associate with severe allergic reactions to parasite antigens or patients may have anaphylactoid reactions. Vomiting with the passage of hydatid membranes and passage of membranes in stool may also occur.<sup>4</sup> Echinococcal cysts may also involve the cervix, which can be the primary or the secondary sites of infection.<sup>5</sup> Pelvic localization is rare, even in an endemic country.<sup>6,7</sup> The pathogenesis of this involvement may give rise to many different clinical signs. We report a case presenting with passage of white-colored cystic vesicles through the vagina due to secondary involvement of the ovaries and the uterus with hydatid disease, which was an extremely rare clinical presentation.

**Case Report.** A 17-year-old woman was admitted to the hospital with a complaint of generalized weakness, weight loss, a dull pain at the lower abdomen for the previous 3 weeks and passage of white-colored cystic vesicles through the vagina (**Figure 1**). Previous medical history was unremarkable, however, the physical examination revealed a pale and cachectic female patient with numerous non tender, firm masses palpated on the

---

From the Department of Radiology (Sabir), Obstetrics and Gynecology (Yildirim, Alatas), Microbiology (Sengul), Pamukkale University, Denizli, and Infection Diseases (Cetin), Celal Bayar University, Manisa, Turkey.

Received 19th March 2005. Accepted for publication in final form 18th July 2005.

Address correspondence and reprint request to: Dr. Nuran Sabir, Yenisehir, Ferah Evler Sitesi, Blok B, Sok. 17, No. 17, Denizli, Turkey. Tel. +90 (258) 2118585. Fax. +90 (258) 2423443. E-mail: nuransabir@hotmail.com

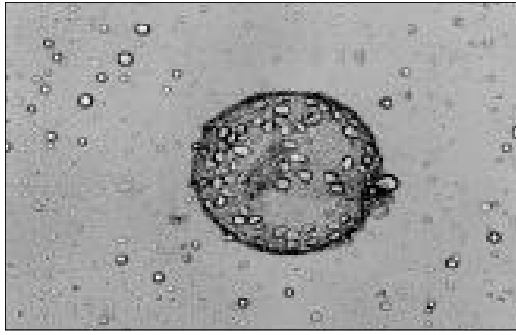


Figure 1 - Grape-like hydatid cystic vesicles passed through the vagina.

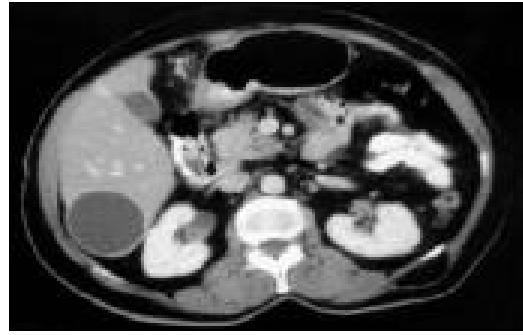


Figure 4 - Abdominal CT shows a cyst in the right lobe of the liver.

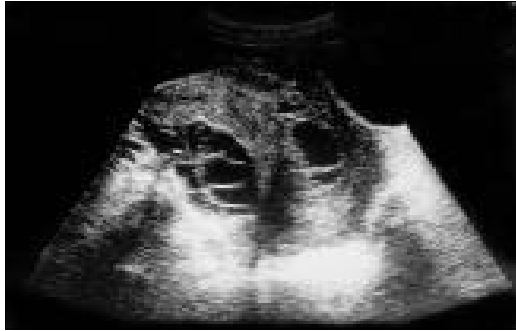

Figure 2 - Pelvic ultrasound displays multiple cysts at both adnexae and uterus.

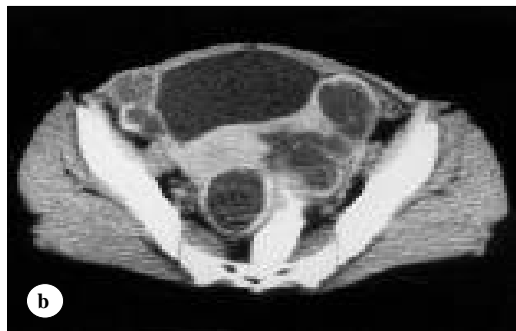
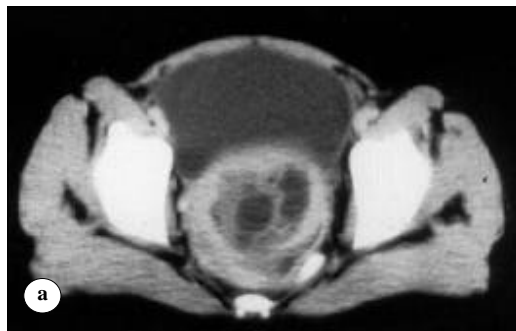
Figure 3 - Pelvic CT reveals, (a) multiple cystic lesions in the uterus and (b) bilateral multiple adnexial cysts.

right hypochondrium, right iliac fossa, and suprapubic area. She had a palpable liver approximately 3 cm below the costal margin. On rectal examination, uterus was big, irregularly shaped and cystic masses of approximately 3-4 cm in size were palpated bilaterally. As the patient was a virgin; we carried out pelvic examination only by inspection and there were multiple milky colored grape like vesicles passing through the vagina. Direct microscopic examination of these vesicles revealed scolexes of hydatid cyst. Vital signs and blood pressure were normal. White blood count and liver enzymes were normal, we found erythrocyte sedimentation rate to be 83 mm in the first hour and indirect hemagglutination test was 1/125. Abdominal ultrasonography revealed well defined, multiple, of variable sizes, thin walled multilocular cystic lesions in the right lobe of the liver, and between segments of the colon. Pelvic ultrasonography displayed large septate cystic lesions at both adnexae and in the uterine cavity (**Figure 2**). Computed tomography was also helpful in demonstrating the lesions in the liver, abdominal and pelvic cavities. In the uterus there were multilocular, thin walled cystic lesions with several septations but no calcification seen in the cyst wall (**Figures 3 & 4**). Cerebral CT showed no pathological findings. She was given albendazole as a medical therapy and then surgical management was planned. In surgery; we totally removed all the cysts in the liver and peritoneum. To preserve fertility, we performed a myomectomy like operation for the hydatid cysts in the uterus and applied wedge resection for the removal of hydatid cysts in the ovaries. Pathological examination was consistent with the hydatid cyst. We gave per oral albendazole (Zentel, Fako, Turkey) 400 mg/d divided in 2 equal doses to her for 6 months in order to prevent any recurrence of the disease. A follow-up abdomino-pelvic CT was taken one year after the laparotomy and showed no evidence of recurrent pelvic or abdominal cyst; patient's ovulation cycle continued regularly.

**DISCUSSION.** Hydatid disease is a parasitic infestation, which is endemic in many parts of the world.<sup>1,2</sup> Humans may be infected either by direct contact with the definitive host, or by ingestion of food or fluids contaminated with ova of *E. granulosus* from canine feces.<sup>2</sup> The liver is affected in 50-75%, the lungs in 15% and rest of the body in 10% of the cases. Peritoneal hydatid disease is usually secondary to hepatic disease and can result from the micro rupture or leakage of the fluid of an echinococcal cyst during trauma or surgery, however, we described some unusual cases of primary peritoneal hydatidosis. Peritoneal involvement is usually undetected unless cysts are large enough to cause symptoms. It may grow and occupy the entire peritoneal cavity, simulating a multilobulated mass. In our case, we detected hydatid cysts in the liver by ultrasonography, and we supposed that cysts in the uterus and adnexa were secondary to liver hydatid disease. The most important factor in the diagnosis of pelvic hydatid disease is an awareness of its possibility. We reported secondary involvement of uterus and both ovaries with hydatid disease as an unusual localization for the disease.<sup>6,7</sup> Similar to our case, most of the echinococcal infestations of the ovaries occur bilaterally, mimicking multicystic lesions.<sup>6,8</sup> Our patient was a young virgin girl with generalized malaise; abdominal pain and passage of the white-colored cystic vesicles through the vagina. Although, previous studies reported the different modes of clinical presentation such as abdominal pain, swelling, and septicemia, in our study, we presented our patient with vaginal passage of grape-like vesicle, and which we considered as an unusual presentation of hydatid disease. We believed this presentation to be due to the vaginally passage of cystic contents and membrane of the cyst due to rupture of the hydatid cyst into the endometrial cavity of the uterus.

We usually reach the diagnosis of hydatid disease on the basis of imaging studies such as ultrasonography, CT, and MRI. All the mentioned imaging examinations have to be confirmed by specific serological tests. Although, serological tests are 80-100% sensitive, and 88-96% specific for liver hydatid disease, it is less sensitive for lung and other organ involvement. For this, ultrasonography should be the first line of screening for abdominal and pelvic hydatidosis.<sup>1</sup> The sonographic analysis of the morphology and structure of the cyst identified in 5 categories, which are thought to correspond to evolutionary stage of the hydatid cysts are; type I: pure fluid collection, type II: fluid collection with split wall, type III: fluid collection with septa, type

IV: heterogeneous echo patterns, and type V: reflecting thick walls.<sup>9</sup> In our case, we determined the cysts as type III according to Gharbi's classification (**Figure 2**). The CT scan best demonstrates the cyst wall calcification, septa and cyst infection. More over, wider field of view and better delineation of the extent of the disease makes CT imaging modality of choice in peritoneal hydatid disease. On CT, cyst fluid usually demonstrates an attenuation of 3-30 hydroxyurea.

To preserve the fertility of the patient; we carried out suturing of the uterus using a myomectomy like procedure after excising all the cysts from uterus. Cystectomy was not convenient due to the multiple nature of the cysts in the ovaries, and so we decided to carry out wedge resection. The medical therapy is important to be given at pre and post operative period to decrease the chance of anaphylaxis, decrease the tension in the cyst wall, and to reduce the recurrence rate postoperatively.

In conclusion, we should remember hydatid cyst in the differential diagnosis of multicystic lesions localized in different abdominal or pelvic organs, especially in the endemic areas. In addition, due to different modes of presentation, a gynecologist should aware of the possibility of hydatid disease when dealing with a patient passing vaginal cystic vesicles.

## References

1. King CH. Cestodes (Tapeworms). In: Mandell GL, Bennett JE, Dolin R, editors. Principles and Practice of Infectious Diseases. New York (NY): Churchill Livingstone Inc; 2000. p. 2956-2965.
2. Bannister B, Begg N, Gillespie S, editors. Infectious disease. 2nd ed. Oxford: Blackwell Science; 2000. p. 5-6.
3. Gossios KJ, Kontoyiannis DS, Dascalogiannaki M, Gourtsoyiannis NC. Uncommon locations of hydatid disease: CT appearances. *Eur Radiol* 1997; 7: 1303-1308.
4. Karavias DD, Vagianos CE, Kakkos SK, Panagopoulos CM, Androulakis JA. Peritoneal echinococcosis. *World J Surg* 1996; 20: 337-340.
5. Dede S, Dede H, Caliskan E, Demir B. Recurrent pelvic hydatid cyst obstructing labor, with a concomitant hepatic primary. A case report. *J Reprod Med* 2002; 47: 164-166.
6. Adewunmi OA, Basilingappa HM. Primary ovarian hydatid disease in the Kingdom of Saudi Arabia. *Saudi Med J* 2004; 25: 1697-1700.
7. Terek MC, Ayan C, Ulukus M, Zekioglu O, Ozkinay E, Erhan Y. Primary pelvic hydatid cyst. *Arch Gynecol Obstet* 2000; 264: 93-96.
8. Tampakoudis P, Assimakopoulos E, Zafrakas M, Tzevelekis P, Kostopoulou E, Bontis J. Pelvic echinococcus mimicking multicystic ovary. *Ultrasound Obstet Gynecol* 2003; 22: 196-198.
9. Gharbi AH, Hassine W, Brauner WM, Dupuch K. I. Ultrasound examination of the hydatid liver. *Radiology* 1981; 159: 459-463.