

## Vesicovaginal fistula in Sudanese women

Mohammed El-Iman, MD,  
El-Hassan M. El-Hassan, MD, Ishag Adam, MD.

Vesicovaginal fistulas are among the most distressing complications of obstetric and gynecologic procedures, they can result from obstetric trauma (obstructed labor), surgery, infections, congenital anomalies, malignancy and radiation.<sup>1</sup> As each fistula is unique, there are many controversies regarding the proper surgical repair of vesicovaginal fistulas where surgeon has to see the best time and procedure to suit the specific problem. Regardless of whether a transvaginal or transabdominal approach was selected, the concepts of using healthy tissue in tension-free closure and reinforcing the closures in high risk situations will ensure success.<sup>2</sup>

This study was conducted to investigate the causes, presentations and to compare the outcomes of the vaginal versus abdominal repair. We performed a prospective and descriptive study during the period January 2001 to December 2002 at Wad Medani Teaching Hospital, Sudan. Sudanese women presented with vesicovaginal fistulas were approached to participate in the study. The details of socio-demographic characters, full clinical, obstetrical and gynecological histories were recorded. All patients were examined clinically where the fistulas were inspected directly using speculum vaginal examination and cystoscopy to visualize the ureteric orifices. In some patients the diagnosis was confirmed by filling the bladder with diluted solution of methylene blue. The aim of the study was to repair small (<0.5cm), single, simple (non-recurrent) and low fistulas (according to ureteric orifices) via transvaginal approach. Different vaginal repair techniques were used according to the case itself, however, these were generally the modifications of the Latzko procedure or a layer closure with or without Martius flap.<sup>3,4</sup> For those repairs involving large, recurrent, non-pelvic organs and high fistulas the transabdominal approach was used with a suitable flap.<sup>5</sup> We recommended a period of 8 weeks from the onset of fistulas before repair and 2 gm of intravenous ceftriaxone was used as prophylactic antibiotic. Urethral catheters were left in place for 2 weeks following the operations. All patients were followed for at least 3 months. Successful repair was defined as complete dryness for one month following removal of the catheter. Fifty Sudanese women with vesicovaginal fistulas were presented to our center during the 2-years period of the study. Obstructed

Table 1 - Comparison of different variables of patients with vesicovaginal fistulas on patients where vaginal or abdominal repair was performed.

Variable	Vaginal repair (N=20)	Abdominal repair (N=30)
Age, years	27.4 ± 4.8	31.8 ± 7.3
Weight, kg	53.7 ± 8.3	58.9 ± 12.3
Parity	1.8 ± 1.3	2.4 ± 1.8
Stay in the hospital, days	10 ± 3	13 ± 4
Urine retention (%)	0	1 (3.3)
Postoperative leakage (%)	1 (5)	1 (3.3)
Urine incontinence (%)	2 (10)	1 (3.3)
Ureteric obstruction (%)	1 (5)	0
Dyspareunia (%)	2 (10)	3 (10)
Failure rate (%)	4 (20)	1 (3.3)
*Data were shown as mean ± SD.		

labor (28%), forceps delivery (14%), Lower segment cesarean sections (16%), hysterectomy (24%), other gynecological operations (12%) and radiation (6%) were the causative factors encountered.

Twenty patients fulfilled our criteria for transvaginal repair, while the rest (30 patients) were selected for abdominal approach. **Table 1** compares the patients', different variables and the rate of complications. There was no postoperative surgical infection; no patient required augmentation cystoplasty or diversion and there was no mortality.

Our patients, presentations were not different from the literature.<sup>1</sup> The women operated upon via abdominal approach, were older and have a higher parity in comparison with those who had been selected for transvaginal one (**Table 1**). The explanation for these differences might be the characters; presentations and the causes of the fistulas that were different in the 2 groups. Thus, younger women with low parity might develop simple small fistulas that had to be corrected via vaginal approach, while older and high parity patients might develop large complicated fistulas following malignancy or different gynecological operations, hence the abdominal approach was chosen. Nevertheless, the above explanation might not be true as we observe that the higher failures were those operated via the vaginal route. Yet, the

better access and tension free closure of the abdominal approach might explain the higher failure in the vaginal repair.

Received 7th March 2004. Accepted for publication in final form 20th July 2004.

From the Department of Urology (El-Imam), Department of Obstetrics and Gynecology (El-Hassan), University of Gezira, Was Medani and the Department of Obstetrics and Gynecology (Adam), New Halfa Teaching Hospital, Sudan. Address correspondence and reprint requests to Dr. Ishag Adam, PO Box 61, New Halfa, Sudan. Tel. +(249) 421822101. Fax. +(249) 421822070. E-mail: ishagadam@hotmail.com

## References

- Margolis T, Mercer LJ. Vesicovaginal fistula. *Obstet Gynecol Surv* 1994; 49: 840-847.
- Angioli R, Penalver M, Muzii L, Mendez L, et al. Guidelines of how to manage vesicovaginal fistula. *Crit Rev Oncol Hematol* 2003; 48: 295-304.
- Dupont MC, Raz S. Vaginal approach to vesicovaginal fistula repair. *Urology* 1996; 48: 7-9.
- Raz S, Bregg KG, Nitti VW, Sussman E. Transvaginal repair of vesicovaginal fistula using a peritoneal flap. *J Urol* 1993; 150: 56-59.
- Carr LK, Webster GD. Abdominal repair of vesicovaginal fistula. *Urology* 1996; 48: 10-11.

## Percutaneous nephrolithripsy in supine position in Yemen

**Tawfik Ba'adani, MD, Mohammed Alwan, MD, Ibraheem Alnono, MD, Ismail Al-Mesleimi, MSc.**

Percutaneous nephrolithripsy (PCNL) had been settled as one of different ways for treating renal stones and prone position is considered the standard position. They were afraid to considered colonic injury as a major morbidity. We think this is not related to the position in which the PCNL is performed as the colon is anteromedially located in relation to the kidney and to be injured should be in retrolateral position and this case occurred if the patient is slim and deficient of a retroperitoneal fat. Even in the supine position, the colon is displaced anteriorly away from the kidney. Also, some studies reported that retrolateral colon is 2% in the supine position and raised to 10% in the prone one.<sup>1</sup>

Percutaneous nephrolithripsy in the supine position may also encourage regional anesthesia rather than general with easier access to intubation if needed. Serious bleeding is <1% which is similar to that occurs in other position as the site of the puncture is more laterally and you can follow the needle comes from the periphery and the calyx deformed and yielding in front of it giving you the

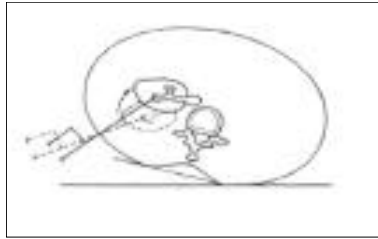


Figure 1 - Right kidney in supine position

sensation of puncturing of the calyx at or near the infundibula away from vessels.<sup>2,3</sup> Thirty-six patients with renal stones were subjected to PCNL in the supine position. Their ages were ranged between 26 and 70 years. They were comprised of 32 males and 4 females. The stones distribution was 21 on the left side and 15 in the right. The size of the stones ranged between 15 and 40 mm with an average of 25 mm. The degree of hydronephrosis was mild in 15 cases, moderate in 17 and severe in 4 cases. Localization of the pelvicalical system was through retrograde pyelography using ureteric catheter. The patient was pulled upward while a small pillow was put under the kidney to be punctured raising it up to 30 degrees horizontally (Figure 1). The table raised to the level of the surgeon chest to facilitate surgeon work in the sitting position.

The patient should be near the edge of the table to make movement of the nephroscope easier. The site of the puncture and tract creation should be in the posterior axillary line or slightly anterior. The direction of the definitive needle should be from the posterior axillary line directed anteriorly by 30 degrees horizontally aiming at puncturing the posterior calyx. Fasciotomy knife was used to cut through the tract until the dorsolumbar fascia was cut. The Amplatz dilator No. 30 over the central rod was used without the need for successive dilation using Alkans dilators and the sheath was passed over. Stone disintegration using the Swiss pneumatic lithotrite with spontaneous passage of small fragments which is facilitated by the supine position and big ones by 3 jaws forceps until the stone appears free and then nephrostomy tube No. 22 was left.

Successful operations were achieved in 32 patients (89%), while failure in 4 patients. Puncture failure in one, losing the tract in 2, while incomplete stone removal in one. The operative time was 40-120 minutes. Blood transfusion was needed in 3