

# Immunohistochemical analysis of CD71 , CD98 and CD99 activation antigens in human palatine and nasopharyngeal tonsils

Lale K. Sokmensuer, MD, Sevda Muftuoğlu, MD, PhD, Esin Asan, PhD.

---

## ABSTRACT

**Objective:** Tonsils (palatine and nasopharyngeal) are immunologically active tissues. Due to their anatomical location, they are considered to be the initial defense barrier against the antigens entering into the respiratory and gastrointestinal tract. Tonsils act against these antigens by producing and activating the lymphocytes, which are responsible for the immune response. In order to get information regarding the distribution of cell surface antigens on the epithelial, stromal and lymphoid cells of these organs, we performed immunohistochemical staining by using antibodies against CD99, CD71 and CD98 activation antigens.

**Methods:** Tissue samples of 20 patients undergoing tonsillectomy and adenoidectomy who presented with recurrent tonsillitis and adenoid hypertrophy in the Otorhinolaryngology Department, Hacettepe University Medical Faculty Hospital, Ankara, Turkey in 2001, were obtained as partial tissue samples apart from pathological examination. Tissues were immunostained by the indirect immunoperoxidase method.

**Results:** Strong CD71 reactivity in macrophages was observed as an indicator of the active role of the macrophages in immunoresponse in the chronic inflammation reaction. The CD98 reactivity on the proliferative basal layer of epithelium was a usual finding, as its detection in epithelial neoplasms and proliferative states is well known. We did not observe any reactivity of CD98 in nasopharyngeal tonsil epithelium and lymphoid cells of either nasopharyngeal or palatine tonsils. The CD99 reactivity was observed in the T-cell dependent area.

**Conclusion:** We determined some topographic difference in the expression of some activation antigens in the epithelial, stromal and lymphoid components of the palatine and nasopharyngeal tonsils. Further detailed studies directed to determine the role of these antigens in tonsils would help to understand the role of these molecules in inflammatory events.

Saudi Med J 2005; Vol. 26 (3): 385-389

---

The skin and the mucous membranes establish the relationship of organisms with the environment. The mucosa that covers the respiratory system, the gastrointestinal system and the urogenital system constitutes the first defense barrier against microorganisms. These mucosal surfaces have 2 different defense mechanisms, which originate from the immune system and the nonspecific systems, like the mucous and gastric acid. Lymphoid cells located on these mucosal

surfaces play an important role in the immune response. These cells are located on the epithelium between the epithelial cells in the lamina propria and the submucosa. These lymphoid cells form an organized structures of lymphoid follicles, which are called the mucosa associated lymphoid tissue (MALT).<sup>1,2</sup> The MALT is important in generating and maintaining the immune response. Specialized epithelial cells (M-cells) as well as activated and

---

From the Department of Histology, Faculty of Medicine, Hacettepe University, Ankara, Turkey.

Received 27th September 2004. Accepted for publication in final form 21st November 2004.

Address correspondence and reprint request to: Dr. Lale K. Sokmensuer, Hacettepe Üniversitesi, Tıp Fakültesi, Histoloji ve Embriyoloji Abd. 06100 Sıhhiye, Ankara, Turkey. Tel. +90 (312) 3051405. Fax. +90 (312) 3100580. E-mail: lalekarakoc@hotmail.com




Figure 1 - Macrophages are reactive with CD71 monoclonal antibody in connective tissue beneath the epithelium of palatine tonsil. Original magnification x20, hematoxylin counter stained.

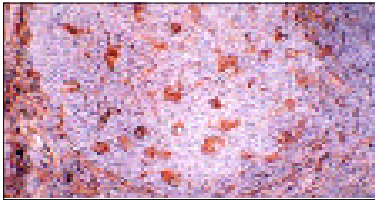


Figure 2 - Section through follicular germinal center of palatine tonsil. Macrophages are reactive with CD71. Original magnification x40, hematoxylin counter stained.




Figure 3 - Section through interfollicular area of palatine tonsil. Strong CD71 immunoreactivity was observed in endothelial cells of high endothelial venule and dendritic cells. Original magnification x40, hematoxylin counter stained.



Figure 4 - Section through surface epithelium of palatine tonsil. Membranous CD98 reactivity was observed in cells of the basal layer of surface epithelium. Original magnification x10, hematoxylin counter stained.

proliferated antigen specific B-cell lymphocytes play major roles in MALT's function.

Mucosa associated lymphoid tissue is named due to their anatomical location such as gut-associated lymphoid tissue (GALT), bronchus-associated lymphoid tissue (BALT) and the nasopharyngeal lymphoid tissue (NALT), which includes the tonsillar lymphatic tissue.<sup>2,3,4</sup>

The palatine and nasopharyngeal tonsils are organized lymphoid tissues that are located at the deeper part of the oral cavity.<sup>3,8</sup> Due to their anatomical location, they are considered as first defense barrier against the antigens entering into the respiratory and gastrointestinal tract. The tonsils act against these antigens by forming and activating lymphocytes, which are responsible of immune response. They contain all types of cells, which are necessary for induction and expression of humoral and cell-mediated immune response.<sup>9</sup> These tissues are considered as secondary lymphoid tissues due to their functional property.<sup>3</sup> Tonsils also belongs to Waldeyers lymphatic ring that constitutes an important part of the immune defense system of the body.<sup>4,6,10-12</sup>

In this study, we aimed to get information on the distribution of the cell surface antigens on the

epithelial, stromal and lymphoid cells of these organs, we performed immunohistochemical staining by using antibodies against the CD99, CD71 and CD98 activation antigens.

**Methods.** Tissue samples were obtained from 20 patients (age between 3-14) that have undergone tonsillectomy and adenoidectomy due to recurrent tonsillitis and adenoid hypertrophy in the Otorhinolaryngology Department, Hacettepe University Medical Faculty Hospital, Ankara, Turkey in 2001. All tissues were frozen in liquid nitrogen (-196°C) within 20 minutes and kept at -30°C until sectioned. Then 7 µm thick cryostat sections were taken onto gelatin-coated slides and kept in humidity free boxes at room temperature until immunostaining procedure (1-4 days).

**Antibodies and staining procedures.** Primary monoclonal antibodies, CD71 (B-D12, Wijdnes, m-G1), CD98 (J-120, Pesando, m-G1) and CD99 (3B2/TA8, Knapp, m-G1), used in these study were obtained from Vllth Leukocyte Typing Workshop (1996, Kobe) and Vllth Leukocyte Typing Workshop (2000, Harrogate). The immunostaining procedure used in our study has been described in




Figure 5 - Membranous CD98 reactivity was observed in cells of the basal layer of the surface epithelium of palatine tonsil with higher magnification. Original magnification x40, hematoxylin counter stained.

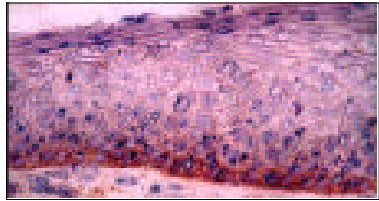


Figure 7 - Cytoplasmic CD99 reactivity was observed in basal columnar cells of the palatine tonsil surface epithelium. Original magnification x40, hematoxylin counter stained.




Figure 6 - The CD99 reactivity is observed in intraepithelial lymphocytes and basal columnar cells of surface epithelium of palatine tonsils. Original magnification x10, hematoxylin counter stained.

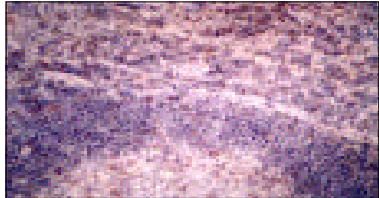


Figure 8 - In the follicular lymphoid tissue of the palatine tonsils, only a few lymphocytes in the corona are reactive with CD99. The CD99 positive lymphocytes was located at the outer part of the corona. In addition, strong CD99 reactivity was observed on the lymphocytes at the interfollicular area. Original magnification x40, hematoxylin counter stained.

detail by Dijkstra et al.<sup>13</sup> Sections were fixed in acetone for 10 minutes and air dried for 30 minutes. Then sections were incubated with primary monoclonal antibodies for one hour. After washing in 0.01 M phosphate buffered saline (PBS) (pH 7.4), the slides were covered with a 1:200 dilution of rabbit anti-mouse immunoglobulin G peroxidase (Sigma Cat no: B9904) in PBS containing 0.2% bovine serum albumin (Sigma Cat no: A7034) and 1% normal human serum for 30 minute. Then after washing in PBS the slides were stained for peroxidase activity with 3,3'-diaminobenzidine-tetrahydrochloride (Sigma Cat no: D-5637) (0.5 mg/ml Tris-HCl buffer, pH 7.6, containing 0.01% H<sub>2</sub>O<sub>2</sub>). Counterstaining with hematoxylin was carried out. The control staining was performed by omitting the primary antibody step and using the irrelevant monoclonal antibody (mAb). Stained sections were examined and photographed using an Olympus BH2 light microscope.

**Results: *The CD71 reactivity.*** In palatine tonsil, weak CD71 reactivity was observed in a few cells in surface epithelium. Basal layer of stratified squamous epithelium was reactive with CD71. Interestingly, in one of the cases, which had chronic clinical infection, in reticular epithelium that covers the crypt, dendritic cells were strongly reactive for CD71. In connective tissue beneath the epithelium and capsule, macrophages were found to be reactive with CD71 (Figure 1). The CD71 antigen was expressed on dendritic cells and macrophages of interfollicular area. In follicular germinal centers, macrophages were reactive with CD71 (Figure 2). In addition, strong immunoreactivity with CD71 was observed in endothelial cells of high endothelial venule (HEV) in interfollicular area (Figure 3). In nasopharyngeal tonsil, similar to palatine tonsil, weak CD71 reactivity was observed in a few cells in epithelium. In connective tissue beneath epithelium, macrophages were strongly reactive with CD71. In germinal centers of lymphoid follicle, macrophages

and some of the dendritic cells were found to be reactive for CD71. Both macrophages and endothelial cells of HEV are stained strongly with CD71 in interfollicular area.

**The CD98 reactivity.** In palatine tonsil, membranous reactivity with CD98 was observed on the basal layer of surface epithelium (Figures 4 & 5). Similar membranous reactivity was observed on the basal layer of crypt epithelium. There was no immunoreactivity in the lymphoid follicle, interfollicular area, lamina propria and capsule of the palatine tonsil with CD98. Interestingly, in nasopharyngeal tonsil, CD98 had no immunoreactivity in the epithelium. In addition, there was no immunoreactivity with this antibody, on the other component of this tissue.

**The CD99 reactivity.** In palatine tonsil, CD99 mAb was found to have been reactive with intraepithelial lymphocytes in surface and crypt epithelium. In addition, cytoplasmic CD99 reactivity was observed on basal columnar cells of the stratified squamous cells of epithelium (Figures 6 & 7). In the connective tissue beneath the epithelium, lymphocytes and fibroblast like cells were reactive with CD99 monoclonal antibody. While the reactivity for CD99 antigen was determined in a few lymphocytes and fusiform like cells in the septula of the capsule.

In the follicular lymphoid tissue of the palatine tonsils, only a few lymphocytes in the corona were reactive with CD99. The CD99 positive lymphocytes were located at the outer part of the corona. While strong CD99 reactivity was observed on lymphocytes at the interfollicular area (Figure 8). In nasopharyngeal tonsil, CD99 mAb was found to be reactive with intraepithelial lymphocytes in the epithelium, like the palatine tonsil. The cytoplasmic CD99 reactivity was detected on the basal cells of the epithelium. The CD99 positive lymphocytes were observed in the capsule, septula and lamina propria of the nasopharyngeal tonsils. As in the palatine tonsil, in the germinal centers of the nasopharyngeal tonsil, CD99 positive lymphocytes were observed at the outer part of the corona. However, in the interfollicular region, strong CD99 reactivity was observed on the lymphocytes.

**Discussion.** The lymphocyte development occurs in primary lymphoid organs (bone marrow and thymus), which are major lymphoid organs. Lymphocytes that differentiate from precursor cells in primary lymphoid cells proliferate and then mature into immunocompetent cells. While T-cells mature in thymus, B-cells mature in fetal liver and bone marrow in mammals. However, secondary lymphoid organs such as tonsils, spleen and lymph nodes, are structures, which provide relationship between the lymphocytes, other cells and antigens. These secondary lymphoid organs play an important

role in the defense system of the body by forming immune response. Mature T-cells, B-cells and antigen presenting cells are necessary for this immune response, which is provided by secondary immune organs.<sup>10</sup>

Tonsils (palatine and nasopharyngeal) are secondary lymphoid organs, which belongs to MALT. They are considered as first defense barrier against the antigens passing to the respiratory and gastrointestinal tract due to their strategical location. They act against these antigens by forming and activating the lymphocytes, which are responsible of immune response.

In the present study, in order to get information regarding the distribution of the cell surface antigens on the epithelial, stromal and lymphoid cells of palatine and nasopharyngeal tonsils, we performed immunohistochemical staining using antibodies against the activation antigens (CD71, CD98, CD99). The CD71 is a late activation antigen, which also called transferring receptor. These antigen are usually found with high level at the cells, which has high proliferation activity.<sup>14,15</sup> In our study, there were no immunoreactivity with CD71 in lymphoid cells of the palatine and nasopharyngeal tonsil, which frequently meet antigens as secondary lymphoid organs. However, macrophage in connective tissue beneath the epithelium, capsule and septula showed strong CD71 immunoreactivity. In addition, strong immunoreactivity of CD71 in HEV of interfollicular area supports that CD71 has a role in cell activation. The CD71 reactivity in high proliferative capacity cells in the basal layer of the surface epithelium, is an expected finding. In addition, detection of CD71 reactivity, especially in the dendritic cells in the reticular epithelium and the interfollicular area are interestingly found and there is no similar finding in the literature before. The CD98 molecule plays an important role in the regulation of cell activation. Its expression increases in leukocytes in inflammatory lesions. Also, it shows strong expression in neoplastic cells.<sup>16</sup>

In this study, CD98 reactivity was strongly seen only in the basal layer of the surface and crypt epithelium of the palatine tonsils. This reactivity in basal layer of proliferative epithelium is an expected finding, as CD98 is known as an activation molecule. However, no immune reactivity was seen in the nasopharyngeal tonsil epithelium. We consider that this molecule might have different functional importance and further studies will help us to understand its role in tonsils. There is no similar finding in literature with this molecule in tonsils. The CD99 is known as a T-cell adhesion molecule.<sup>17</sup> This molecule is primarily expressed as an early indicator of T-cell activator.<sup>18</sup> It is highly expressed especially in CD8 positive cytotoxic cells.<sup>19</sup> In these cells, it has been showed that there are some regulatory function of this molecule in

relationship to the TCR/CD3 and other cells. In our study, we showed that, CD99 immunoreactivity is found in lymphocytes at T-cell dependent region. Aside from this, we determined that intraepithelial lymphocytes, which is considered as CD8 positive cytotoxic cells, showed high CD99 reactivity. These findings give us information on the T lymphocytes function in the tonsils. There are some studies related to CD99 expression in T-cells in the reactive lymph nodes, but there is no information regarding the palatine and nasopharyngeal tonsils.<sup>20</sup>

In our study, we detected more CD99 positive lymphocytes in the corona than in the germinal centers. This finding supports the studies, which showed the CD99 deficiency in the B lymphocytes.<sup>19,21</sup> There are a lot of studies related to CD99 expression in thymus T lymphocytes, whereas there is not enough studies in the palatine and nasopharyngeal tonsils. We consider that further detailed studies are needed for the understanding of the functional role of activation antigens in the palatine and nasopharyngeal tonsils.

## References

- Kempen MJP, Rijkers GT, Cauwenberge PBV. The immune response in adenoids and tonsils. *Int Arch Allergy Immunol* 2000; 122: 8-19.
- Gebert A. The role of M cells in the protection of mucosal membranes. *Histochem Cell Biol* 1997; 108: 455-470.
- Surjan I. Jr. Tonsils and lympho-epithelial structures in the pharynx as immuno-barriers. *Acta Otolaryngol* 1987; 103: 369-372.
- Fujimura Y. Evidence of M cells as portals of entry for antigens in the nasopharyngeal lymphoid tissue of humans. *Virchows Arch* 2000; 436: 560-566.
- Williams PL, Warnick R, Dyson M, Bannister LH. Gray's Anatomy. 37th ed. New York (NY): Churchill Livingstone; 1989. p. 1324-1325.
- Cummings CW. Otolaryngol-Head and Neck Survey. 2nd ed. Baltimore (MD): Mosby; 1992. p. 1110-1111.
- Fawcett DW. A textbook of Histology. 12th ed. New York (NY): Chapman and Hall; 1994. p. 575-576.
- Ross MH, Romrell LJ, Kaye GI. Histology. A text and Atlas. 3rd ed. Baltimore (MD): Williams and Wilkins; 1995. p. 534.
- Quiding M, Granstrom G, Nordstrom I, Ferrua B, Holmgren J, Czerkinsky C. High frequency of spontaneous interferon-gamma-producing cell in human tonsils: role of local accessory cells and soluble factors. *Clin Exp Immunol* 1993; 91:157-163.
- Kuper CF, Koornstra PJ, Hamelers DMH, Biewenga J, Spit BJ, Duijvestijn AM, et al. The role of nasopharyngeal lymphoid tissue. *Immunol Today* 1992; 6: 219-224.
- Rubin E, Farber JL. Pathology. New York (NY): Lippincott-Raven; 1999. p. 1324.
- Roitt I, Brostoff J, Male D. Immunology. London (UK): Mosby; 1998. p. 37.
- Dijkstra CD, Dopp EA, Joling P, Kraal G. The heterogeneity of nuclear phagocytes in lymphoid organs: Distinct macrophage subpopulations in the rat recognized by monoclonal antibodies ED1,ED2,ED3. *Immunology* 1985; 54: 389-399.
- Goding JW, Duhljivic V, Sali A. Leukocyte Typing VI. New York (NY): Garland Publishing Inc; 1998. p. 524-527.
- Gruss HJ, Scheffrahn J, Hubinger G, Duyster J, Hermann F. The CD30 ligand and CD40 ligand regulate CD54 surface expression and release of its soluble form by cultured Hodgkin and Reed-Stenberg cells. *Leukemia* 1996; 10: 829.
- Diaz L. Leukocyte Typing VI. New York (NY): Garland Publishing Inc; 1998. p. 1182-1183.
- Shaw S. Leukocyte Typing VI. New York (NY): Garland Publishing Inc; 1998,1183.
- Wingett D, Forcier K, Nielson CP. A role for CD99 in T cell activation. *Cell Immunol* 1999; 193: 17-23.
- Bernard A. Leukocyte Typing VI. New York (NY): Garland Publishing Inc; 1998. p.75-77.
- Park CK, Shin YK, Kim TJ, Park SH, Ahn GH. High CD99 expression in memory T and B cells in reactive lymph nodes. *J Korean Med Sci* 1999; 14: 600-606.
- Loveland BE, Szokolai K. Leukocyte Typing VI. New York (NY): Garland Publishing Inc; 1998. p. 519-520.