

Survival of 2 extreme preterm neonates with cardiac tamponade as a complication of percutaneous central venous catheterization

Abdullah M. Alzaydi, ABP, SBP, Ali Y. Mersal, MBBS, FRCP (C),
Saad A. Al-Saedi, MD, FRCP (C), Walid A. El-Naggar, ABP, SBP.

ABSTRACT

We report 2 extreme preterm neonates who developed cardiac tamponade secondary to perforation of the myocardium by the percutaneous silastic central venous catheters, which were inserted for parental nutrition. Percutaneous pericardiocentesis was performed and pericardial effusion was aspirated, later proved by analysis to be total parental nutrition. The lines were removed and the patients successfully resuscitated and survived, both were sent home in good condition.

Saudi Med J 2005; Vol. 26 (3): 476-477

Percutaneous silastic central venous catheters (PCVC) are commonly used in preterm neonates to deliver total parental nutrition (TPN), medications, and fluids.^{1,2} Unfortunately, their use is often associated with complications including infections, local phlebitis, local thrombosis at the catheter tip, deposition of calcium crystals and rarely pericardial tamponade as a result of migration of the catheter tip.¹ We report 2 cases of extreme preterm neonates who survived cardiac tamponade as a complication of percutaneous central venous catheter migration.

Case Reports. Patient one. A 28 week-extreme preterm baby product of quintuplet pregnancy, with a birth weight of 1125 gm. On the twelfth day of age, a PCVC was inserted for TPN and infusion of medications. Although the baby had a stormy course with sepsis and meningitis. Percutaneous silastic central venous catheters infection was never proven. Forty-two days after

PCVC insertion, the baby developed sudden cardiopulmonary arrest. During resuscitation the line was not flushing. Chest x-ray showed cardiomegaly (Figure 1) and the catheter tip had migrated to the right atrium, so cardiac tamponade was suspected. This was confirmed by echocardiogram. Percutaneous pericardiocentesis was performed and 60 ml of turbid fluid was aspirated from pericardial sac. Later the fluid was confirmed to be consistent with TPN fluid. The catheter was removed, and the baby survived.

Patient 2. A 23 week-extreme preterm baby, a product of *in-vitro* fertilization, with a birth weight of 500 grams. She developed pulmonary hemorrhage at 48 hours of age. On the fourth day of life, patent ductus arteriosus was detected. She remained stable with no evidence of sepsis or intraventricular hemorrhage. A percutaneous long line (PCVC) was inserted in the left arm on the fourth day of life and its position was checked by x-ray. On the tenth day of life, she developed

From the Department of Pediatrics, Division of Neonatology, King Faisal Specialist Hospital and Research Centre, Jeddah, Kingdom of Saudi Arabia.

Received 17th July 2004. Accepted for publication in final form 30th November 2004.

Address correspondence and reprint request to: Dr. Ali Y. Mersal, King Faisal Specialist Hospital and Research Centre, PO Box 40047, MBC: J-58, Jeddah 21499, Kingdom of Saudi Arabia. Tel. +966 (2) 6677777 Ext. 1592. Fax. +966 (2) 6677777 Ext: 3508. E-mail: alimersal@dr.com

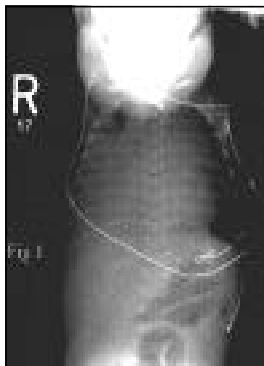


Figure 1 - Chest x-ray of patient one showing massive cardiomegaly secondary to pericardial effusion.

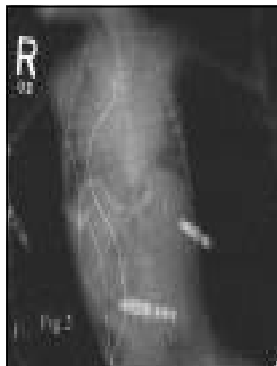

Figure 2 - Chest x-ray of patient 2 showing an enlarged cardiac shadow.

generalized edema, hypotension, metabolic acidosis and increased ventilatory requirements. The heart sounds were barely audible and the chest x-ray showed an enlarged cardiac shadow (**Figure 2**). Pericardial effusion was suspected and was confirmed by echocardiography. Percutaneous pericardiocentesis was performed and 18 ml of turbid fluid was aspirated; later proven by amino acid analysis to be TPN. The line was removed and the patient survived.

Discussion. The exact mechanism of pericardial effusion with PCVC use remains somewhat speculative.³ Catheters placed initially in the superior vena cava can, with respiration, heart beat, and movement of the infant's head, arms, or trunk migrate further into the right atrium (RA) and right ventricle (RV) and lodge against or perforate the atrial or ventricular wall.³ When no perforation is visualized, it is then hypothesized that pericardial effusions may be the result of the hypertonic TPN solution causing tissue damage at the site where the catheter tip is lodged against the RA or RV wall.³ The cause of pericardial effusion and tamponade in our cases was myocardial perforation by the tip of the migrating silastic catheter. The fact that the effusion fluid in the pericardial sac was found to be consistent with TPN, confirms the perforation of the myocardium by PCVC rather than pericardial effusion. A previous report suggests a 3% incidence for PCVC associated symptomatic perforation complications and a 1% incidence for fatal perforation.²⁴ This occurs in spite of a policy of a careful placement. Both patients survived, due to

early recognition of the perforation and evacuation intervention contributed to their survival.

In conclusion, cardiac tamponade is a serious life-threatening complication of percutaneous central venous catheterization.^{3,6} We recommend regular checking of the site of the catheter tip with x-ray immediately after insertion and thereafter. This would help in early detection of migration of the catheter tip. Also, the catheter tip should not be placed in the right atrium to avoid risk of tamponade. Any unexplained sudden onset of shocklike symptoms, non-attributable to usual causes in neonates with a PCVC should raise the suspicion of migration of the PCVC tip causing pericardial effusion and pericardial tamponade.

References

1. Kabra NS, Kluckow MR. Survival after an acute pericardial tamponade as a result of percutaneous ly inserted central venous catheter in a preterm neonate. *Indian J Pediatr* 2001; 68: 677-680.
2. Beardsall K, White DK, Pinto EM, Kelsall AW. Pericardial effusion and cardiac tamponade as complications of neonatal long lines: are they really a problem? *Arch Dis Child Fetal Neonatal Ed* 2003; 88: F292-F295.
3. Fioravanti J, Butzard CJ, Harris JP. Pericardial effusion and tamponade as a result of percutaneous silastic catheter use. *Neonatal New* 1998;17: 39-42.
4. Leipala JA, Petaja J, Fellman V. Perforation complications of percutaneous central venous catheters in very low birthweight infants. *J Paediatr Child Health* 2001; 37: 168-171.
5. Nadroo AM, Lin J, Green RS, Magid MS, Hoizman IR. Death as a complication of peripherally inserted central catheters in neonates. *J Pediatr* 2001; 3: 599-601.
6. Darling JC, Newell SJ, Mohamdee O, Uzun O, Cullinane CJ, Dear PR. *J Perinatal* 2001; 7: A61-A64.