

# Laparoscopic appendectomy

*Abdulrahman A. Al-Bassam, FRCS(Ed).*

## ABSTRACT

**Objectives:** Laparoscopic appendectomy (LA) is a minimally invasive time saving rapidly becoming an alternative to open appendectomy (OA) for the treatment of appendicitis. We examined the efficacy, safety and complications of performing LA in children.

**Methods:** This is a critical review of the literature. We analyzed 113 children who underwent LA between January 1999 and May 2004 at King Khalid University Hospital, Riyadh, Saudi Arabia. Demographic data, severity of appendicitis, histopathological findings, hospital stay, analgesia and complications were analyzed.

**Results:** Laparoscopic appendectomy was successful in 113 children. 85 had uncomplicated appendicitis, 28 had complicated appendicitis. In children with complicated appendicitis, open appendectomy had to be carried out in 10 patients (35.7%). Their ages ranged between 2 and 16 years (average 8 years). 52 were males and 61 were females. Symptom duration average was 30 hours. In uncomplicated appendicitis and 56 had no complications.

**Conclusion:** Laparoscopic appendectomy is a safe and effective method for managing patients with uncomplicated appendicitis. In children with complicated appendicitis, open appendectomy had to be carried out in 10 patients (35.7%). Their ages ranged between 2 and 16 years (average 8 years). 52 were males and 61 were females. Symptom duration average was 30 hours. In uncomplicated appendicitis and 56 had no complications.

**Saudi Med J 2005; Vol. 26**

**L**aparoscopic surgery is a minimally invasive surgical approach to the abdominal cavity. Several surgical specialties have adopted this approach for a variety of indications. Laparoscopic appendectomy (LA) is still a controversial technique for the treatment of appendicitis in children. Laparoscopic appendectomy is rapidly becoming an alternative to open appendectomy (OA) for the treatment of appendicitis in children. We examined the efficacy, safety and complications of LA in children. In this review, we analyzed 113 children who underwent LA between January 1999 and May 2004 at King Khalid University Hospital, Riyadh, Saudi Arabia. Demographic data, severity of appendicitis, histopathological findings, hospital stay, analgesia and complications were analyzed.

**Methods:** This is a critical review of the literature. We analyzed 113 children who underwent LA between January 1999 and May 2004 at King Khalid University Hospital, Riyadh, Saudi Arabia. Demographic data, severity of appendicitis, histopathological findings, hospital stay, analgesia and complications were analyzed.

From the Department of Surgery, King Khalid University Hospital, Riyadh, Kingdom of Saudi Arabia. Received 21st September 2004. Accepted for publication in final form 19th December 2004. Address correspondence and reprint request to: Dr. Abdulrahman Al-Bassam, Der 86572, Riyadh 11652, Kingdom of Saudi Arabia. Fax: +966 (1) 4679493. E-mail: dr.abbassam@kku.edu.sa

# Laparoscopic appendectomy in children ... Al-Bass

(5mm or 10mm, depending upon the age and weight of the patient). In 3-ports technique, a second port (3.5mm or 5mm) was inserted into the left lower quadrant just below umbilicus and used for manipulation, cauterization of mesoappendix, the Roeder-loop suture, suction and irrigation. Pre-tie Vicryl Roeder-loop sutures (Auto Sutures United Surgical Corporation, Norwalk, Connecticut, USA), 2 proximally and one distally were used to secure the base of the appendix **Figure 1**. The third port is placed suprapubically (3.5mm or 5mm) and is used to hold the tip of appendix during appendectomy. The appendix is usually removed through the infraumbilical primary port (5mm or 10mm). In the 2-ports technique (extracorporeal), the appendix is eviscerated through the second-port (5mm or 10mm) placed in the right lower quadrant directly over the cecum. The appendectomy was performed outside the abdominal cavity (**Figure 2**). All patients received intravenous antibiotics (cefuroxime and metronidazole) with induction of anesthesia and continued postoperatively depending on the findings at surgery.

**Results.** Laparoscopic appendectomy was attempted in 113 children. It was successfully completed in only 100 patients. In 13 (11.5%), conversion to open appendectomy had to be resorted to for complicated appendicitis and that was mostly early in our experience. The conversion was mostly due to technical difficulties such as malposition of the appendix, mass formation, adhesions, and perforation during manipulation. Out of 100, 85 had uncomplicated appendicitis. Their ages ranged between 2-12 years (average of 8 years). Fifty-two patients were males and 48 were females. The symptoms' duration average was 30 hours in uncomplicated appendicitis and 56 hours in complicated appendicitis. Preoperative investigations included complete blood count, plain abdominal x-ray and ultrasound of the abdomen in some patients as indicated. Operative time ranged between 35-80 minutes (average 53 min). Four patients with complicated appendicitis developed postoperative complications, 2 had wound infection and the other 2 had intraabdominal collections. Wound infection was treated with drainage and antibiotics and intraabdominal collections were managed by percutaneous aspiration under computerized tomography scan guidance with good results. No intraoperative complications were encountered. Twenty-four patients required one dose of postoperative analgesia (pethidine 1mg/kg/dose) while 10 required 2 or more doses and the rest of patients were managed with simple analgesia. The average hospital stay was 2 days for uncomplicated appendicitis and 6 days for complicated ones. A comparison of result between LA for uncomplicated appendicitis and LA

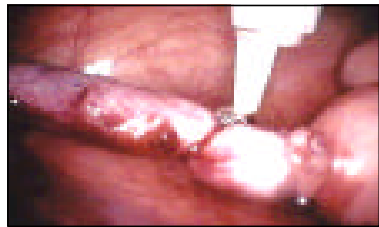

Figure 1 - Shows endoscopic view during intra corporeal laparoscopic appendectomy with the base of appendix ligated with pre-tied end loop.

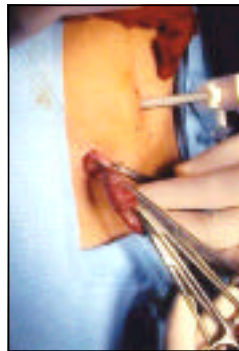


Figure 2 - Shows appendix pulled out of abdominal cavity in 2-port technique of extracorporeal laparoscopic appendectomy.

**Table 1** Comparison of outcome between complicated and uncomplicated appendicitis.

Characteristics	Uncomplicated appendicitis (N=85)	Complicated appendicitis (N=15)
Operative time (min)	53 ± 24.41	63.5 ± 17.33
Hospital stay	2.9 ± 0.98	6.6 ± 4.91
<b>Postoperative analgesia: (pethidine)</b>		
One dose only	22	3
Two or more doses	7	4
Wound infection	-	2
Intra-abdominal collections	-	2

performed for perforated appendicitis showed that LA for perforated appendicitis is associated with longer operating time and hospital stay, need for more postoperative analgesia and had a higher complication rate (Table 1). Histopathological examination revealed 75 acutely inflamed appendices, 15 were perforated appendicitis and 10 appendices were reported to be normal. All patients were followed up for 6-12 months.

**Discussion.** Appendectomy is the most common surgical emergency in children. Open appendectomy has been the standard treatment for decades with excellent results. However, owing to advances in pediatric laparoscopic instruments and increased experience with laparoscopy, many centers now routinely use LA in children.<sup>2</sup> The popularity of this procedure has increased and most laparoscopic appendectomies in children were reported.<sup>3-7</sup> Laparoscopic appendectomy has undergone considerable refinements since its introduction in 1983. Various techniques have been described including using single-port, 2-ports and 3-ports.<sup>7,9</sup> The procedure can be carried out intracorporeally or extracorporeally (appendix pulled through laparoscopic port and carried out outside the abdominal cavity).<sup>5</sup> Early in our experience, we used both approaches but now we adopted the 3-ports intracorporeal technique. Although the extracorporeal method was as effective and safe as the intracorporeal technique, we believe the latter has more advantages. The mesoappendix is dissected and divided by using either electrocautery, endoscopic clips, endoscopic stapler, or ultrasonically activated endoshear.<sup>7-10</sup> The base of appendix can be ligated with endoscopic ligating loops or clips or by endoscopic stapler.<sup>5,7,10</sup> Several retrospective and prospective studies have shown that laparoscopic appendectomy in children is safe, effective and offers many benefits compared to the open technique.<sup>3,7,11</sup> Our experience with LA in over 100 cases lends support to this conclusion especially in uncomplicated and simple appendicitis. In addition to these advantages, a thorough examination of the entire abdominal cavity is possible and this can help find other pathological conditions especially in females, in whom the rate of negative appendectomy is higher and in patients with recurrent abdominal pain.<sup>12</sup> What was not clearly documented in the literature is whether the operating time, cost and complication rate for LA can approach that for open appendectomy. As one gains experience with laparoscopic surgery, the operative time will become shorter and approach that for open technique or even shorter. This is especially so for simple appendicitis. In complicated and perforated appendicitis the operative time may be longer but with experience this can be similar to the open

technique. Our average operative time for uncomplicated appendicitis was 53 minutes and 63 minutes for perforated appendicitis. This operative time is comparable to the open technique and similar to what was reported in the literature.<sup>4,6,7</sup> It is true that laparoscopic technique is more costly than the open one. However, this potential disadvantage can be overcome by eliminating the expensive instruments and using reusable equipments.

Postoperative complications of LA have been reported to range between 1.5-4% in large series.<sup>5,7</sup> This incidence is comparable to traditional open appendectomy series.<sup>13,14</sup> Postoperative complications included wound infection, residual intraabdominal abscess, intestinal obstruction, accidental visceral injuries, port hernia and others.<sup>3,7,9,15</sup> In our study, 4 patients developed postoperative complications (4%), which were seen only in complicated (perforated) appendicitis. It has been clearly documented that LA is superior to open technique for uncomplicated appendicitis. However, it is still uncertain whether this is true for complicated appendicitis. Some investigators reported a higher rate of morbidity in complicated (perforated) appendicitis especially the infectious complications (wound infection and intra-abdominal abscess) and advised against using laparoscopy in these cases.<sup>15-17</sup> In a retrospective study of 56 children treated for complicated appendicitis, 9% of the open appendectomy group developed a postoperative intra-abdominal abscess compared with 41% ( $p=0.01$ ) of the laparoscopically treated group.<sup>16</sup> Krisher et al<sup>15</sup> reported a 24% postoperative intra-abdominal abscess in LA for perforated appendicitis and only 4.2% in open appendectomy. Steyaert et al<sup>17</sup> in a study of 1500 pediatric laparoscopic appendectomies found that 14 (5.8%) of 240 patients with peritonitis developed postoperative intra-abdominal abscess. In our study, 2 (13.3%) of 15 patients with perforated appendicitis developed postoperative intra-abdominal abscess. On the contrary, others have found no difference in term of infectious complications between laparoscopic and open groups for both simple and perforated appendicitis.<sup>7,18-20</sup> Most of the previously published studies however had the limitations of being retrospectives and the number of perforated appendicitis performed by the laparoscopic approach were relatively small. The benefits of laparoscopic surgery in complicated appendicitis will remain uncertain until we have more prospective randomized controlled trials.

In conclusion, our present study shows that LA is safe and effective method in managing children with acute uncomplicated appendicitis. In children with complicated appendicitis, (perforated/mass/abscess), LA should be carried out with caution and by

experienced surgeon as it is associated with a higher rate of conversion to open technique and has more postoperative infectious complications. Further, prospective randomized control studies are needed to show the benefits of LA for complicated appendicitis.

## References

- Valla JS, Steyaert H. Laparoscopic appendectomy in children. In: Bax NMA, Georgeson KE, Najmaldin AS, Valla JS, editors. Endoscopic surgery in children. Berlin: Springer-Verlag Publisher; 1999. p. 234-253.
- Blakely ML, Spurbuck WW, Lobe TE. Current status of laparoscopic appendectomy in children. *Semin Pediatr Surg* 1998; 7: 225-227.
- Valla JS, Limonne B, Valla V, Montupet P, Daoud N, Grinda A, et al. Laparoscopic appendectomy in children. Report of 465 cases. *Surg Laparosc Endosc* 1991; 1: 166-172.
- Richard W, Watson D, Lynch G, Reed GW, Olsen D, Spaw A, et al. A review of the result of laparoscopic versus open appendectomy. *Surg Gynecol and Obstet* 1993; 177: 473-480.
- El-Ghoneimi A, Valla JS, Limonne B, Valla V, Montoupet P, Chavrier Y, et al. Laparoscopic appendectomy in children: Report of 1379 cases. *J Pediatr Surg* 1994; 29: 786-789.
- Hay SA. Laparoscopic versus conventional appendectomy in children. *Pediatr Surg Int* 1998; 13: 21-23.
- Canty TG, Collins D, Losasso B, Lynch F, Brown C. Laparoscopic appendectomy for simple and perforated appendicitis in children: The procedure of choice? *J Pediatr Surg* 2000; 35: 1582-1585.
- Khan AR. Two port laparoscopically appendectomy in a child with use of the ultrasonically activated endo-sheer. *Pediatric Endosurgery and Innovative Techniques* 2003; 7: 193-197.
- Satomai A, Tanimizu T, Takahashi S, Kawase H, Murai H, Yonekawa H, et al. One-port laparoscopy assisted appendectomy in children with appendicitis: Experience with 100 cases. *Pediatric Endosurgery and Innovative Techniques* 2001; 5: 371-377.
- Olguner M, Akgur FM, Ucan B, Aktug T. Laparoscopic appendectomy in children performed using single endoscopic GIA stapler for both mesoappendix and base of appendix. *J Pediatr Surg* 1998; 33: 1347-1349.
- Lejus C, Delile L, Plattner V, Baron M, Guillou S, Helonry Y, et al. Randomized single blinded trial of laparoscopic versus open appendectomy in children: Effect on post-operative analgesia. *Anesthesiology* 1996; 84: 801-806.
- Stylianos S, Stein JE, Flanagan LM, Hechtman DH. Laparoscopy for diagnosis and treatment of recurrent abdominal pain in children. *J Pediatr Surg* 1996; 31: 1158-1160.
- Nelson IR, Laberge JM, Nguyen LT, Moir C, Doody D, Sonnino RE, et al. Appendicitis in children: Current therapeutic recommendations. *J Pediatr Surg* 1990; 25: 1113-1116.
- Chevalier J, Durand A. Reflexions sur une serie homogene de plas de 3200 appendectomies. *Lyon Chir* 1980; 76: 251-253.
- Krisher SL, Brown A, Dibbins A, Tracz N, Curci M. Intra-abdominal abscess after laparoscopic appendectomy for perforated appendicitis. *Arch Surg* 2001; 136: 438-441.
- Horwitz JR, Custer MD, May JR, Mehall JR, Lailly KP. Should laparoscopic appendectomy be avoided for complicated appendicitis in children? *J Pediatr Surg* 1997; 11: 1601-1603.
- Steyaert H, Hendrice C, Lereau L, Ghoneimi A, Valla J. Laparoscopic appendectomy in children: Sense or nonsense? *Acta Chir Belg* 1998; 98: 119-124.
- Tibrabassi MV, Tashjian DB, Moriarty KP, Konefal SH, Courtney Sachs BF. Perforated appendicitis: Is laparoscopy safe? *JSL* 2004; 8: 147-149.
- McKinlay R, Neeleman S, Klein R, Stevens K, Greenfield J, Ghory M, et al. Intra-abdominal abscess following open and laparoscopic appendectomy in the pediatric population. *Surg Endosc* 2003; 17: 730-733.
- Oka T, Kurkhubasche AG, Bussey JG, Wesselhoeft CW, Tracy T, Luks FL. Open and laparoscopic appendectomy is equally safe and acceptable in children. *Surg Endosc* 2003; 18: 242-245.