

# Occult hepatitis B among chronic liver disease patients

Zahra Honarkar, MD, Seyed M. Alavian, MD, Shahram Samiee, MD, PhD,  
Kayvan Saeedfar, MD, Mohammad R. Zali, MD.

---

## ABSTRACT

**Objective:** Occult hepatitis B virus (HBV) infection is characterized by presence of HBV infection with undetectable hepatitis B surface antigen (HBsAg). Diagnosis of occult HBV infection requires sensitive HBV-DNA polymerase chain reaction (PCR) assay. Occult hepatitis B is a new entity and the prevalence of it and its clinical importance has not been investigated yet in Iran. The aim of this study is to investigate the prevalence and clinical importance of occult hepatitis B among chronic liver disease patients in Iran.

**Methods:** We studied 35 consecutive paraffin-embedded liver tissues cases referred to Research Center for Gastroenterology and Liver Diseases, Tehran, Iran during the year 2001 to 2002 for liver biopsy due to its elevation of alanine aminotransferase (ALT) levels for more than 6 months. Liver biopsies were reviewed and HBV-DNA and

HBsAg and Hepatitis B core antigen were assayed in liver tissue by PCR and immunohistochemistry (IHC).

**Results:** Our patients with chronic liver disease (CLD) included hepatitis C (77.1%), cryptogenic liver disease (20%), and autoimmune hepatitis (2.9%). Histologically, chronic hepatitis, cirrhosis and non-specific changes were reported. Hepatitis B virus-DNA was detectable in 8 (22%) patients; however, IHC was negative in all.

**Conclusion:** Occult hepatitis B is relatively frequent among patients with CLD in Iran. It maybe associated with more advanced liver pathology (cirrhosis) and more aggressive clinical course (decompensated cirrhosis). Occult HBV infection causes strong suppression of viral gene expression.

Saudi Med J 2005; Vol. 26 (4): 601-606

---

Hepatitis B virus (HBV) infection is one of the major global human health problems. It is estimated that more than 350 million people world-wide and 1.25 million people in the United States are affected by HBV infection. The spectrum of HBV-related disease ranges from acute hepatitis B, asymptomatic HBV carrier, chronic hepatitis to rarely fulminant hepatitis. Chronic HBV infection is also associated with cirrhosis and hepatocellular carcinoma (HCC). Hepatitis B surface antigen (HBsAg) is often used as the serological marker to screen for HBV infection in the investigation of

liver cirrhosis. Persistent viral infection has been reported in area where HBV infection is endemic after the loss of HBsAg. Many studies have shown that HBV infection may occur in HBsAg-negative patients with or without serologic markers of previous infection (anti-HBs or anti-HBc). In fact, in HBV infection; HBsAg sero-clearance does not necessarily reflect HBV eradication. Accumulated data indicated that a low level of HBV-DNA remains detectable in serum and liver tissue in some patients who cleared HBsAg from either acute self-limited or chronic HBV infection, or even after

---

From the Department of Gastroenterology (Honarkar, Saeedfar, Zali), Research Center of Gastroenterology and Liver Diseases, Shahid Beheshti University of Medical Science, Department of Internal Medicine (Alavian), Baqiatollah Medical University and the Department of Biochemistry (Samiee), Iran Blood Transfusion Organization, Tehran, Iran.

Received 26th June 2004. Accepted for publication in final form 4th December 2004.

Address correspondence and reprint request to: Dr. Zahra Honarkar, Research Center of Gastroenterology and Liver Diseases, Shahid Beheshti University of Medical Sciences, Taleghani Hospital, Tabnak St., Evin, Tehran, Iran. Tel. +98 (21) 2418872. Fax. +98 (21) 2402639. E-mail: honarkar\_z@yahoo.com

a successful anti-HBV treatment. Demonstration of this clinical entity has resulted in introduction of the concept of 'occult, silent, or latent' HBV infection, which defines presence of HBV infection with undetectable HBsAg.<sup>1,8</sup> The proportion of chronic hepatitis in which HBV-DNA is detectable depends on different parameters such as: (1) the method used for HBV-DNA detection, even by PCR, the choice of primers and the experimental conditions are critical; (2) the origin of the samples, prevalence being potentially higher in clinical settings with liver disease patients and/or in regions of high-HBV endemicity and (3) whether serum, peripheral blood mononuclear cells (PBMCs) or liver tissue are tested.<sup>1-8</sup>

The clinical impact of occult HBV infection after HBsAg sero-clearance remains uncertain in chronic liver disease (CLD) patients. It remains to be clarified whether persistent occult HBV infection exerts any adverse effect on the liver disease. To address these issues, virological and histological features were studied among patients with CLD in Iran.

**Methods.** Study samples were obtained from the 65 patients of Research Center for Gastrointestinal and Liver Diseases and Tehran Hepatitis Center, Tehran, Iran, during the years 2001 to 2002. All of them were suffering from CLD, had negative HBsAg and had been undertaken liver biopsy. There was no history of antiviral therapy in any patient. The paraffin-embedded liver tissue of these patients were investigated for presence of HBV-DNA by polymerase chain reaction (PCR) and existence of HBsAg and HBeAg by immunohistochemistry (IHC) technique. All laboratory procedures (PCR and IHC) were performed in Iran Blood Transfusion Organization (IBTO) Laboratory, Tehran, Iran.

Patients were identified as cases with a persistent increase in alanine aminotransferase (ALT) (>1.5 time the upper limit of normal on at least 2 different occasions) or have impaired liver function over a minimum period of 6 months. Epidemiological data (previous history of acute hepatitis, transfusion, intravenous drug addiction, acupuncture, tattooing, and so forth), clinical data (patient age, gender, body mass index [body weight in kg/height in meters]), and biochemical parameters including glucose, triglycerides, cholesterol, and protein electrophoresis were obtained from patient's charts and recorded in a questionnaire. According to clinical, biochemical, serological and pathological findings the clinical diagnosis was chronic hepatitis C, cryptogenic liver disease, non-alcoholic steatohepatitis (NASH) and autoimmune liver disease.

The cryptogenic liver disease cases met the following criteria (i) Absence of HBsAg and

anti-HCV antibodies in serum. (ii) Ferritin, alpha 1 antitrypsin, a ceruloplasmin levels within the normal range. (iii) Antinuclear, antimitochochrial, and anti-smooth muscle antibodies at a titer of <1/40. (iv) Ethanol intake less than 80 g/day. (v) Absence of treatment with potentially hepatotoxic drugs. (vi) Negative human immunodeficiency virus (HIV) serology. (vii) Absence of decompensated diabetes, thyroid dysfunction, morbid obesity (defined as body mass index of >35 kg/m<sup>2</sup>) or other systemic diseases which might affect the liver, including severe hyperlipidemia (cholesterol or triglyceride serum levels greater than 350 mg/dl). (viii) Absence of focal intrahepatic lesions or biliary abnormalities at ultrasonography or even normal endoscopic retrograde cholangiopancreatography (ERCP) in some patients.

**Liver histopathology.** Different histological parameters were reported: fibrosis, portal inflammation, piecemeal necrosis, lobular inflammation, lobular necrosis, steatosis, cholestasis, bile duct damage, sinusoidal dilation, and iron deposition. According to these data, liver biopsies were classified into 3 groups: 1) Chronic hepatitis and cirrhosis according to international criteria.<sup>9</sup> 2) Non-alcoholic steatohepatitis (NASH). 3) Non-specific/minimal changes, a variety of mild abnormalities including intrahepatocytic cholestasis, steatosis, sinusoidal dilation, and mild lobular inflammation or necrosis.

**Immunohistochemistry.** Immunoperoxidase staining for HBV surface and core proteins were performed by kits from DAKO company (clone HBeAg, lot No:128, antibody concentration: 1/500 and code No: BO586 and clone HBsAg: 3E7, lot No: 058, antibody concentration: 1/50 and code No: M3506) in all liver samples. Then samples were interpreted by immunofluorescent microscope.

**Hepatitis B virus-DNA polymerase chain reaction.** DNA was extracted from paraffin-embedded liver tissue using Greer et al method<sup>10</sup> with some modification. A fundamental safeguard to prevent cross contamination between block preparation was carried out. Every extraction and PCR sets included: 12 samples, 7 patients paraffin-embedded block, 3 water as negative controls to detect cross contamination and 2 positive controls to establish sensitivity, corresponding to 3000 and 300geq/ml (VQC Panel). The conserved region on S gene was selected. Polymerase chain reaction was performed using the following primers:

Primer #1 (nt109-139):  
ATACCACAGAGTCTAGACTCGTGGTGACT

Primer 2R (nt 555-586):  
AAGCCCTACGAACCACTGAACAAATGGCAC

Briefly 6 $\mu$ l DNA was amplified for 35 cycle 95°C for 1 minute, 60°C for 1 minute and 72°C for 1 minute following by final extension at 72°C for 10 minutes in total reaction mixture of 20 $\mu$ l containing 10mM Tris-Hcl pH 8.3, 1.5 mM Mgcl<sub>2</sub> (promega) 50mM Kcl 200 $\mu$ M dNTP (Roche) 1.5 U of Taq-polymerase and 0.5  $\mu$ M each primer. 10 $\mu$ l of reaction mixture were loaded on a 2% agarose gel electrophoresis. All precautions for avoiding contamination were followed stringently. Each positive result was confirmed by a second independent determination. The sensitivity of assay was 300 gem/ml. Occult hepatitis B was defined as detectable HBV-DNA in liver tissue.

**Statistical analysis.** Fisher's exact test was used to compare proportions and the Student's t test to compare continuous variables. The Mann-Whitney U test was used to compare non-parametric variables in independent samples. All statistical tests were 2-tailed. A *p* value of 0.05 (2-tailed) was considered to indicate significance.

**Results.** We investigated 65 patients referred for liver biopsy because of persistent (more than 6 months) elevation of serum transaminases. In 19 cases the liver tissue was not enough. Some patients with unavailable clinical data also were excluded from the study. Therefore, the investigated cases decreased to 35 as the following: hepatitis C 27 (77.1%), cryptogenic liver disease 7 (20%), autoimmune hepatitis 1 (2.9%). Twenty-two males (62.9%) and 13 females (37.1%) with a mean age of 32.5  $\pm$  17.39 were studied. Most of the patients presented with non-specific symptoms of chronic hepatitis (84.3%). Signs and symptoms of advanced liver disease or cirrhosis had been reported in 5.7% of patients.

Histopathological findings were as follow chronic hepatitis 29 (82.8%), cirrhosis 3 (8.5%), non-specific reactive changes and mild steatosis 1 (2.9%) and normal histology 2 (5.8%).

Clinical and biochemical findings according to result of HBV DNA PCR patients were divided to 2 groups, HBV-DNA positive and HBV-DNA negative (Table 1). Clinical and biochemical findings were compared between 2 groups. As shown in Table 1, no significant difference was found between 2 groups according to age, gender, duration of disease, or history of risk factors (transfusion, intravenous drug abusing, needle stick or surgery), clinical diagnosis and level of aminotransferase. But completely significant difference was shown according to clinical presentation and stage of liver disease between 2 groups. Decompensated cirrhosis and more advanced pathology were found in HBV DNA positive group.

**Viral markers.** Hepatitis B core antigen for 25 and HBsAb for 26 patients were available. Hepatitis B core antigen in 12 (34.3%) and HBsAb

in 3 (8.6%) were positive. Hepatitis B core antigen in 40% and HBsAb in 20% of HBV-DNA positive were reported to be positive. No significant correlation was found between HBV-DNA positivity and presence of HBcAb or HBsAb in serum. Approximately 77.1% of all patients and 50% of patients with positive HBV-DNA had hepatitis C, which indicates high prevalence of occult HBV infection in patients with chronic hepatitis C. More than 50% of hepatitis C patients were positive either for HBc or HBs antibodies. About 14.3% of hepatitis C patients were positive for HBV-DNA. Finally, it is worth noting that for all viral markers (HCV RNA, HBV-DNA, and anti-HBV antibodies), only one of 35 cases lacked serological signs of contact with hepatitis viruses.

Hepatitis B surface and HBc proteins were investigated in liver biopsies by immunohistochemistry. All cases were found to be negative.

**Prevalence of HBV-DNA.** Of the 8 HBV-DNA positive patients, 4 patients (50%) had hepatitis C and 4 patients (50%) had cryptogenic liver disease. Regarding to the prevalence of HBV-DNA in different histopathological forms of liver damage, in patient with positive HBV-DNA, 37.5% had cirrhosis, 37.5% had chronic hepatitis, 12.5% had non-specific and 12.5% had normal histology. Cirrhosis was significantly more prevalent in the group of patients with detectable HBV-DNA than in cases with negative HBV-DNA (37.5% versus 0%; *p*=0.03) (Figures 1 & 2).

**Discussion.** In our series, 20% of the investigated patients were marked as cryptogenic liver disease. Frequency of occult hepatitis B in these patients was approximately 50%. In patients who underwent liver biopsy due to persistent alteration of liver biochemistry, the etiology of the liver lesion could not be determined from clinical, biochemical, or serological data obtained prior to the biopsy in 10% of cases. This value is similar to the reported prevalences of 9.2% and 8.2% for cryptogenic hypertransaminasemia observed in other European series.<sup>1,11-13</sup> In other study, up to 32% of patients who were labeled as having cryptogenic liver cirrhosis had occult HBV infection.<sup>4</sup> Different reports have indicated that low level replication of HBV and/or HCV may play a pathogenic role in a proportion of cases with cryptogenic hepatitis or cirrhosis.<sup>1,12-13</sup> Our study demonstrated that occult HBV infection is common among patients with cryptogenic liver cirrhosis in an area where HBV infection is prevalent. Hepatitis B surface antigen alone is insufficient for the diagnosis of HBV infection, and screening for occult HBV infection by HBV-DNA assay is necessary before diagnosis of cryptogenic cirrhosis.

Table 1 - Clinical, biochemical and histological features of patients with chronic liver disease according to the presence of HBV-DNA.

Characteristics	HBV-DNA positive N=8	HBA-DNA negative N=27	p value
Mean age (years)	41 ± 14	27 ± 18	0.116
Gender ratio (M/F)	5/3	17/10	1.0002
Mean duration of disease	18 ± 16	23 ± 20	0.496
<b>Risk factor (%)</b>			
Transfusion	2 (25)	10 (40)	0.678
Intravenous abuser	0	5 (19.2)	0.527
Needle Stick	0	3 (12)	0.419
Surgery	6 (85.7)	20 (85.7)	0.754
<b>Clinical presentation (%)</b>			
Decompensated cirrhosis	6 (75)	23 (85)	0.017
Non-specific symptom	2 (25)	4 (15)	
<b>Clinical Dx (%)</b>			
Hepatitis C	4 (50)	23 (85.2)	0.051
Cryptogenic	4 (50)	3 (11.1)	
-AIH	0	1 (3.7)	
<b>Biochemical</b>			
Aspartate transaminase	99 ± 78		
Alanine aminotransferase	153 ± 162	118 ± 87	0.559
ALP	446 ± 332	157 ± 172	0.949
		268 ± 158	0.073
<b>Serology</b>			
Hepatitis B core antigen positive (%)	2/5 (40)	10 (50)	1.000*
Hepatitis B surface antigen positive (%)	1/5 (20)	2 (9.5)	0.488
<b>Pathology</b>			
Cirrhosis (%)	3 (37.5)	0	0.01
Chronic hepatitis (%)	3 (37.5)	26 (96.3)	
Normal (%)	1 (12.5)	1 (3.7)	
Non-specific (%)	1 (12.5)	0	

\*Fisher's exact test, HBV-DNA - hepatitis B virus-DNA, M - male, F - female, AIH - auto immune liver diseases, ALP - alkaline phosphatase

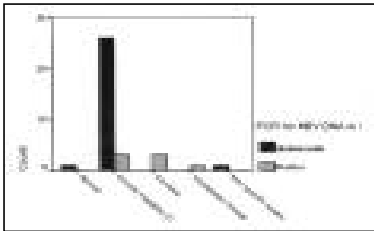


Figure 1 - Pathological findings among chronic liver diseases patients. PCR - polymerase chain reaction.



Figure 2 - Hepatitis B virus-polymerase chain reaction for chronic liver disease patients number 1 to 9.

Identification of occult HBV infection before and prophylactic antiviral therapy after liver transplantation should be considered to prevent re-infection of the graft by HBV. Identification of HBV-related cirrhosis and surveillance for early, potentially resectable hepatocellular carcinoma by regular fetoprotein testing and/or ultrasound screening, and special precautions before accepting donations from patients with unexplained cirrhosis and atypical serological markers maybe beneficial.<sup>1,4,14-16</sup>

Approximately 77% of our investigated HBsAg-negative patients had chronic hepatitis C. We found that one sixth of patients with HCV-related chronic hepatitis had detectable HBV genomes, despite the absence of circulating HBsAg. This prevalence was significantly higher than that among HCV-negative patients with CLD.<sup>1,3,17-19</sup> Hepatitis B virus co-infection has been reported to be 22% in Austria, 87% in Japan, 49% in Spain and only 5.5% in French. The discrepancy in the reported incidence of HBV-DNA in HBsAg negative chronic hepatitis C patients might be due to differences in the sensitivity of the methods used for detection of viral genome, different quantity of HBV viremia and geographical variation in prevalence of HBV infection.<sup>1,7,15</sup> It has been demonstrated that occult replication of HBV at low levels can accelerate the evolution to cirrhosis in patients with chronic HCV infection.<sup>1,13,18</sup> Cirrhosis is generally considered the most important risk factor for the development of hepatocellular carcinoma. Thus, in addition to its possible direct oncogenic properties, occult HBV infection may favor neoplastic transformation in HCV-infected patients through its contribution to cirrhosis. Occult HBV infection correlates with a lack of response to interferon treatment in patients with chronic hepatitis C.<sup>1,3,14</sup>

In our study, patients with positive HBV-DNA, had a higher prevalence of cirrhosis and also signs of decompensated cirrhosis more frequently than those with undetectable HBV-DNA. These data are in accordance with reports showing a more aggressive course in cryptogenic cirrhosis when viral sequences can be detected in serum compared with patients who tested negative.<sup>1,13</sup> In one study, the PCR methodology to detect an intact direct repeat region could amplify the CCC HBV-DNA but not the incomplete HBV-DNA and integrated HBV-DNA and showed ongoing occult HBV infection and more advanced liver pathology.<sup>8</sup> In other study, there was no significant difference regarding inflammatory disease activity or hepatic fibrosis in chronic hepatitis C patients with or without HBV co-infections.<sup>7</sup> More than one third of our patients with occult HBV infection had serological markers of previous exposure to HBV.

Other study, performed among Israeli patients, demonstrated that 30% of HBsAg negative patients with CLD had HBV-DNA detectable by PCR in serum.<sup>4</sup> In that study, the positive rates of anti-HBc and anti-HBs were approximately 45%. Similar to the direct detection of HBV-DNA, serological markers of past HBV infection are also frequently detectable in HBsAg negative patients with chronic hepatitis C (20-55%).<sup>7</sup> Immunoperoxidase staining for HBV surface and core proteins were negative in all liver-biopsy specimens examined. These data suggest that occult HBV infection usually causes strong suppression of viral replication and gene expression.<sup>3,20</sup> Viral or host factors allowing HBV being persistence in the absence of HBsAg includes viral interference in co-infection with HCV or a new viral agent, HBV mutations in the core promoter region leading to minimal HBV replication and rearrangements or mutations in the HBsAg-encoding region of the viral genome, particularly in the S gene.<sup>16</sup> It is also possible that in some cases, host immune mechanisms can maintain HBV infection in a latent state until transmission to another individual who subsequently develops a more active infection especially when immunosuppressive therapy is employed.<sup>1-4,8</sup> Thus, serological recovery from chronic hepatitis B, marked by the absence of HBsAg, the occurrence of anti-HBs, reductions in anti-HBc titers and serum HBV-DNA clearance as measured by PCR, does not indicate HBV eradication and seems to merely represent immune control of viral replication. A replication-competent state of HBV infection might persist in the liver over many years after serological resolution.<sup>1,8</sup>

In conclusion, extensive studies have demonstrated that occult HBV infection represents a special form of HBV infection with clinical relevance. It seems to be common among patients with CLDs especially cryptogenic liver disease in Iran and more investigation with larger number of patients is seriously needed in the future.

**Acknowledgment.** The authors would like to thank the staff of the Iranian Blood Transfusion Organization, Tehran Office, Tehran, Iran for their kind cooperation.

## References

- Hu KO. Occult hepatitis B virus infection and its clinical implications. *J Viral Hepat* 2002; 9: 243-257.
- Chemin I, Jeanet D, Kay A, Trepo C. Role of silent hepatitis B virus in chronic hepatitis B surface antigen (-) liver disease. *Antiviral Res* 2001; 52: 117-123.
- Cacciola I, Pollicino T, Squadrito G, Cerenzia G, Orlando ME, Raimondo G. Occult hepatitis B virus infection in patients with chronic hepatitis C liver disease. *N Engl J Med* 1999; 341: 22-26.

4. Chan HL, Tsang SW, Leung NW, Tse CH, Hui Y, Tam JS, et al. Occult HBV infection in cryptogenic liver cirrhosis in an area with high prevalence of HBV infection. *Am J Gastroenterol* 2002; 97: 1211-1215.
5. Komori M, Yuki N, Nagaoka T, Yamashiro M, Mochizuki K, Kaneko A, et al. Long-term clinical impact of occult hepatitis B virus infection in chronic hepatitis B patients. *J Hepatol* 2001; 35: 798-804.
6. Hennig H, Puchta I, Luhn J, Schlenke P, Goerg S, Kirchner H. Frequency and load of hepatitis B virus DNA in first-time blood donors with antibodies to hepatitis B core antigen. *Blood* 2002; 100: 2637-2641.
7. Kazemi-Shirazi L, Petermann D, Muller C. Hepatitis B virus DNA in sera and liver tissue of HBsAg negative patients with chronic hepatitis C. *J Hepatol* 2000; 33: 785-790.
8. Yuki N, Nagaoka T, Yamashiro M, Mochizuki K, Kaneko A, Yamamoto K, et al. Long-term histologic and virologic outcomes of acute self-limited hepatitis B. *Hepatology* 2003; 37: 1172-1179.
9. Terminology of chronic hepatitis. International Working Party. *Am J Gastroenterol* 1995; 90: 181-189.
10. Greer EC, Lund JK, Manos M. PCR Amplification from paraffin-embedded tissue: Recommendation on Fixative for long term storage and prospective studies. *PCR Methods and Applications* 1991; 1: 46-50.
11. Mei SD, Yatsushashi H, Parquet MC, Hamada R, Fujino T, Matsumoto T, et al. Detection of HBV RNA in peripheral blood mononuclear cells in patients with and without HBsAg by reverse transcription polymerase chain reaction. *Hepatol Res* 2000; 18: 19-28.
12. Cabrerizo M, Bartolom inverted question marke J, Caramelo C, Barril G, Carreno V. Molecular analysis of hepatitis B virus DNA in serum and peripheral blood mononuclear cells from hepatitis B surface antigen-negative cases. *Hepatology* 2000; 32: 116-123.
13. Berasain C, Betes M, Panizo A, Ruiz J, Herrero JI, Civeira MP, et al. Pathological and virological findings in patients with persistent hypertransaminasaemia of unknown aetiology. *Gut* 2000; 47: 429-435.
14. Raimondo G. Occult hepatitis B virus infection and liver disease: fact or fiction? *J Hepatol* 2001; 34: 471-473.
15. Brechot C, Thiers V, Kremsdorf D, Nalpas B, Pol S, Paterlini-Brechot P. Persistent hepatitis B virus infection in subjects without hepatitis B surface antigen: clinically significant or purely "occult"? *Hepatology* 2001; 34: 194-203.
16. Blackberg J, Kidd-Ljunggren K. Occult hepatitis B virus after acute self-limited infection persisting for 30 years without sequence variation. *J Hepatol* 2000; 33: 992-997.
17. Fan CL, Wei L, Jiang D, Chen HS, Gao Y, Li RB, et al. Spontaneous viral clearance after 6-21 years of hepatitis B and C viruses' co-infection in high HBV endemic area. *World J Gastroenterol* 2003; 9: 2012-2016.
18. Liaw YF, Yeh CT, Tsai SL. Impact of acute hepatitis B virus superinfection on chronic hepatitis C virus infection. *Am J Gastroenterol* 2000; 95: 2978-2980.
19. Transmission of hepatitis B to patients from four infected surgeons without hepatitis B e antigen. The Incident Investigation Teams and others. *N Engl J Med* 1997; 336: 178-184.
20. Guido M, Thung SN, Fattovich G, Cusinato R, Leandro G, Cecchetto A, et al. Intrahepatic expression of hepatitis B virus antigens: effect of hepatitis C virus infection. *Mod Pathol* 1999; 12: 599-603.