

# Treatment of nosocomial meningitis due to a multidrug resistant *Acinetobacter baumannii* with intraventricular colistin

Zakeya Bukhary, MD, Wafeeq Mahmood, MD, Ahmed Al-Khani, FRCSC, Hail M. Al-Abdely, MD.

---

## ABSTRACT

We report a case of serious nosocomial meningitis due to a multidrug-resistant *Acinetobacter baumannii* in a 23-year-old woman who had a posterior fossa craniotomy with upper cervical laminectomy for excision of a meningioma at the level of foramen magnum. Post-operatively, she had neck pain with continuous fever and deterioration in the level of consciousness and convulsions. The CSF was turbid and had neutrophil pleocytosis. A multidrug-resistant *Acinetobacter baumannii* was isolated from the blood and CSF. The patient failed high doses of imipenem, ciprofloxacin and systemic colistin but responded well to intraventricular injections of colistin 125,000 units twice daily for 3 weeks. No apparent side effects were noticed. We have reviewed other similar cases reported in the literature.

Saudi Med J 2005; Vol. 26 (4): 656-658

---

Nosocomial infections due to *Acinetobacter baumannii* (*A.baumannii*) are associated with intensive care unit (ICU) stay, mechanical ventilation and the use of broad-spectrum antimicrobial therapy.<sup>1,2</sup> Effective therapy is limited by antibiotic resistance and poor diffusion of many antibiotics into the subarachnoid space. Meningitis due to *A.baumannii* is associated with high attributable mortality.<sup>3</sup> This may have been largely due to limited therapeutic options because of resistance to most of the available antibiotics. There are 4 previously reported cases of nosocomial meningitis due to multidrug-resistant *A.baumannii* that were treated with intra-ventricular colistin.<sup>4-6</sup> We report the outcome of colistin administered directly into the ventricles for a life-threatening multidrug-resistant *A.baumannii* infection in a neurosurgical patient.

Case Report. A 23-year-old Saudi woman was referred to the neurosurgical department at King Faisal Specialist Hospital and Research Centre, Riyadh, Saudi Arabia in May 2002 with a diagnosis of intradural tumor at the cervico-medullary junction. She was complaining of a progressive lower extremity weakness for one year. Physical examination revealed spastic quadriplegia and MRI revealed a large foramen magnum extra-axial dural mass. She underwent a posterior fossa craniotomy and C-1, 2 and 3 laminectomy with total excision of the mass. Histopathological diagnosis was consistent with meningioma. The patient had CSF leakage from the surgical wound. On postoperative day 13, she complained of neck pain with continuous fever, and shortly afterwards she became unresponsive with convulsions. A CT scan of the

---

From the Sections of Infectious Diseases (Bukhary, Al-Abdely) and Critical Care Medicine (Mahmood), Department of Medicine and the Section of Neurosurgery (Al-Khani), Department of Neuroscience, King Faisal Specialist Hospital and Research Centre, Riyadh, Kingdom of Saudi Arabia.

Received 21st September 2004. Accepted for publication in final form 2nd January 2005.

Address correspondence and reprint request to: Dr. Hail M. Al-Abdely, Section of Infectious Diseases, Department of Medicine (MBC 46), King Faisal Specialist Hospital and Research Centre, PO Box 3354, Riyadh 11211, Kingdom of Saudi Arabia. Tel. +966 (1) 4427494. Fax. +966 (1) 4427499. E-mail: abdely@kfsrh.edu.sa

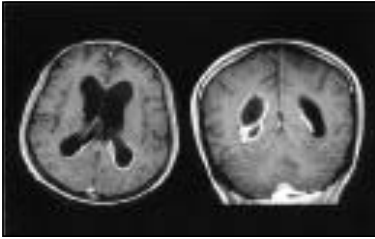


Figure 1 - An MRI sagittal and coronal sections of T-1 weighted image with contrast showing ventricular dilatation with intense enhancement of the ventricular lining consistent with ventriculitis.

brain showed hydrocephalus for which she had external ventricular drain (EVD) insertion. An MRI with contrast showed intense enhancement of the ventricular lining (Figure 1). The CSF obtained was turbid and white blood cell (WBC) count of  $3050 \times 10^6$  cell/dl with neutrophil predominance. Gram stain showed gram negative rods and culture grew a multidrug-resistant *A.baumannii*. The organism was resistant to all cephalosporins, penicillins, aztreonam, aminoglycosides, fluoroquinolones and carbapenems but susceptible to colistin (sublactam was not available). Blood culture was also positive for the same organism. This infection happened while the patient was on meropenem and vancomycin for probable nosocomial pneumonia. Although the organism was resistant to both meropenem and imipenem, the zone of inhibition around the imipenem disc was larger, therefore, she was started on imipenem 1 gm every 6 hours and intravenous ciprofloxacin 400 mg every 8 hours (colistin was not available then). The patient had slight clinical improvement on this regimen, and the number of WBC in the CSF had decreased but the daily CSF culture remained positive for *A.baumannii*. Ciprofloxacin was later replaced with moxifloxacin orally 400 mg every 8 hours. In vitro testing suggested better minimum inhibitory concentrations (MIC) to moxifloxacin than ciprofloxacin although still in the resistant range. One week later, she continued to be febrile and less responsive. Intravenous colistin was then started at a dose of 2 million units every 6 hours. After 6 days of moxifloxacin and intravenous colistin, she had partial and temporary improvement in her condition and the WBC in the CSF dropped from 1350 to 17, however, several CSF cultures remained positive for *A.baumannii*. At that time the patient was started on colistin intra-ventricular through the EVD catheter. The colistin dose was 125,000 u (5 mg) every 12 hours. It was administered in 5 ml solution of

normal saline, and the EVD catheter was clamped for 2-3 hours. Intravenous colistin and moxifloxacin were stopped. Two days later the CSF culture turned negative for the first time and remained negative throughout the course of intraventricular colistin. White cells in the CSF dropped to 2 cells/dl. She improved and regained full consciousness, however, remained on the ventilator due to debilitation and phrenic nerve palsy. She was continued on intra-ventricular colistin for 3 weeks. At day 40 of ICU-stay, she developed episode nosocomial meningitis due to *Enterococcus faecalis* that was treated successfully with intravenous and intra-ventricular vancomycin. After eradication of the organisms she underwent EVD replacement with a ventriculo-peritoneal shunt. Eventually, she was weaned off the ventilator and transferred to the ward in good condition with no evidence of relapse after 12 months of follow up.

**DISCUSSION.** Nosocomial meningitis after neurosurgical interventions is a difficult therapeutic problem because of its frequent occurrence in compromised hosts, the high degree of antimicrobial resistance among the pathogens encountered and the poor CSF penetration of potentially effective antibiotics.<sup>3,7</sup> Siegman-Igra et al described 25 cases over 5 years of nosocomial meningitis due *A.baumannii* after invasive procedures in a neurosurgical ICU. Half the organisms in that series were multidrug-resistant and the epidemic was mainly related to excessive use of antibiotics. Recently, resistant *A.baumannii* to carbapenems emerged that is only susceptible to sublactam, polymyxin, or both.<sup>1,2,8</sup>

No antibiotic alternatives have been defined for infections due to carbapenem-resistant strains. Therapy in these patients is severely threatened and currently limited to sublactam or polymyxin which is not favorable for clinical use.<sup>1,9</sup> In patients with meningitis, although there are some scattered experience of the use of the sublactam/ampicillin combinations, the efficacy of this antibiotic is questionable.<sup>10</sup> Colistin sulfomethate sodium (a polymyxin-E compound) is active in-vitro against most *Acinetobacter* species including *A.baumannii* (MIC 2mg/l).<sup>10</sup> Desirable concentrations of colistin in CSF after high dose parenteral use have been demonstrated in one report.<sup>11</sup>

To our knowledge, only 4 reported cases of carbapenem-resistant *A.baumannii* ventriculitis have been treated with direct intra-ventricular or intra-thecal colistin. Our case is the fifth case to date that survived after treatment with intra-ventricular colistin. The first case was a 16-year-old male who underwent surgery and insertion of external ventriculostomy tube because for hemangioblastoma of the fourth ventricle. He had a culture from the CSF that grew a

meropenem-resistant *A.baumannii*. He failed both intravenous and intra-ventricular tobramycin and was switched to intra-ventricular colistin 5 mg every 12 hours. The CSF cultures turned negative after 5 days on colistin and therapy was continued for 21 days. No adverse events were reported. The second patient was a 34 year-old woman who required an external ventriculostomy tube because of subarachnoid hemorrhage with hydrocephalus who developed ventriculitis with purulent discharge from the insertion site.<sup>4</sup> The CSF culture grew *A.baumannii*. A new ventricular tube was inserted, and intra-ventricular colistin 5 mg twice daily and intravenous tobramycin were administered. The CSF cultures remained positive through the fifth day of therapy. The dose of colistin was increased to 10 mg twice daily, and CSF culture was negative 24 hours later. He received intra-ventricular colistin for 21 days with no complications.

The dosage and duration of colistin intra-ventricular therapy given to our patient are similar to the above 2 cases. The CSF sterilization was achieved in 2 days after the initiation of intra-ventricular colistin. The CSF trough and peak levels were not measured. The other 2 cases due to *A.baumannii* were treated for about 3 weeks with intrathecal colistin successfully.<sup>5,6</sup> No adverse events were noticed. The fourth case received a lower dose of intra-thecal colistin at 40000 units daily.<sup>6</sup>

Our case and the other 4 cases reported in the literature suggest that direct intra-ventricular treatment with colistin is safe and efficacious in life-threatening ventriculitis due to multidrug-resistant gram negative rods especially *A.baumannii*.

## References

1. Manikal VM, Landman D, Saurina G, Oydna E, Lal H, Quale J. Endemic carbapenem-resistant *Acinetobacter* species in Brooklyn, New York: citywide prevalence, interinstitutional spread, and relation to antibiotic usage. *Clin Infect Dis* 2000; 31: 101-106.

2. Garcia-Garmendia JL, Ortiz-Leyba C, Garnacho-Montero J, Jimenez-Jimenez FJ, Perez-Paredes C, Barrero-Almodovar AE et al. Risk factors for *Acinetobacter baumannii* nosocomial bacteremia in critically ill patients: a cohort study. *Clin Infect Dis* 2001; 33: 939-946.
3. Siegman-Igra Y, Bar-Yosef S, Gorea A, Avram J. Nosocomial *Acinetobacter meningitis* secondary to invasive procedures: report of 25 cases and review. *Clin Infect Dis* 1993; 17: 843-849.
4. Fernandez-Viladrich P, Corbella X, Corral L, Tubau F, Mateu A. Successful treatment of ventriculitis due to carbapenem-resistant *Acinetobacter baumannii* with intraventricular colistin sulfomethate sodium. *Clin Infect Dis* 1999; 28: 916-917.
5. Vasen W, Desmery P, Ilutovich S, Di Martino A. Intrathecal use of colistin. *J Clin Microbiol* 2000; 38: 3523.
6. Benifla M, Zucker G, Cohen A, Alkan M. Successful treatment of *Acinetobacter meningitis* with intrathecal polymyxin E. *J Antimicrob Chemother* 2004; 54: 290-292.
7. Lu CH, Chang WN, Chuang YC. Resistance to third-generation cephalosporins in adult gram-negative bacillary meningitis. *Infection* 1999; 27: 208-211.
8. Levin AS, Levy CE, Manrique AE, Medeiros EA, Costa SF. Severe nosocomial infections with imipenem-resistant *Acinetobacter baumannii* treated with ampicillin/sulbactam. *Int J Antimicrob Agents* 2003; 21: 58-62.
9. Jimenez-Mejias ME, Becerril B, Marquez-Rivas FJ, Pichardo C, Cuberos L, Pachon J. Successful treatment of multidrug-resistant *Acinetobacter baumannii meningitis* with intravenous colistin sulfomethate sodium. *Eur J Clin Microbiol Infect Dis* 2000; 19: 970-971.
10. Catchpole CR, Andrews JM, Brenwald N, Wise R. A reassessment of the in-vitro activity of colistin sulphomethate sodium. *J Antimicrob Chemother* 1997; 39: 255-260.
11. Jimenez-Mejias ME, Pichardo-Guerrero C, Marquez-Rivas FJ, Martin-Lozano D, Prados T, Pachon J. Cerebrospinal fluid penetration and pharmacokinetic/pharmacodynamic parameters of intravenously administered colistin in a case of multidrug-resistant *Acinetobacter baumannii meningitis*. *Eur J Clin Microbiol Infect Dis* 2002; 21: 212-214.