

An unusual cause of pelvi-ureteric junction obstruction

Hilal Matta, FRCS, Akhter Nawaz, FRCSI, Ahmed H. Al-Salem, FACS, FICS.

ABSTRACT

Congenital lumbar hernia is rare in the pediatric age group. This report describes an infant with a superior lumbar hernia with herniation of the kidney that resulted in pelvi-ureteric junction obstruction. Surgical repair of the hernia and reduction of the herniated kidney resulted in resolution of the pelvi-ureteric junction obstruction. The literature on the subject is also reviewed.

Saudi Med J 2005; Vol. 26 (4): 662-664

Among all abdominal wall hernias, lumbar hernias are considered the least common and mostly seen in adults. In the pediatric age group, congenital lumbar hernia is extremely rare and when seen it is frequently associated with other congenital malformations, most commonly the lumbo-costo-vertebral syndrome.^{4,5} Lumbar hernia may be entirely extra peritoneal or contain intra-abdominal organs such as small and large bowel, omentum, stomach, and spleen. Very rarely lumbar hernia may contain the kidney.^{6,7} This report describes an unusual case of congenital lumbar hernia with herniation of the kidney that resulted in secondary pelvi-ureteric junction obstruction.

Case Report. A male infant, a product of full term spontaneous vaginal delivery was referred to our hospital at the age of 6 weeks with an asymptomatic right sided lumbar swelling that was present since birth. Examination revealed no abnormalities apart from a firm swelling in the right lumbar area consistent with an irreducible lumbar hernia (Figure 1). Plain x-ray of the abdomen showed a soft tissue mass on the right side as well as spina bifida occulta. Abdominal ultrasound and

CT scan (Figures 2a and 2b) showed mild right hydronephrosis as well as right-sided congenital superior lumbar hernia with herniation of the right kidney. He was operated on and found to have a right congenital superior lumbar hernia with herniation of the right kidney that was protruding through the hernial defect. The right kidney was reduced and the hernial defect was repaired primarily in layers. The patient had an uneventful recovery and 4 months later there was no evidence of hydronephrosis on a repeat abdominal ultrasound scan.

Discussion. Lumbar hernias are classified into acquired following surgery, infection, trauma, or both, and congenital.¹ Congenital lumbar hernia is very rare in the pediatric age group. In 1994, Lafer⁸ in an extensive review found only 42 cases of lumbar hernias in children between 0 and 13 years of age, 16 of them only were congenital.

Anatomically, the lumbar region is bounded by the 12th rib superiorly, the iliac crest inferiorly, the posterior border of the external oblique muscle anteriorly and the vertebral column and spinal muscles posteriorly. Within this region there are 2

From the Division of Pediatric Surgery, Department of Surgery, Tawam Hospital, Al-Ain, Abu Dhabi, United Arab Emirates.

Received 21st October 2004. Accepted for publication in final form 31st January 2005.

Address correspondence and reprint request to: Dr. Ahmed H. Al-Salem, PO Box 61015, Qatif 31911, Kingdom of Saudi Arabia. Fax. +966 (3) 8630009. E-mail: ahalsalem@hotmail.com



Figure 1 - Clinical photograph showing a right superior lumbar hernia.

potentially weak areas where a lumbar hernia can develop either through the superior lumbar triangle or through the inferior lumbar triangle. The superior lumbar triangle (Grynfeltt-Lesshaft triangle) is found between the inferior aspect of the 12th rib, the internal oblique muscle and the quadratus lumborum muscle.^{2,9} A lumbar hernia may also occur, although less commonly through the inferior lumbar triangle (Petit triangle) which is bounded by the iliac crest inferiorly, the external oblique muscle anteriorly and the latissimus dorsi muscle posteriorly.¹⁰ Sometimes congenital lumbar hernia may be diffuse involving most of the lumbar region.⁶

The exact etiology of congenital lumbar hernia is not known. A developmental defect occurring during the third week of embryonic life leading to derangement of the muscles and aponeurosis has been proposed as a mechanism in the etiology of congenital lumbar hernia.^{1,5} This is supported by the occurrence of congenital lumbar hernia in a patient with aplasia of the lumbo-dorsal muscles,⁶ but the mechanism does not explain the selective involvement of the lumbar region. The frequent occurrence of other malformations with congenital lumbar hernia suggests a common congenital somatic defect. The most commonly associated defect is the lumbo-costo-vertebral syndrome.^{1,3,7,8} Touloukian⁸ attributed this to a single somatic defect occurring at 3-5 weeks of embryogenesis, leading to malformations of the vertebral bodies, ribs, and trunk musculature.⁸ Other reported associated anomalies include anterior and posterior meningocele, maternal diabetes with absent tibia, congenital sciatic hernia, focal nodular hyperplasia of the liver, hydrocephalus and absent right kidney, scoliosis, congenital bilateral dislocation of radial heads, 7th nerve paralysis and pes planovalgus.^{1,4,9,11,12} Lafer⁶ on the other hand and in a report of 2 patients with lumbar hernia and neuroblastoma suggested a localized neuropraxia,

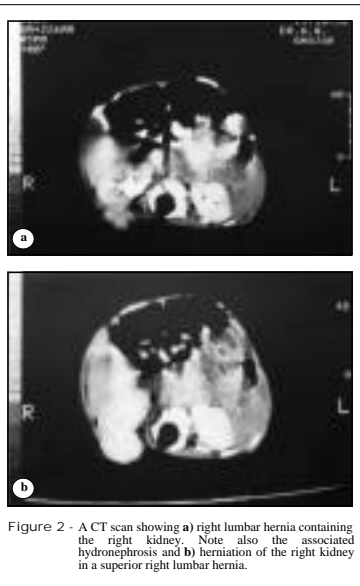


Figure 2 - A CT scan showing a) right lumbar hernia containing the right kidney. Note also the associated hydronephrosis and b) herniation of the right kidney in a superior right lumbar hernia.

temporary or permanent as an etiological factor for lumbar hernia.⁸ This may also be the cause in those with associated meningocele leading to abnormalities in muscular innervations as a result of nerve entrapment in the spinal dysraphism.¹¹

Lumbar hernia may be entirely extraperitoneal containing only retroperitoneal fat or may contain intra-abdominal organs, most commonly the bowel.^{9,10} Very rarely, the hernia may contain the kidney.^{6,7} Herniation of the kidney into a lumbar hernia was reported previously but in a 42-year-old male with an incisional lumbar hernia.⁷ In this patient and similar to our patient, herniation of the kidney resulted in pelvi-ureteric junction obstruction that resolved after surgical repair of the hernia. Lima⁶ et al reported a 5-day-old male newborn with bilateral diffuse lumbar hernias that contained the colon and the kidney. The lumbar hernias in their patient was due to congenital aplasia of the lumbo-dorsal muscles, but was not associated with pelvi-ureteric junction obstruction. Our patient represents the first infant with a true congenital lumbar hernia with herniation of the kidney that resulted in pelvi-ureteric junction obstruction.

Congenital lumbar hernia is not a surgical emergency, but we like others advocate elective repair as soon as possible.^{1,7,9,11} This is because congenital lumbar hernias are likely to grow with the child which makes the repair more difficult and also to obviate the danger of incarceration and obstruction.³ This is also the case in situations like our patient where in order to overcome the associated pelvi-ureteric junction obstruction, early repair becomes mandatory. Small lumbar hernias can be easily closed primarily, while larger defects may require local flaps or prosthetic material for their repair.

References

1. Al-Salem AH, Abu-Srair H, Qaissaruddin S. Focal nodular hyperplasia of the liver with the Lumbo-costovertebral syndrome. *J Pediatr Surg* 1996; 31: 1282-1284.
2. Bernay F, Gidenex C, Gurses N. Superior lumbar hernia associated with the lumbo-costovertebral syndrome. *Pediatr Surg Int* 1990; 5: 469-470.
3. Hancock BJ, Wiseman NE. Incarcerated congenital lumbar hernia associated with the lumbo-costovertebral syndrome. *J Pediatr Surg* 1988; 23: 782-783.
4. Somuncu S, Bernay F, Rizlar R, Ariturk E, Gunaydin M, Gurses N. Congenital lumbar hernia associated with the lumbo-costovertebral syndrome: Two cases. *Eur J Pediatr Surg* 1977; 7: 122-124.
5. Touloukian RJ. The Lumbo-costovertebral syndrome. A single somatic defect. *Surgery* 1972; 71: 174-181.
6. Lima M, Grandi M, Ruggeri G, Domini M, Bianchini MA, Ceccarelli PL, et al. Lumbar hernia as congenital aplasia of lumbo-dorsal muscle. *Eur J Pediatr Surg* 1994; 4: 110-112.
7. Presti JC Jr, Narayan P. Lumbar herniation of the kidney. *J Urol* 1988; 140: 586-587.
8. Lafer D. Neuroblastoma and lumbar hernia: a causal relationship? *J Pediatr Surg* 1994; 29: 926-929.
9. Pul M, Pul N. Congenital lumbar (Grynfelt-Lesshaft) hernia. *Eur J Pediatr Surg* 1991; 1: 115-117.
10. Lawdahl RB, Moss CN, VanDyke JA. Inferior lumbar (petit's) hernia. *AJR* 1986; 147: 744-745.
11. Lowell DG, Guzzetta PC. Lumbar hernia in a case of meningomyelocele. *J Pediatr Surg* 1986; 21: 913-914.
12. Morris P, Bruce J, Theiss N, Woodward AA. Congenital lumbar hernia and Sciatic hernia in an infant. *Pediatr Surg Int* 1992; 7: 317-318.