

High resolution computed tomography appearances of late sequelae of barium aspiration in an asymptomatic young child

Bhat Venkatraman, MD, FRCR, Hathim A. Rehman, MBBC, ABP, Atiqa Abdul-Wahab, ABP, FCCP.

ABSTRACT

Barium aspiration is a well-known complication of upper gastro-intestinal studies. Consequences of aspiration are generally insignificant and leave no permanent changes in the lung parenchyma. However, large quantities of high density barium, if aspirated, lead to silent interstitial changes and fibrosis. High-resolution computed tomography (HRCT) appearances of lung changes have been demonstrated in adults; few such reports are available in the pediatric literature. We report a case of a child who aspirated barium 3 months before this presentation. The HRCT appearances of barium aspiration are presented with a review of the literature.

Saudi Med J 2005; Vol. 26 (4): 665-667

Barium aspiration into the tracheo-bronchial tree occurs frequently in upper gastro-intestinal (GI) examinations.¹ The exact incidence is not known. Certain conditions such as head and neck cancer, broncho-esophageal fistulae, closed head injury and progressive neurological disorders predispose to aspiration pneumonia.² The overall incidence of aspiration pneumonia in the hospital population is assessed at approximately 8 in 1000, but as many as 40% of such aspiration cases remain silent.¹ Barium aspiration, due to the inert nature of the compound, is likely to be silent. However, serious consequences and even several deaths have been reported after the aspiration of either low-density or high-density barium by the patients in all age groups.^{3,4} Radiological documentation of fibrosis can be shown by high-resolution computed tomography (HRCT).² We present a young child who had HRCT 3 months after aspiration of barium. The HRCT features of lung changes are described with a review of the literature.

Case Report. A 3-year-old male, with normal prenatal and perinatal history was referred to the pulmonary clinic for assessment of a persistent abnormal chest radiograph over 3 months. Previously, he had developed normally until episodes of repeated vomiting at the age of 2 years. There was no history of weight loss or diarrhea. A radiological study of the upper GI tract in a private clinic 3 months prior to this presentation showed major gastro-esophageal reflux. The child had developed bouts of coughing with mild to moderate respiratory distress during the procedure and required hospitalization for aspiration pneumonia, most probably of the barium sulfate. He received intravenous antibiotics, respiratory physiotherapy and anti-reflux medications such as domperidone and omeprazole. Fiberoptic broncho-alveolar lavages were not performed at that time due to lack of facilities. The clinical course was uncomplicated. One week later the child was asymptomatic. A chest radiograph demonstrated lobar alveolar lesions in

From the Department of Radiology (Venkatraman) and the Department of Pediatrics (Rehman, Abdul-Wahab), Hamad Medical Corporation, Doha, State of Qatar.

Received 24th October 2004. Accepted for publication in final form 2nd January 2005.

Address correspondence and reprint request to: Dr. Atiqa Abdul-Wahab, Consultant Pediatric Pulmonologist, Department of Pediatrics, Hamad Medical Corporation, PO Box 3050, Doha, State of Qatar. Fax: +974 4439571. E-mail: atiqa@qatar.net.qa

the left mid and lower zones (**Figure 1**); the right lung was clear. The high density content of the lung parenchyma was evident on a penetrated chest examination (**Figure 2**). An HRCT examination of the chest 3 months after the barium aspiration showed lesions of different patterns in the left lower and lingula lobes. More anterior changes involving lateral basal segment of left lower lobe and lingula had an alveolar pattern resembling crazy paving pattern of microlithiasis (**Figure 3**). Posterior lung changes were mostly of peribronchial distribution. One year later he continued to do well. He has been clinically stable and asymptomatic and is gaining weight.

Discussion. Complications of barium aspiration depend upon the density of barium, the amount of aspirate, the extent of tracheo-bronchial penetration and the general physical condition of the patient. A large amount of barium aspiration with tracheo-bronchial penetration leads to acute pneumonia. Deaths have been reported in all age groups, ranging from a 2-month-old boy³ to elderly patients.⁴ Silent aspiration of barium, if not clearly observed on fluoroscopic examination, generally does not leave permanent sequelae. Such events are fairly frequent in patients with neuromuscular incoordination, swallowing dysfunction and tracheo-bronchial fistulae.

As barium sulfate is an inert substance, aspiration of it may not cause acute symptoms in a patient with a good general status and a normal cough reflex. Most of the aspirated amount is expelled by mucociliary clearance, although as many as 31% of patients present with pneumonia after aspiration during barium studies,¹ pneumonia being a presenting symptom of silent aspiration. Distribution of the aspirate depends upon the posture at the time of aspiration. Commonly affected areas are right lower lobe (55%), left lung (14%), both lungs (32%) and diffuse (2%). The depth of the tracheo-bronchial penetration correlates directly with the incidence of pneumonia. Permanent changes occur due to interstitial clearance and subsequent fibrosis of interstitial septae. Interstitial deposition of barium is probably due to a combination of factors, the amount of aspirated barium and its density, infection and local pathology in the lungs.⁵

Radiology plays a vital role in the management of aspiration pneumonia. Assessment should include the distribution of the aspirated material, its density and the subsequent clearance pattern. Routine radiography of the chest is mandatory for a suspected episode of aspiration. Because of the high atomic number ($z=56$) retained barium particles or aggregates appear as dense punctate foci on chest radiographs. Computed tomography plays an additional role in demonstrating the interstitial

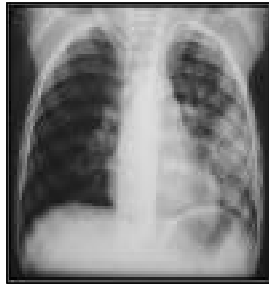


Figure 1 - Chest radiograph demonstrating alveolar lesions of lobar distribution at left mid and lower zone.

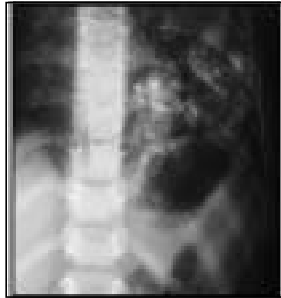

Figure 2 - High density of pulmonary lesions at left lower lobe are better appreciated in penetrated radiograph.

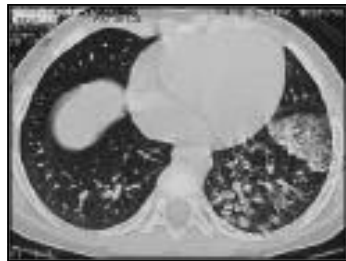

Figure 3 - An high-resolution computed tomography of lower chest demonstrating high density lesions at left lower lobe.

changes in addition to documenting distribution of barium.

The high density of the barium aspiration may be confirmed by measuring the Hounsfield units (HU) which are usually greater than 100 units. Reported HRCT findings are few and describe subpleural, centrilobular and random patterns of lesions, explained by the inorganic particle clearance mechanisms.^{2,3} A micronodular pattern in the dependent parts of the lower lobe has been described.³ Our patient showed a combination of alveolar and peribronchial interstitial patterns of aspirated barium. Gross distribution is dependent on the posture at the time of aspiration. From the review of the literature and analysis of our case, it appears that there is no single pattern which is pathognomic for late sequelae of barium aspiration apart from the high density of the lung changes. It is conceivable that the pattern of lesions is time dependent due to slow progressive clearance; the early phase of the lesion showing an alveolar, predominantly central pattern, subsequently leading to peripheral migration, interstitial changes and fibrosis. Hence, any diagnosis should be based upon the appropriate clinical background and the appearance of the high density lung lesions.

From the radiological perspective, there are few differential diagnoses if the clinical history is unhelpful. Alveolar microlithiasis may present with a very similar radiographic appearance including a crazy paving pattern in the dependent parts of lower lobes. Other differential considerations are lesions leading to lung calcification, such as hyperparathyroidism secondary to renal failure, pulmonary ossifications in osseous metastasis or

iron deposition as in hemosiderosis. Extraneous substances may also be deposited in lung parenchyma in heavy metal pneumoconiosis and amidarone toxicity.⁴

In conclusion, documentation of late sequelae of barium aspiration is relatively rare in pediatric practice. They should be suspected in appropriate clinical settings and confirmed by conventional radiography. The HRCT density of the barium appears to be a key factor in confirming the diagnosis and is useful in evaluating the long term sequelae. Hence, despite barium aspiration being a silent event with minimal lung reaction, HRCT should be performed when there are persistently clinical symptoms and an abnormal chest radiograph.

References

1. Pikus L, Levine MS, Yang YX, Rubesin SE, Katzka DA, Lauffer I et al. Videofluoroscopic Studies of Swallowing Dysfunction and the Relative Risk of pneumonia. *AJR* 2003; 180: 1613-1616.
2. Voloudaki A, Ergazakis N, Gourtsoyiannis N. Late changes in barium sulphate aspiration: HRCT features. *Eur Radiol* 2003; 13: 2226-2229.
3. Lopes-Castilla JD, Cano M, Munoz M, Sout J, Andres A, Montilla M, et al. Massive bronchoalveolar aspiration of barium sulfate during a radiologic study of the upper digestive tract. *Pediatr Pulmonol* 1997; 24: 126-127.
4. Tamm I, Kortsik C. Severe barium sulfate aspiration into the lung: clinical presentation, prognosis and therapy. *Respiration* 1999; 66: 81-84.
5. Fraser RG, Peter Pare JA. Methods of Roentgenologic and Pathologic investigations. In: Diagnosis of diseases of Chest. 2nd ed. Philadelphia (PA): WB Saunders; 1979. p. 217.