

Drotrecogin alfa (activated) treatment in a neonate with sepsis and multi organ failure

Waleed H. Albuali, MBBS, Ram N. Singh, MBBS, FRCPC, Douglas D. Fraser, PhD, FRCPC,
Leslie A. Scott, MD, FRCSC, Alik Kornecki, MD.

ABSTRACT

The administration of drotrecogin alfa (activated) improves outcome in adult patients with severe sepsis. Since the published pediatric experience with this drug is limited, the role of drotrecogin alfa (activated) in children, and especially in newborns is not well established. We describe a 3-day-old neonate with septic shock and multiorgan system failure, including circulatory, respiratory, renal failure, and disseminated intravascular coagulation, refractory to intensive fluid resuscitation and inotrope support. Within hours of drotrecogin alfa (activated) administration, the neonate experienced dramatic improvement in hemodynamic parameters. The infusion was discontinued after 48 hours, without clinical deterioration. Aside from transient thrombocytopenia, no significant side effects were observed. A brain MRI performed on day 18 after discontinuation of treatment was normal. The positive hemodynamic effect and outcome of treatment in this patient, indicates that drotrecogin alfa (activated) may play a similar role in the treatment of sepsis in neonates as already established in adults.

Saudi Med J 2005; Vol. 26 (8): 1289-1292

In the early phase of sepsis, the cytokine release stimulates the coagulation system, causing intravascular fibrin deposition, consumption of clotting factors and inhibitors, resulting in uncontrolled coagulation, and organ dysfunction.^{1,2} In the last decade, several attempts to develop agents that restore the coagulation system (for example antithrombin III, tissue factor inhibitor)³ failed, until recently, when the recombinant human activated protein C Worldwide Evaluation in Severe Sepsis (PROWESS) trial showed promising results in improving outcome by administration of drotrecogin alfa (activated) in adult patients with severe sepsis.⁴ Drotrecogin alfa (activated) (Xigris™; Eli Lilly and Company; Indianapolis) is a recombinant form of the human activated protein C (aAPC). The Federal Drug Association approved aAPC for the treatment of adult patients with severe

sepsis in 2001. As the published data regarding the administration of aAPC in children, and especially in neonates is scarce, drotrecogin alfa (activated) has not been approved for usage in patients under the age of 18 years. To date, only one case had been reported regarding the clinical impact of drotrecogin alfa (activated) in a newborn with severe sepsis.⁵ Recently, a study analyzing safety, pharmacokinetics, and pharmacodynamics of drotrecogin alfa (activated) in children, and newborns was published.⁶ We report a case of a neonate with severe sepsis who was treated successfully with infusion of drotrecogin alfa (activated), without significant side effects.

Case Report. A 5-day-old neonate was admitted to the pediatric critical care unit with

From the Department of Pediatrics, Pediatric Critical Care (Waleed, Singh, Fraser, Kornecki), and the Department of Pediatric Surgery (Scott), London Health Science Center, Children's Hospital of Western Ontario, University of Western Ontario, London Ontario, Canada.

Received 8th February 2005. Accepted for publication in final form 3rd May 2005.

Address correspondence and reprint request to: Dr. Ram Singh, Department of Pediatrics, Pediatric Critical Care, Children Hospital of Western Ontario, 800 Commissioners Road, London Ontario N6C2V5, Canada. Tel. +1 (519) 6858052. Fax. +1 (519) 6858156. E-mail: ram.singh@lhsc.on.ca

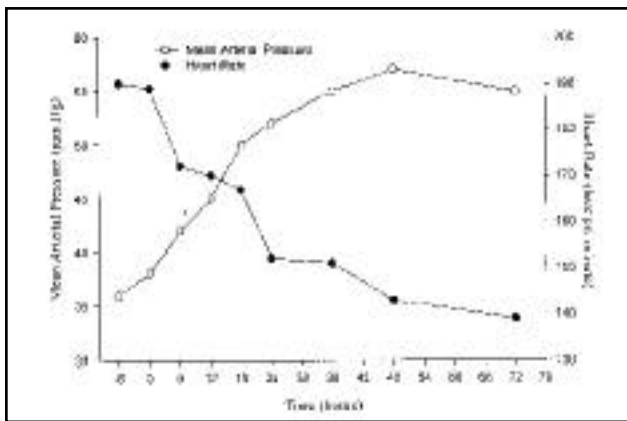


Figure 1 - Mean arterial pressure (mm Hg) and heart rate (beat per minute), 6 hours before starting the infusion (time 0), during 48 hours of infusion, and 24 hours after discontinuation of the infusion with drotrecogin alfa (activated).

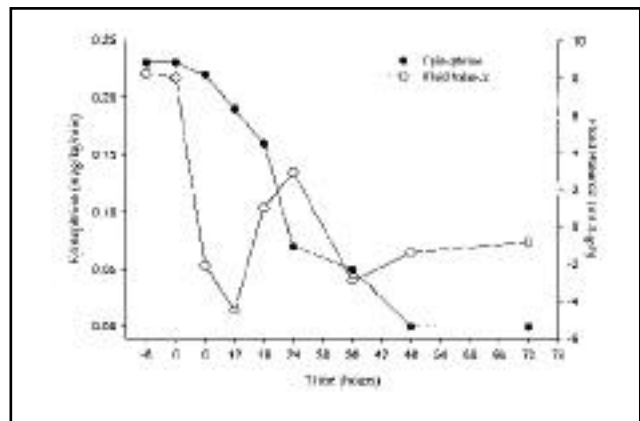


Figure 2 - Epinephrine infusion ($\text{mcg}\cdot\text{kg}^{-1}\cdot\text{min}^{-1}$) and fluid balance ($\text{mL}\cdot\text{kg}^{-1}\cdot\text{hr}^{-1}$) 6 hours before starting the infusion, during 48 hours of infusion and 24 hours after discontinuation of the infusion with drotrecogin alfa (activated).

septic shock, and multi organ failure. She was born at 38 weeks with a birth weight of 2960 g. Following one day of intermittent vomiting on day 3 of her life, she developed copious bilious vomiting with abdominal distension, and within hours her clinical status rapidly deteriorated requiring mechanical ventilation, and inotropic support. She was transferred to the critical care unit in a tertiary care center for further investigation, and treatment. On admission, she was sedated and mechanically ventilated. Her temperature was 36.8°C with heart rate of 185 beats per minute, and blood pressure of 55/18 mm Hg. Her extremities were cold with poor perfusion (capillary refill > 6 sec). The abdomen was distended, diffusely reddened with absence of bowel sounds. Blood work on admission showed a hemoglobin 11 g/dL, white blood count $3,700$ cells/ mm^3 , platelets $62,000/\text{mm}^3$, INR 2.7 IU, partial thromboplastin time 106 s, aspartate transaminase 178 U/L, alanine aminotransferase 40 U/L, bilirubin 33.5 $\mu\text{mol/L}$, lactate 13.2 mmol/L , creatinine 92 $\mu\text{mol/L}$, and blood urea nitrogen 10 mmol/L . Chest x-ray revealed diffuse bilateral alveolar infiltrates. Abdominal x-ray revealed multiple bowel fluid levels. On admission, she was on an infusion of dopamine (20 $\text{mcg}\cdot\text{kg}^{-1}\cdot\text{min}^{-1}$). Due to persistent low perfusion with severe capillary leak, and metabolic acidosis, repeated boluses of crystalloids, and colloids (total of 240 $\text{mL}\cdot\text{kg}^{-1}$ over 12 hours) were administered, and infusion of epinephrine was started. Eight hours from her arrival, once she was felt to be stable, laparotomy was performed, which showed the presence of a large amount of meconium contamination from a perforated cecum, part of the right colon was removed and ileostomy was performed. Postoperatively, her condition continued to deteriorate despite escalation of inotrope support, and fluid administration.

Vasopressin was instituted (0.00025 $\text{mcg}\cdot\text{kg}^{-1}\cdot\text{min}^{-1}$). The respiratory status gradually deteriorated with significant reduction in the total respiratory compliance. She required aggressive ventilation with high inflation pressure and high FiO_2 . After 8 hours of conventional ventilation, high frequency oscillation (mean air way pressure 30 mm Hg, FiO_2 0.8) was instituted. Despite the administration of fresh frozen plasma, and vitamin K, her coagulation continued to be abnormal. No significant bleeding was detected beside mild intermittent gastrointestinal bleed through the nasogastric tube. After 26 hours of her admission, despite high doses of inotropes and fluid support (**Figure 1**), she continued to experience poor perfusion with low arterial pressure, oliguria, and persistent lactic acidosis. At this stage, treatment with drotrecogin alfa was instituted (24 $\text{mcg}\cdot\text{kg}^{-1}\cdot\text{hr}^{-1}$), and within a short period of time her perfusion improved, mean arterial pressure increased, heart rate decreased, and both fluid and the inotrope support decreased (**Figures 1 & 2**). Epinephrine infusion was gradually weaned and stopped within 48 hours (**Figure 2**) of treatment. Dopamine infusion was weaned to 10 $\text{mcg}\cdot\text{kg}^{-1}\cdot\text{min}^{-1}$. Lactate levels gradually decreased and returned to normal within 24 hours. Drotrecogin alfa (activated) administration was discontinued after 48 hours. Infusion was tolerated well except for a reduction in the platelet count from $55,000$ to $18,000/\text{mm}^3$. Her clinical status continued to improve after discontinuation of the drug. She was extubated 12 days after her admission, and discharged from the intensive care unit after 17 days, and from the hospital after 28 days. Both brain ultrasound performed at day 8, and MRI performed at day 18 after discontinuation of treatment were normal without signs of intracranial hemorrhage.

DISCUSSION. Although the outcome in neonatal, and pediatric sepsis has improved over the years with a significant reduction in mortality from 97% to 9%,^{7,8} sepsis, and in particular sepsis associated with multi organ failure is a major cause of morbidity, and mortality in children.^{9,10} Over the past decade, several modalities of treatment for sepsis have been suggested, however, only drotrecogin alfa (activated) has been shown in a randomized controlled study to improve the mortality or morbidity. Over the last few years a new understanding of sepsis pathophysiology with regards to the coupling of inflammation, microvascular coagulation, and endothelial cell dysfunction has emerged.^{11,12} Protein C is a glycoprotein that is synthesized in the liver, and is vitamin K dependent. It is activated by endothelial, and platelet thrombin/thrombomodulin complexes and requires protein S as a cofactor. After its activation, protein C has an antithrombotic, profibrinolytic, and anti-inflammatory properties. The anti inflammatory effects of aAPC are both, indirect by inhibition of thrombin formation, and direct via blockage of cytokine formation,¹³ inhibition of selectin activity, and nuclear factor kB translocation.¹⁴ During sepsis the ongoing consumption of the coagulation regulators (antithrombin, protein S, and protein C) cause uninhibited coagulopathy. The levels of aAPC fall due to increased consumption, and impaired activation via the thrombin/thrombomodulin complexes. Acquired protein C deficiency in adult and children during sepsis was observed to be related to severity of sepsis, and increased morbidity and mortality.¹⁵

In the last few years, the use of recombinant protein C was explored and reported to affect the outcome of adult patients with sepsis.⁴ The PROWESS trial demonstrated significant reduction in mortality in adult patients with severe sepsis (24.7% versus 30.8% in control).⁴ At present, the data regarding the use of this drug in children are limited and therefore, the Food and Drug Administration (FDA) has approved the drug for use only in adults older than 18 years. In children and newborns, only a preliminary study of safety, pharmacokinetics, and pharmacodynamics was performed.⁶ To date, only one case report has been published in relation to the clinical impact, and specifically on hemodynamic status of the use of drotrecogin alfa (activated) in a newborn.⁵ We described the clinical improvement associated with the treatment, but no brain imaging that excludes potential intracranial hemorrhage was reported.⁵ A more recent case report in an infant (4-months-old) describes the positive effects of drotrecogin alfa (activated), and reports a small occipital hemorrhage on MRI, which may be related to the treatment, or

to the disseminated intravascular coagulation.¹⁶ The main side effect reported with the drug is major bleeding.^{4,6} The incidence of major bleeding reported in adults is 2.4%, and in children is 4.8%.^{4,6} This effect is consistent with the pharmacological antithrombotic properties of protein C.

In the patient presented, drotrecogin alfa (activated) was administered to a newborn with septic shock, and multi organ failure that was consistently deteriorating despite aggressive treatment with fluid and inotropes over 24 hours. A rapid and significant hemodynamic improvement within hours of starting therapy was observed. The perfusion improved, mean arterial pressure increased (**Figure 1**), fluid requirement decreased (**Figure 2**) urine output increased, inotrope support was weaned gradually (**Figure 2**), and lactic acidosis gradually resolved. Treatment was discontinued within 48 hours. No significant side effects, other than thrombocytopenia were observed. The newborn described developed thrombocytopenia prior to the administration of the drug (55,000/mm³) however, the drop in platelets count during therapy (18,000/mm³), and the increase in the count after termination of treatment suggests that the thrombocytopenia observed was associated with administering of the drug.

The positive effect and outcome of treatment in this case indicate that drotrecogin alfa (activated) may play a similar role in the treatment of sepsis in newborns as has already been established in adults. A randomized control trial is required in order to establish the efficacy of this treatment in children. However, a physician faced with a newborn or an infant with life threatening illness may consider the option of off label use of Drotrecogin alfa (activated).

References

1. Hack CE, Zeerleder S. The endothelium in sepsis: source of and a target for inflammation. *Crit Care Med* 2001; 29: 21-27.
2. Pinsky MR. Pathophysiology of sepsis and multiple organ failure: pro-versus anti-inflammatory aspects. *Contrib Nephrol* 2004; 144: 31-43.
3. Warren BL, Eid A, Singer P, Pillay SS, Carl P, Novak I, et al. Caring for the critically ill patient. High-dose antithrombin III in severe sepsis: a randomized controlled trial. *JAMA* 2001; 286: 1869-1878.
4. Bernard GR, Vincent JL, Laterre PF, LaRosa SP, Dhainaut JF, Lopez-Rodriguez A, et al. Efficacy and safety of recombinant human activated protein C for severe sepsis. *N Engl J Med* 2001; 344: 699-709.
5. Rawicz M, Sitkowska B, Rudzinska I, Kornacka MK, Bochenski P. Recombinant human activated protein C for severe sepsis in a neonate. *Med Sci Monit* 2002; 8: 90-94.
6. Barton P, Kalil AC, Nadel S, Goldstein B, Okhuysen-Cawley R, Brill J, et al. Safety, pharmacokinetics, and pharmacodynamics of drotrecogin alfa (activated) in children with severe sepsis. *Pediatrics* 2004; 113: 7-17.

7. Watson RS, Carcillo JA, Linde-Zwirble WT, Clermont G, Lidicker J, Angus DC. The epidemiology of severe sepsis in children in the United States. *Am J Respir Crit Care Med* 2003; 167: 695-701.
8. Angus DC, Linde-Zwirble WT, Lidicker J, Clermont G, Carcillo J, Pinsky MR. Epidemiology of severe sepsis in the United States: analysis of incidence, outcome, and associated costs of care. *Crit Care Med* 2001; 29: 1303-1310.
9. Leclerc F, Leteurtre S, Duhamel A, Grandbastien B, Proulx F, Martinot A, et al. Cumulative influence of organ dysfunctions and septic state on mortality of critically ill children. *Am J Respir Crit Care Med* 2005; 171: 348-353.
10. Natanson C, Esposito CJ, Banks SM. The sirens' songs of confirmatory sepsis trials: selection bias and sampling error. *Crit Care Med* 1998; 26: 1927-1931.
11. le Roux P. An update on the pathophysiology of sepsis. *SADJ* 2004; 59: 163-165.
12. Weigand MA, Horner C, Bardenheuer HJ, Bouchon A. The systemic inflammatory response syndrome. *Best Pract Res Clin Anaesthesiol* 2004; 18: 455-475.
13. Grey ST, Tsuchida A, Hau H, Orthner CL, Salem HH, Hancock WW. Selective inhibitory effects of the anticoagulant activated protein C on the responses of human mononuclear phagocytes to LPS, IFN-gamma, or phorbol ester. *J Immunol* 1994; 153: 3664-3672.
14. Grinnell BW, Hermann RB, Yan SB. Human protein C inhibits selectin-mediated cell adhesion: role of unique fucosylated oligosaccharide. *Glycobiology* 1994; 4: 221-225.
15. Fijnvandraat K, Peters M, Derkx B, van Deventer S, ten Cate JW. Endotoxin induced coagulation activation and protein C reduction in meningococcal septic shock. *Prog Clin Biol Res* 1994; 388: 247-254.
16. Sajan I, Da-Silva SS, Dellinger RP. Drotrecogin alfa (activated) in an infant with gram-negative septic shock. *J Intensive Care Med* 2004; 19: 51-55.