Clinical Quiz

Submitted by: Fahmi Y. Khan, MD
Senior Specialist, Department of Medicine,
Hamad General Hospital, PO Box 3050, Doha, Qatar
Tel. +974 4879228. Fax. +974 4392273. E-mail: fakanqal@yahoo.co.uk

Notice: Authors are encouraged to submit quizzes for possible publication in the Journal. These may be in any speciality, and should approximately follow the format used here (maximum of 2 figures). Please address any submissions to: Editor, Saudi Medical Journal, Armed Forces Hospital, PO Box 7897, Riyadh 11159, Kingdom of Saudi Arabia. Tel. +966 (1) 4777714 Ext. 6570. Fax. +966 (1) 4761810 or 4777194.

Unusual cause of dysphagia

Clinical Presentation

A 14-year male patient presented with a one-month history of difficulty in swallowing, mainly for solid food, of gradual onset, associated with loss of weight, but no fever. Plain radiographs and CT examination of the chest were carried out (**Figure 1 & 2**). A thoracic surgeon was consulted; he decided to intervene surgically.

Figure 1 - Plain radiograph of the chest.

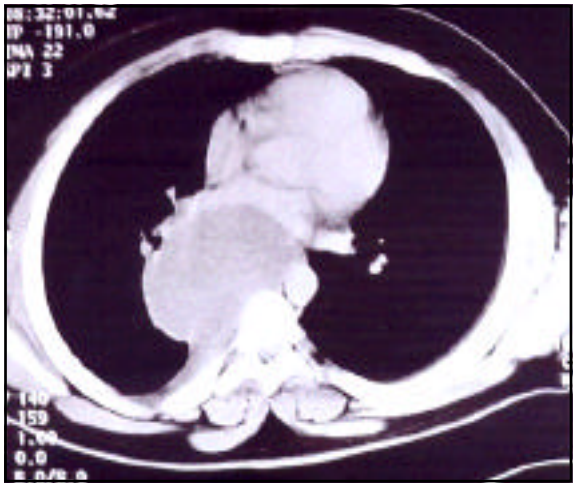

Figure 2 - Chest CT.

Questions

1. Describe the images.
2. Mention a differential diagnosis?
3. What is the likely diagnosis?

Answers

1. Plain radiographs of the chest show a spherical mass projecting from the mediastinum. The CT examination reveals a large, smooth-walled cyst with water density.

2. The differential diagnoses include: Bronchogenic cyst, cystadenomatous malformation, Swyer-James syndrome.

3. Bronchogenic cyst: The diagnosis of Bronchogenic cyst was established after histopathologic examination of the resected tumor.

Discussion

Bronchogenic cysts are thin walled cystic structures formed by abnormal detachment of a fragment of primitive foregut. The result is an outbranching of the bronchial tree lined with bronchial epithelium and filled with mucus. They may be either mediastinal, parenchymal or, sometimes, infradiaphragmatic. Bronchogenic cysts may present with compressive symptoms such as chest pain, cough, dyspnea, or acute respiratory distress, particularly in children,[1] while in adults, chest pain and dysphagia are the most common symptoms. In the absence of adjacent structures prone to compression, most bronchogenic cysts remain asymptomatic. A rare complication is the risk of transformation to rhabdomyosarcoma. Mediastinal cysts are visualized as a mediastinal mass on conventional radiographs. Intrapulmonary cysts usually present as a solitary pulmonary nodule unless the cyst contains air.[2] The CT demonstrates a sharply defined, smoothly marginated, homogeneous mass. Differences in attenuation result from the amount of proteinaceous fluid within the cysts. Cysts do not enhance after administration of intravenous contrast.[2] On MRI, bronchogenic cysts are usually bright on T2-weighted images and dark on T1-weighted images. Cysts do not enhance after administration of intravenous gadolinium.[2] The diagnosis of bronchogenic cyst can be confirmed nonoperatively by needle aspiration of the contents. The cyst fluid can be examined to exclude malignant cells, and a confirmed diagnosis of bronchogenic cyst may, in the appropriate clinical circumstances, obviate the need for operative removal.[3]

References

1. Ribet ME, Copin MC, Gosselin B. Bronchogenic cysts of the mediastinum. ***J Thorac Cardiovasc Surg*** 1995; 109: 1003-1010.
2. Zhang Z. [Surgical treatment of mediastinal bronchogenic cyst in the adult: a report of 10 cases]. ***Zhongguo Yi Xue Ke Xue Yuan Xue Bao*** 1990; 12: 445-447. Chinese
3. McAdams HP, Kirejczyk WM, Rosado-de-Christenson ML, Matsumoto S. Bronchogenic cyst: imaging features with clinical and histopathologic correlation. ***Radiology*** 2000; 217: 441-446.