

Foreign body in the vallecula presenting as acute epiglottitis with unilateral supraglottitis

*Latifi Asrar, MS (ENT), DLO (Lon), Nureni Oyetunji, FRCS (Edin), DLO,
Sayed S. Raza, FRCS (Oto), DLO, Imranulhaque Zeyaulhaque, MBBS, MD (Path).*

ABSTRACT

Life threatening inflammatory swelling of the epiglottic and supraglottic regions secondary to a foreign body in the vallecula is an unusual occurrence. Upper airway obstruction is potentially a life threatening sequela. We present a unique case of acute epiglottitis with unilateral supraglottitis secondary to foreign body in the vallecula, which gradually improved after emergency endotracheal intubation for respiratory arrest, followed by intensive conservative management with intravenous antibiotics, cortisone and intravenous fluids. This case emphasizes that a foreign body in the vallecula presenting with severe dysphagia should be taken seriously as it may lead to life threatening complications.

Saudi Med J 2005; Vol. 26 (9): 1449-1452

Inflammation of the epiglottis and unilateral supraglottic area secondary to foreign body in the vallecula is a very unusual and unique presentation. Epiglottic and supraglottic areas are clinically important as they protect the airway and guard the laryngeal inlet. The mucosa of the supraglottic region is lax and vascular, so the inflammatory response causes immediate edema, and vascular engorgement leading to life threatening respiratory obstruction.¹ Predisposing factors include infection and thermal, caustic and traumatic insults.^{1,2} An adult patient presents with a more insidious onset of symptoms, and may have a more benign course, but, can also progress rapidly to sudden respiratory obstruction, as seen in our case. Inflammatory swelling in the vallecula should be taken very seriously to avoid life threatening respiratory complications. In this report, our objectives are to draw the attention of emergency physicians and Ear, Nose and Throat (ENT) surgeons to an unusual presentation of epiglottitis and swelling in the vallecula due to a foreign body, and to make them aware of the different ways in which epiglottitis can

present. The value of early suspicion and prompt management to avoid airway crisis is highlighted.

Case Report. A 28-year-old male Indian patient presented to the ENT Clinic in Buraidah Central Hospital, Buraidah, Kingdom of Saudi Arabia (KSA). He complained of dysphagia progressively increasing over the past 8 days, following history of swallowing a fish bone 10 days earlier. He took some treatment from a private dispensary with minimal relief. He was referred from the dispensary as his dysphagia was worsening. He was afebrile with mild tachycardia and normal blood pressure. Examination of throat revealed congested posterior pharyngeal wall with muffled voice. Indirect laryngoscopy demonstrated a medium size fleshy congested swelling in the left vallecula with a mildly congested epiglottis. Soft tissue radiograph did not reveal any foreign body. He was referred to a tertiary center for endoscopic management with the primary diagnosis of infected swelling of the left vallecula due to foreign body.

From the Department of ENT (Asrar, Oyetunji, Raza) and Histopathology (Zeyaulhaque), Buraidah Central Hospital and King Fahd Specialist Hospital, Buraidah, AlQassim, Kingdom of Saudi Arabia.

Received 12th March 2005. Accepted for publication in final form 6th June 2005.

Address correspondence and reprint request to: Dr. Latifi Asrar, PO Box 2290, King Fahd Specialist Hospital Complex, Buraidah, AlQassim, Kingdom of Saudi Arabia. Tel/Fax. +966 (6) 3238314. E-mail: latifiasrar@hotmail.com

An hour later, patient attended the Emergency Room (ER) at King Fahad Specialist Hospital (KFSH), Buraidah, KSA with severe stridor and dyspnea, progressing within a few minutes into respiratory arrest. As it was a difficult intubation, emergency endotracheal intubation was carried out by the anesthetist on call. He was revived in the ER, sedated and kept on mechanical ventilation. Direct laryngoscopy with McIntosh laryngoscope was carried out by the ENT consultant in the ER; this showed a 1 cm diameter red congested swelling in the left vallecula with grossly congested, edematous epiglottis, and left aryepiglottic fold. No foreign body was seen. A review of the x-ray showed a previously missed soft tissue shadow in the base of the tongue, epiglottic, and supraglottic region (**Figure 1**). He was kept in the Intensive Care Unit (ICU) at Buraidah Central Hospital due to unavailability of an ICU bed in KFSH. Mechanical ventilation was continued. He also received intensive treatment with intravenous ceftriaxone, hydrocortisone, analgesics, and intravenous fluids. Blood tests showed leucocytosis of 28,000 with neutrophilia and normal hemoglobin. Blood chemistry was normal. Swab for culture and sensitivity taken from the swelling did not show pathogen. A CT scan showed a swelling in the left vallecular region extending to the epiglottis and left aryepiglottic fold (**Figure 2**). On the fourth day of admission, he was extubated. Before extubation, direct laryngoscopy was carried out. The swelling in the vallecula has decreased considerably in size and appeared like a small granuloma. The epiglottis was nearly normal with a minimally congested supraglottic region. His general condition improved with a little residual hoarseness and mild dysphagia. On the eleventh day of admission, a direct laryngoscopy under general anesthesia was performed to rule out the presence of a foreign body. A small granulomatous lesion was seen on the left side of the vallecular surface of the epiglottis. Excisional biopsy was performed and sent for histopathological examination. The rest of the supraglottic area, and the vocal cord was normal. Histopathological examination showed inflamed cellular fibrous tissue covered by non-cornified squamous epithelium. A foreign body resembling a bone like structure could be seen amidst the inflammatory cells (**Figure 3**). On the thirteenth day of admission, he was discharged on oral antibiotics, cefuroxime 500 mg twice a day together with an anti-inflammatory drug. He returned to complete normality on follow-up one week later.

Discussion. The epiglottitis was first described in the eighteenth century. Theisen³ discussed 3 cases of epiglottitis in 1900, and states that Mainwaring was the first to describe the condition in 1791. An

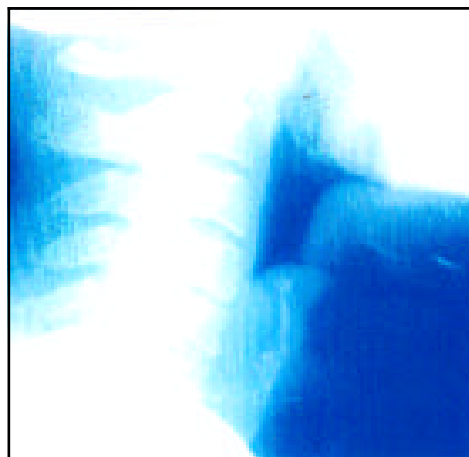


Figure 1 - Lateral soft tissue radiograph of the neck shows soft tissue shadow at the base of the tongue, epiglottic and supraglottic region.

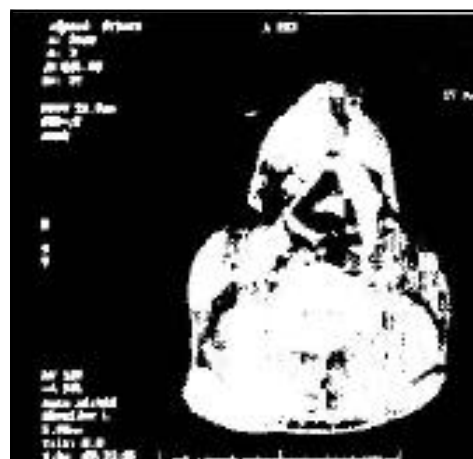


Figure 2 - Axial CT scan of the neck shows edematous tissue in the vallecular region extending to the epiglottis and left aryepiglottic fold.

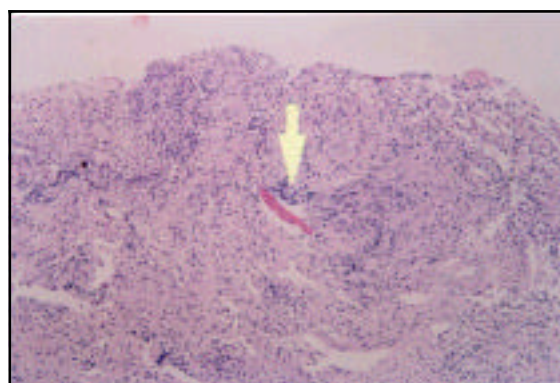

Figure 3 - Microphotograph showing inflamed cellular fibrous tissue covered by non-cornified squamous epithelium. A foreign body resembling bone like structure could be seen amidst the inflammatory cells.

accurate description of the pathology of the disease was not published until 1941.⁴ Acute epiglottitis (or supraglottitis as described by some authors) is a medical emergency. Inflammation is usually caused by infection, which affects the epiglottis and surrounding structures. Rapid swelling of the epiglottis and its surrounding structures results in severe dysphagia and airway compromise. Since the 1960s, acute epiglottitis was known to be a disease of childhood. However, recent widespread use of the hemophilus vaccination has produced a dramatic decline in epiglottitis of childhood.^{5,6} The disease is now seen more often in adults, and may be life threatening with less severe and slower onset of progression. The prodrome and deterioration vary from a matter of hours to days. Although most incidences of adult supraglottitis are infectious in origin, and involve the supraglottic and epiglottic area, we present a unique case of epiglottitis with unilateral supraglottitis caused by an inflammatory reaction secondary to foreign body in the vallecula. Infectious, thermal, caustic, and traumatic agents are the main known insults to the supraglottic area. A variety of microorganisms are considered as etiological factors in epiglottitis. However, *Haemophilus Influenza* and B-Hemolytic *Streptococci* are still considered the common pathogens.⁷ Negative throat cultures and neutrophilia is well documented in literature, and is probably due to improper culture technique, or use of antibiotics prior to admission.⁷ The same findings were noted in our case. Adult patients with progressive sore throat leading to severe dysphagia and sudden respiratory difficulty are at high risk of developing respiratory obstruction. This needs urgent and aggressive treatment in view of suspicious epiglottitis or supraglottitis. Direct visualization with direct laryngoscopy is the gold standard for definitive diagnosis, but in recent years fiberoptic nasoendoscopy has taken priority.⁵ In our case, soft tissue lateral x-ray of the neck revealed a smooth supraglottic soft tissue shadow, which was suspicious for epiglottitis, but was missed by the primary attending physician. Direct laryngoscopy, after securing the airway confirmed the diagnosis of epiglottitis and unilateral edema to the left supraglottic structures. Oral examination with a tongue depressor is deferred in suspicious cases of epiglottitis, as it may result in life threatening laryngospasm and respiratory arrest. A plain x-ray of the soft tissue neck does help in diagnosing epiglottitis with the classical finding of 'thumb sign'. A CT scan and MRI may delineate the extent of swelling in the supraglottic region and surrounding structures. Stankiewicz and Bowes⁸ reported a sensitivity of 38%, and specificity of 76%

for diagnosis of epiglottitis from soft tissue lateral x-ray of the neck. Early radiological investigations are only possible if the patient's airway is not compromised or is well secured. The presence of tachycardia, tachypnea, and stridor with hypoxemia are considered early indicators of potential airway compromise. Securing the airway is the first aim of the attending physicians. Intubation may be difficult in such cases due to edema of the supraglottic structures and distorted anatomy. The airway should be secured by either endotracheal intubation, emergency tracheostomy or cricothyrotomy. It should be managed by experienced anesthetist and ENT specialist. Empirical antibiotics should be started urgently. Intravenous fluids are given to maintain hydration. Nonsteroidal anti-inflammatory drugs are given to decrease pain and inflammation. Corticosteroids are often given on the assumption of their anti-inflammatory effect. There is no evidence-based report to support this effect.⁷ In this case, epiglottitis and unilateral supraglottitis with granuloma formation were secondary to foreign body in the vallecula. This was confirmed by endoscopic excisional biopsy. Following a Medline search, there were 2 cases of unilateral supraglottitis secondary to smoking crack cocaine.⁹ Two cases of vallecular cyst with inflammation leading to respiratory crisis.¹⁰ However, ingested foreign body in the vallecula leading to epiglottitis and unilateral supraglottitis has not previously been documented.

In conclusion, we report an atypical case of epiglottitis triggered by inflammation in the vallecula due to foreign body. Any inflammatory swelling in the vallecula should be taken seriously as inflammation can extend to the epiglottis and supraglottic area leading to the life threatening airway complication. Prompt and early diagnosis, aggressive management with utmost care to the airway will avoid such respiratory crisis.

Acknowledgment. The authors would like to thank Mr. Ahmed Abdulla AlOmar, Director of Buraidah Central Hospital, Buraidah, Kingdom of Saudi Arabia for his encouragement in the medical research activities, and Dr. Waleed Kanhkan for translating the abstract into Arabic.

References

1. Chung CH. Acute epiglottitis presenting as sensation of a foreign body in the throat. *Hong Kong Med J* 2000; 6: 322-324.
2. Kornak JM, Freije JE, Campbell BH. Caustic and thermal epiglottitis in the adult. *Otolaryngol Head Neck Surg* 1996; 114: 310-312.
3. Theisen DF. Angina epiglottidea anterior: report of three cases. *Albany Medical Annals* 1900; 21: 395-405.

4. Sinclair SE. *Hemophilus influenzae* type B and acute laryngitis with bacteremia. *JAMA* 1941; 117: 170-173.
5. Shepherd M, Kidney E. Adult epiglottitis. *Accid Emerg Nurs* 2004; 12: 28-30.
6. Chan KO, Pang YT, Tan KK. Acute epiglottitis in the tropics is it an adult disease? *J Laryngol Otol* 2001; 115: 715-718.
7. Tveteras K, Kristensen S. Acute epiglottitis in adults: Bacteriology and therapeutic principles. *Clin Otolaryngol* 1987; 12: 337-343.
8. Stankiewicz JA, Bowes AK. Croup and epiglottitis. A radiologic study. *Laryngoscope* 1985; 95: 1159-1160.
9. McQueen CT, Yarbrough WG, Witsell DL, Holmes DK, Shockley WW. Unilateral supraglottis in adults: fact or fiction. *J Otolaryngol* 1995; 24: 255-257.
10. Albert DM, Ali Z. Two cases of vallecular cyst presenting with acute stridor. *J Laryngol Otol* 1985; 99: 421-425.