

# Ovarian arteries with bilateral unusual courses

Osman Sulak, MD, PhD, Soner Albay, MD, Süleyman M. Tagil, MD, Mehmet A. Malas, MD, PhD.

---

## ABSTRACT

Bilateral unusual coursed ovarian arteries were found in a 45-year-old female cadaver. The ovarian arteries arose from the abdominal aorta at a level inferior to the corpus of L1 vertebra bilaterally. The right ovarian artery was coursing behind the inferior vena cava. The left one was coursing between the left renal artery and vein upward to the level of the inferior part of the body of Th12 vertebra. At the level of Th12 vertebra, it turned caudally and proceeded downward between the anterior-inferior and posterior segmental renal veins. On both sides, ovarian arteries were on their normal routes below the L2 vertebra accompanying the ovarian veins. The variation determined by this study would reduce possible complications of nephrectomy operations that urologists, gynecologists and other related surgeons may encounter.

Saudi Med J 2005; Vol. 26 (9): 1456-1458

---

The ovarian arteries generally arise from the anterolateral (or lateral) aspect of the abdominal aorta at a level caudal to the renal arteries, around the level of L2 vertebra.<sup>1</sup> The ovarian artery descends obliquely behind the peritoneum inferiorly and laterally to the pelvic cavity where it turns medially to enter the suspensory ligament of the ovary.<sup>2</sup> Various publications reported variations of the origin, course or the number of gonadal arteries.<sup>3-7</sup> Here, we present a previously not reported bilateral variation of the courses of the ovarian arteries (OAs) for the attention of surgeons, radiologists and anatomists.

**Case Report.** During routine dissection, OAs with unusual courses have been observed bilaterally in a female cadaver aged 45 years in the year 2004 (Figures 1-3). The right OA was found to originate from the anterolateral side of the abdominal aorta at a level 4 mm below the right renal artery and inferior part of body of L1 vertebra (Figure 1). And then it was coursing behind the inferior vena cava (IVC). The left OA was found to originate from the

anterolateral side of the abdominal aorta at a level 2 mm below the left renal artery and then course between the left renal artery and vein upward to the level of inferior part of body of Th12 vertebra (Figure 2). At this level, it turned smoothly caudally, running downward between the posterior aspect of the anterior-inferior and the anterior aspect of the posterior segmental renal veins. On both sides, ovarian arteries were on their normal routes below the L2 vertebra accompanying the ovarian veins. The diameter of the right and left ovarian arteries was approximately 2 mm at their origin.

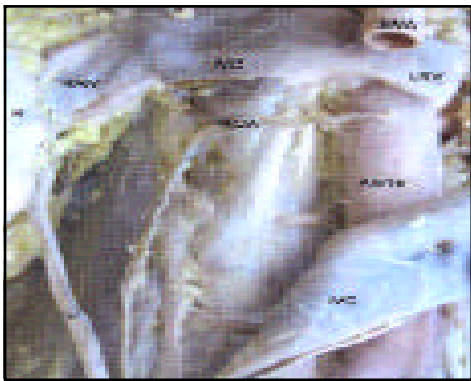
**Discussion.** Although many references regarding the variations of the testicular arteries exist in the literature, only a few cases of variation of OAs have been reported. Notkovich<sup>8</sup> described 3 different types of course of the right OA. The right OA originates from the anterolateral aspect of the abdominal aorta, beneath the left renal vein and travels inferiorly on the anterior aspect of the inferior vena cava (IVC) in Type I. In Type II, the right OA originates from the anterolateral aspect of

---

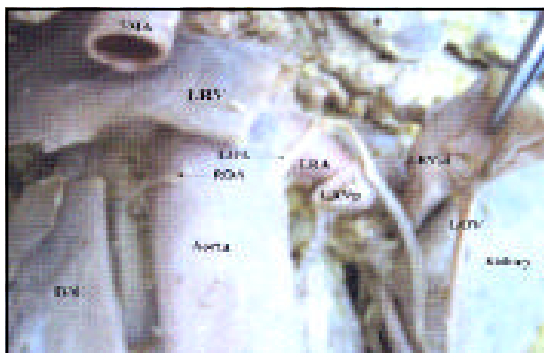
From the Department of Anatomy, Suleyman Demirel University, Isparta, Turkey.

Received 15th February 2005. Accepted for publication in final form 26th June 2005.

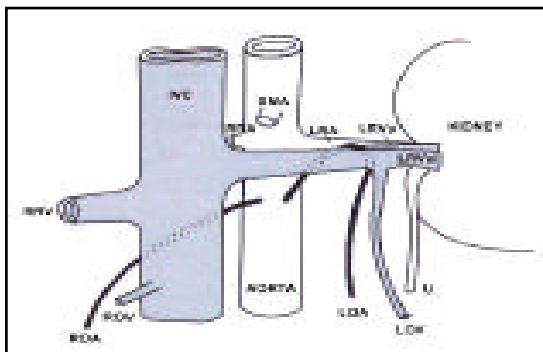
Address correspondence and reprint request to: Dr. Osman Sulak, Süleyman Demirel Üniversitesi, Tıp Fakültesi, Anatomi Anabilim Dalı, 32260 Isparta, Turkey. Fax. +90 (246) 2371165. E-mail: osulak67@hotmail.com



**Figure 1** - Photograph of the right half of the posterior abdominal wall showing the unusual course of the right ovarian artery. Inferior vena cava is dissected to demonstrate the right ovarian artery. IVC - inferior vena cava, K - kidney; U - ureter; ROA - right ovarian artery, RRV - right renal vein, LRV - left renal vein, SMA - superior mesenteric artery.



**Figure 2** - Photograph of the left half of the posterior abdominal wall showing the unusual course of the left ovarian artery. The left renal vein is dissected to demonstrate the left ovarian artery. IVC - inferior vena cava, ROA - right ovarian artery, LRV - left renal vein, LRA - left renal artery; LRVai - left anterior inferior segment of the renal vein, LRVp - left posterior segment of the renal vein, SMA - superior mesenteric artery, LOV - left ovarian vein, K - kidney.



**Figure 3** - Schematic illustration of the variations in the left and right ovarian arteries our study. IVC - inferior vena cava, RRA - right renal artery, RRV - right renal vein, LRA - left renal artery, ROA - right ovarian artery, ROV - right ovarian vein, LOA - left ovarian artery, LOV - left ovarian vein, LRVai - anterior inferior segment of the left renal vein, LRVp - posterior segment of the left renal vein, SMA - superior mesenteric artery, U - ureter.

the abdominal aorta, similar to Type I, above the left renal vein but descends, passing behind the IVC, only to turn downwards on the anterior aspect of the right renal vein. In Type III, the right OA emerges from the anterolateral aspect of the abdominal aorta, but this time above the left renal vein, passes behind the IVC and runs caudad traversing the right renal vein. In our case, the right OA emanated from the abdominal aorta below the left renal vein but in contrast to Type I in Notkovich's study, passed behind the IVC. In addition, Kurtoglu et al<sup>7</sup> founded that a right OA originating from an accessory renal artery then passing behind the IVC. However, in the present study, the right OA originated from the abdominal aorta then passed behind the IVC.

In the very same study, Notkovich<sup>8</sup> described the variability and classified the course of the left OA as well. Similarly, 3 different courses were described. The left OA originated from the antero-lateral aspect of the abdominal aorta in all types. In Type I, left AO emerged below left renal vein and coursed downward. In Type II, it emerged below the left renal vein, ran upward behind the left renal vein, turned around the vein and coursed downward from its anterior aspect. In Type III, the left OA emerged above the left renal vein, crossing this vein anteriorly on its course downwards. In our case, the left OA was found to originate from the anterolateral side of the abdominal aorta at a level 2 mm below the left renal artery, course between the left renal artery and vein upwards to the level of inferior part of the body of Th12 vertebra (Figure 2). At this level, it turned downwards smoothly, passed between the anterior-inferior and posterior segmental renal veins, namely, behind the anterior-inferior segmental and anterior to the posterior segmental renal vein. This resembles Notkovich's<sup>8</sup> Type II though the left OA passed between the anterior-inferior and posterior segmental renal veins instead of the anterior aspect of the left renal vein.

Notkovich<sup>8</sup> claims that varicocele is expected to be more common in females due to the entrapment of the ovarian vein accompanying the left ovarian artery between the renal artery and vein in Type II. During left OA's course between the segmental renal veins it is possible to get entrapped, causing diminished blood supply to the ovaries. Knowing the variations of the left OA is important for surgical interventions such as nephrectomy and renal transplants.

It is previously reported that the gonadal arteries may originate from the aorta at a higher level or may arise from the renal artery, suprarenal artery or accessory renal artery.<sup>2,4,5,9-14</sup> In contrast to these studies, there was no variation in the origin of the OA in this case but a variation in its course. In addition, Machnicki and Grzybiak<sup>15</sup> reported that 5 cases were found with atypical course of renal and

gonadal vessels along with developmental anomalies of the kidneys and ureters. In our case, there was atypical course of ovarian artery but no developmental anomalies of the kidneys and ureters were found.

Knowledge on the course of the OA is of interest not only to anatomists, but also to surgeons, radiologists, especially urologists and gynecologists to avoid clinical complications during radiological examination or surgical approaches in this region. Moreover, during surgery if the OA is damaged bilaterally, adverse complications may result such as infertility, early menopausal symptoms, sexual dysfunction that would be due to the absence of ovarian hormones, particularly in premenopausal women. Therefore, better knowledge of the anatomic variations of the ovarian artery is necessary to prevent surgical complications.

## References

1. Moore KL. Clinically oriented anatomy. 3th ed. Baltimore: Williams and Wilkins; 1992. p. 289.
2. Rahman HA, Donk K, Yamadori T. Unique course of the ovarian artery associated with other variations. *J Anat* 1993; 182: 287-290.
3. Onderoglu S, Yuksel M, Arik Z. Unusual branching and course of the testicular artery. *Ann Anat* 1993; 175: 541-544.
4. Ozan H, Gümüşalan Y, Önderoglu S, Simsek C. High origin of gonadal arteries associated with other variations. *Ann Anat* 1995; 177: 157-160.
5. Bergman RA, Cassell DM, Sahinoglu K, Heidger PM. Human doubled renal and testicular arteries. *Ann Anat* 1992; 174: 313-315.
6. Machnicki A, Grzybiak M. Variations in ovarian arteries in fetuses and adults. *Folia Morphol (Warsz)* 1999; 58: 115-125.
7. Kurtoglu Z, Aktekin M, Ozturk HA, Bobus A. A case of a right ovarian artery diverging from a right accessory renal artery. *Saudi Med J* 2004; 25: 1734-1735.
8. Notkovich H. Variations of the testicular and ovarian arteries in relation to the renal pedicle. *Surg Gynecol Obstet* 1956; 103: 487-495.
9. Asala S, Chaudhary SC, Masumbuko-Kahamba N, Bidmos M. Anatomical variations in the human testicular blood vessels. *Ann Anat* 2001; 183: 545-549.
10. Otulakowski B, Wozniak W. A case of origin of the testicular artery from the renal artery, and course of the testicular artery behind the inferior vena cava. *Folia Morphol (Warsz)* 1975; 34: 349-351.
11. Cicekcibasi AE, Salbacak A, Seker M, Ziylan T, Buyukmumcu M, Uysal I. The origin of gonadal arteries in human fetuses: anatomical variations. *Ann Anat* 2002; 18: 275-279.
12. Singh G, Ng YK, Bay BH. Bilateral accessory renal arteries associated with some anomalies of the ovarian arteries: a case study. *Clin Anat* 1998; 11: 417-420.
13. Brohi RA, Sargon MF, Yener N. High origin and unusual suprarenal branch of a testicular artery. *Surg Radiol Anat* 2001; 23: 207-208.
14. Shinohara H, Nakatani T, Fukuo Y, Morisawa S, Matsuda T. Case with a high-positioned origin of the testicular artery. *Anat Rec* 1990; 226: 264-266.
15. Machnicki A, Grzybiak M. Selected cases of atypical course of renal and gonadal arteries and veins. *Folia Morphol (Warsz)* 1997; 56: 229-236.