

# Pregnancy complicated by superior vena cava thrombosis and pulmonary embolism in a patient with Behcet disease and the use of heparin for treatment

Ahmet Kale, MD, Levent Akyildiz, MD, Nurten Akdeniz, MD, Ebru Kale, MD.

---

## ABSTRACT

Behcet disease is a multisystemic vasculitis of unknown origin. Vascular involvement has been considered to result from systemic vasculitis, occurs in 5-10% of these patients. We report a 34-year-old pregnant woman complicated by superior vena cava thrombosis, and pulmonary embolism in a patient with Behcet disease.

Saudi Med J 2006; Vol. 27 (1): 95-97

---

Behcet syndrome is a multisystem vasculitis characterized by recurrent aphthous ulcers of the mouth and genitalia, hyperreactivity of the skin to penetrating trauma (pathergy reaction), other skin lesions; arthritis, and panuveitis.<sup>1</sup> Vascular involvement has been considered to result from systemic vasculitis, which involves immuno complexes in the vessel wall and occurs in 5-10% of these patients.<sup>2</sup> Superior venacava (SVC) involvement is rare and accounts only for 9.8% of cases. Pulmonary lesions associated with Behcet disease are rare and reported to have a prevalence of 1.0-7.7%. Although, Behcet disease is mainly diagnosed during the fertile years, we know little regarding the influence of pregnancy on the clinical course of Behcet's disease. Also, we poorly understand the effect of pregnancy and the puerperium on Behcet disease. So far only a few cases analyzing this relationship have been reported in the literature.<sup>3</sup>

The aim of this article is to report on a case of SVC and pulmonary embolism and the use of heparin as treatment of life-threatening pulmonary embolism and SVC thrombosis in a pregnant woman with Behcet disease.

**Case Report.** A 34-year-old pregnant woman with a history of Behcet disease since 1998 was admitted to our hospital in February 2005 for dyspnea and chest pain at 30 weeks' gestation. The diagnosis of Behcet disease was made according to the criteria of International Study Group for Behcet Disease.<sup>4</sup> She had gravida 4, para 3 (3 spontaneous vaginal births). She had a history of intravenous systemic corticosteroids used in acute disease exacerbations and irregular colchicine (1.5 mg/day) used before pregnancy period.

On physical examination, she seemed to be in moderate distress secondary to dyspnea and chest pain.

---

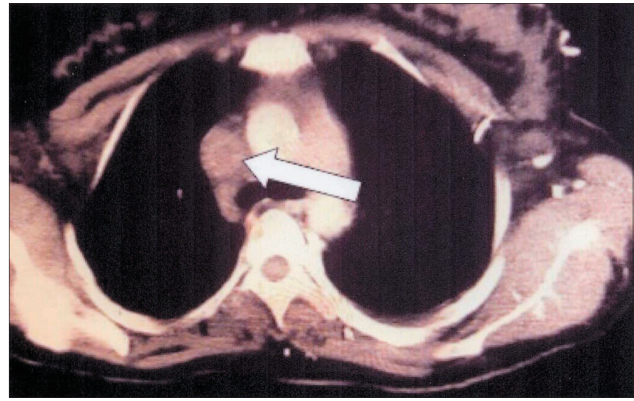
From the Department of Obstetrics and Gynecology (Kale A, Akdeniz), Chest Disease (Akyildiz), and Clinical Biochemistry (Kale E), Dicle University School of Medicine, Diyarbakir, Turkey.

Received on 29th June 2005. Accepted in publication in final form 17th September 2005.

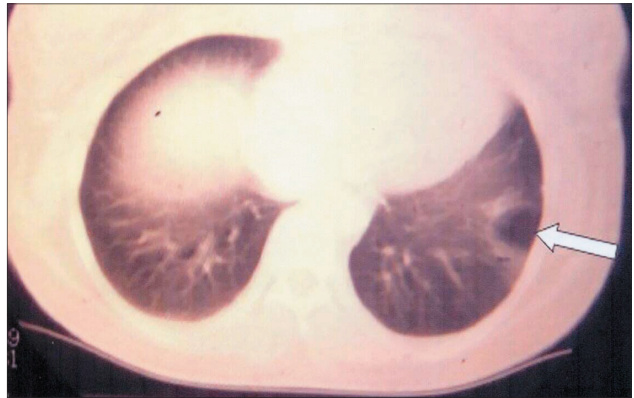
Address correspondence and reprint request to: Dr. Ahmet Kale, Department of Obstetrics and Gynecology, Dicle University School of Medicine, 21280 Diyarbakir, Turkey. Tel. +90 (412) 2488001 Ext. 4756. E-mail: drakale@dicle.edu.tr

The body temperature was 36°C, heart rate was 108 beats/min, respiratory rate was 28 breaths/min, and blood pressure was 90/60 mm Hg. We detected oral aphthous and genital ulcers on the vulva and vagina, erythema nodosum on the anterior of the lower limbs, and swelling of her arms and neck. We found uveitis on ophthalmological examination. She had no uterine contraction, cervical effacement, cervical dilatation and ruptured membranes on obstetric examination. The ultrasound (US) examination showed a 28 week gestational age viable fetus. The patient's hematologic workup demonstrated: erythrocyte sedimentation rates = 45 mm/h (normal range [NR] = 0-7 mm/h), hemoglobin = 10 g/dl (NR = 12.3-15.3 g/dl), hematocrit = 29% (NR = 37.7-53.7%), white blood cell = 12 K/UL (NR = 4.4-11.3%), platelets count = 331 K/UL (NR = 142-424 K/UL), alkaline phosphatase = 68 U/L (reference range 53-141 U/L) ALT = 10 U/L (reference range, 0-41 U/L), AST = 11 U/L (reference range 0-37 U/L). The values of anticardiolipin immunoglobulin G, lupus anticoagulant, protein S, protein C, antithrombin III, fibrinogen, factor V-Leiden, and factor VIII were normal, as were antinuclear antibodies. Her 12 lead electrocardiogram (ECG) showed sinus tachycardia with normal complex size. Chest X-ray showed infiltration in the left lower zone and costophrenic angle was blunt. Doppler echocardiography was in normal ranges. Arterial blood gases revealed severe hypoxia (SpO<sub>2</sub> 86% on 15 l min<sup>-1</sup> oxygen) and elevated A-a gradient: pO<sub>2</sub> 7.5 kPa; pCO<sub>2</sub> 3.84 kPa; pH 7.49 and bicarbonate 23.6 mmol/l. Computed tomography of thorax showed SVC and left brachycephalic vein thrombosis (**Figure 1**). Consolidation was seen which suggested that pulmonary infarct of the left lung inferior lobe laterobasal segment and effusion were in the left pleural space (**Figure 2**). Perfusion scintigraphy showed high probability pulmonary embolism according to the criteria of Prospective Investigation of Pulmonary Embolism Diagnosis.<sup>5</sup> Thus, clinical and radiological findings suggested SVC thrombosis and pulmonary embolism in a patient suffering from Behcet's disease.

Immediately, intravenous heparin treatment was begun with a loading dose of 80 U/kg. This was followed by a continuous infusion of heparin, 18 U/kg/hr. The dose was maintained to produce a 2-fold prolongation of the activated partial thromboplastin time (aPTT). Continuous infusion of heparin treatment was subsequently replaced with subcutaneous low molecular weight heparin (enoxaparin; 0.6 ml twice a day) treatment, as clinical signs and laboratory data improved after 10 days. She was discharged 15 days after onset of disease with subcutaneous low molecular weight heparin [enoxaparin; 0.6 ml twice



**Figure 1** - Computerized tomography scan of the thorax showing superior vena cava thrombosis.



**Figure 2** - Computerized tomography scan of the thorax showing pulmonary infarct.

a day] therapy.<sup>6</sup> Five weeks later, she was readmitted to our clinic with preterm labor. She had uterine contractions (frequency of 5 in 20 minutes), cervical dilatation of 7 cm, cervical effacement of 90% with intact fetal membrane on obstetrics examination, 35 weeks' gestation viable fetus was seen on US examination. A non stress test was reactive. She decided to deliver spontaneously and was admitted to the labor and delivery unit. She was using low molecular weight heparin (enoxaparin; 0.6 ml twice a day) for the last 5 weeks, therefore, she was referred to chest diseases clinic for additional treatment during labor management but additional treatment was not offered. Eight hours after admission to the delivery unit she delivered a healthy boy, weighing 2600 g, 47 cm in length with Apgar score of 8. No complication occur during labor management. Two days after delivery, CT of thorax was performed to evaluate SVC thrombosis and showed similar findings except pleural effusion with the comparison of previous CT of thorax. She was discharged 4 days after delivery without any complication.

**Discussion.** Behcet's disease, had its name from Hulusi Behcet, a Turkish dermatologist who, in 1937, described the classic triad of uveitis, oral and genital ulceration.<sup>1</sup> It is characterized by a multisystem vasculitis of unknown etiology and has been related to the virus, bacteria, genetics, environmental and immunologic factors.<sup>1,4</sup> Vascular involvement has been reported in 7.7–60% of cases; 25% of such lesions affect the venous system and, whereas only 7% affect the arterial system. The majority of patients with vascular involvement (68%) present with both venous and arterial lesions.<sup>7</sup> Vasculitic or thrombotic pathogenesis are both predisposition factors for SVC thrombosis in Behcet's disease.<sup>2,8,9</sup> Thrombotic complications have been reported in approximately 10–45% of patients with Behcet's disease.<sup>7-9</sup> Superior vena cava syndrome due to thrombotic occlusion is a rare manifestation of Behcet disease. Superior vena caval thrombosis may be life threatening due to complications such as pulmonary embolism and hemoptysis.<sup>2,7,8</sup>

Houman et al,<sup>2</sup> analyzed 10 cases with vena cava thrombosis in Behcet disease. Superior vena cava thrombosis in 3 of them. Martinez et al,<sup>8</sup> described 2 cases of the SVC thrombosis as an early manifestation of Behcet disease. Yasuo et al,<sup>9</sup> described a case of pulmonary embolism due to right ventricular thrombus in a Behcet disease. Aleman et al,<sup>10</sup> described severe pulmonary thromboembolism in 3 patients with Behcet disease. Superior vena cava thrombosis was a rare event in Behcet disease but there is no reported data regarding pregnancy complicated with SVC thrombosis in Behcet diseases. Additionally, pulmonary embolism was an unexpected event in Behcet disease. Our case interestingly including SVC thrombosis and pulmonary embolism in a 28 week pregnant woman in Behcet disease.

In addition, we begun to treat our patient with intravenous heparin treatment. All reported studies agree that heparinization is mandatory in patient's with Behcet disease; however, to date, no randomized controlled clinical trial has been performed to

determine the need for anticoagulant treatment and its duration.<sup>1-8</sup> In our case, we administered intravenous heparin for the first 10 days of treatment (to maintain more than 2 times the normal values of the activated partial prothrombin time) and thereafter, we maintained subcutaneous low molecular weight heparin (enoxaparin; 0.6 ml twice a day) until delivery. We successfully managed delivery of the pregnant woman without any complication and additional treatment during the labor period.

## References

1. Sakane T, Takeno M, Suzuki N, Inaba G. Behcet disease. *N Engl J Med* 1999; 341 :1284-1291.
2. Houman H, Lamoum M, Ben Ghorbel I, Khiari-Ben Salah I, Miled M. Vena cava thrombosis in Behcet disease. Analysis of a series of 10 cases. *Ann Med Interne (Paris)* 1999; 150: 587-590.
3. Kuzu MA, Ozaslan C, Koksoy C, Gurler A, Tuzuner A. Vascular involvement in Behcet's disease: 8-year audit. *World J Surg* 1994; 18: 948-953.
4. International Study Group for Behcet Disease. Criteria for diagnosis of Behcet disease. *Lancet* 1990; 335: 1078-1080.
5. PIOPED Investigators. Value of the ventilation/perfusion scan in acute pulmonary embolism: Results of the Prospective Investigation of Pulmonary Embolism Diagnosis [PIOPED]. *JAMA* 1990; 263: 2753-2759.
6. Barbour LA. ACOG practice bulletin. Thromboembolism in pregnancy. *Int J Gynaecol Obstet* 2001; 75: 203-212.
7. Koc Y, Gullu I, Akpek G, Akpolat T, Kansu E, Kiraz S, et al. Vascular involvement in Behcet's disease. *J Rheumatol* 1992; 19: 402-410.
8. Martinez-Orozco F, Poch E, Fernandez-Sola J, Ferrer J, Ingelmo M. Thrombosis of the superior vena cava as an early manifestation of Behcet disease. Presentation of 2 cases. *Rev Clin Esp* 1989; 184: 415-417.
9. Yasuo M, Nagano S, Yazaki Y, Koizumi T, Kitabayashi H, Imamura H, et al. Pulmonary embolism due to right ventricular thrombus in a case of Behcet disease. *Jpn Circ J* 1999; 63: 909-911.
10. Aleman Lorenzo A, Ortega Gonzalez G, Molina Boix M, Salinas Caballero F, Meseguer Frutos MD, Meseguer Arce J, et al. Severe pulmonary thromboembolism in 3 patients with Behcet disease. *Rev Clin Esp* 1985; 176: 423-425.