

## Uterus didelphus

*Ramachandran Muthukrishnan, MD, MCCP,  
George K. Oyakhire, MSc (Edin), FRCOG,  
Umadevi K. Ramachandran, MD.*

Uterus didelphus (di+Gr.delphus-Uterus) is a rare symmetric unobstructed disorder of lateral fusion of Müllerian ducts. We present a 43-year-old female patient, who was referred from a near by hospital, for investigation and management of dysmenorrhea and uterine mass. She had 2 pregnancies before by cesarean section secondary to malpresentation. Local gynecological examination revealed a longitudinal vaginal septum, and her cervix could not be visualized by speculum examination. Routine ultrasound of the abdomen did not reveal the Müllerian anomaly, but showed an enlarged uterus, distorted by a heterogeneous mass measuring 14 x 9 cms, and a cystic lesion in the left ovary. A provisional diagnosis of uterine fibroid was derived, and she underwent a total abdominal hysterectomy, and the specimen was submitted for histopathological examination. On gross examination, the uterus was enlarged and distorted, measuring 13 x 15 x 10 cms. The lower cervical end showed 2 cervical orifices. The left ovary showed features of mature cystic teratoma containing yellowish greasy contents and hair follicles. The cut section of the uterus and cervix showed 2 separate uterine and cervical canals, and large and small fibromas in the larger and smaller uterus (**Figure 1**).

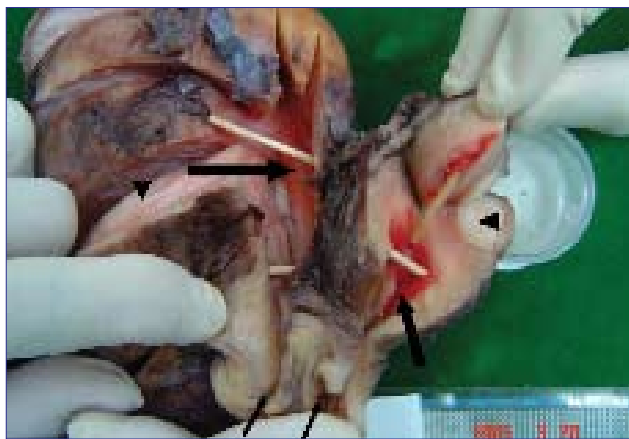
The female reproductive organs consist of external genitalia, gonads, and internal duct system. These 3 components develop embryologically from different

primordia and in close association with urinary system and hindgut. The Müllerian (Paramesonephric) duct system is stimulated to develop preferentially over the Wolffian duct (Mesonephric) system, which regresses in the early female fetal life. The Müllerian duct system attains complete development during organogenesis, and forms the fallopian tubes, uterine corpus, cervix, and a portion of vagina. The Müllerian duct is ordinarily pulled together by the sub peritoneal fibromuscular tissue and the suggested defect in this, is a cause of utero-vaginal malformations. In uterus didelphus, the round ligaments are unusually thick and strong, which might prevent fusion of 2 Müllerian ducts.

Molecular and genetic studies on mice and humans had shown a mutation of Hepatocyte nuclear factor (HNF)-beta, which is expressed during the earlier stages of development of the Wolffian duct, the meso and metanephros, and the Müllerian ducts.<sup>1</sup> As a part of multiple congenital anomalies, the uterus didelphus may occur as a manifestation of an earlier unrecognized single gene disorder or an expansion of VACTERL association.<sup>2</sup> The VACTERL, is a mnemonically useful acronym for a non random association of malformations including V (vertebral anomalies), A (anal atresia), C (cardiac anomalies), TE (tracheoesophageal atresia or fistula), R (renal/urinary anomalies), and L (limb defects).

The American Fertility Society classifies the didelphic uterus as class 111 Müllerian anomaly.<sup>3</sup> Fusion anomalies of various kinds are not uncommon, and may present clinically either in pregnancy or not. Lesser degree of fusion defects is quite common; the cornual parts of the uterus remaining separate giving the organ heart shaped appearance known as the bicornuate uterus. A such minor degree of fusion defects gives lesser amount of signs and symptoms, however, major defects may present as recurrent spontaneous abortion or malpresentation. Complete duplication of uterus and cervix, if associated with clinical problem, may prevent descent of the head in the late pregnancy, or obstruct labor by the non pregnant horn.

Various clinical signs and symptoms of uterus didelphus depends on the age of presentation. Uterus didelphus may be an incidental finding on a routine workup for evaluating multiple congenital anomalies during prenatal, postnatal, or childhood period. The presenting feature in menstruating women is hematocolpos due to the obstruction of one of the uterine horn, cervix, or vagina. During child bearing age, women may present with dysmenorrhea, dyspareunia, low back pain, or urinary stress incontinence. During pregnancy, hypertension due to



**Figure 1** - Showing endometrial cavities (thick arrows), cervical cavities (thin arrows), and fibroids (arrowheads).

altered uterine circulation, and reduced blood supply to the placenta, recurrent spontaneous abortions, preterm births, malpresentation, delayed descent, and engagements during labor are the presenting signs and symptoms. Case reports of simultaneous twin pregnancy in each uterine horn of didelphic uterus, torsion of a gravid uterus didelphus horn of a twin pregnancy, successful consecutive pregnancies in separate horns of a uterus didelphus, simultaneous endometrial cancer in both uteruses are reported in the literature. Diagnostic methods include hysterosalpingogram, ultrasound, and ultrasound with transvaginal transducers. High resolution, real time mechanical sector scanners can improve the diagnostic accuracy. Ultrasonography is the method of choice, for screening patients with uterovaginal anomalies,<sup>4</sup> and diagnosis to be confirmed by hysterosalpingogram in identifying 2 separate cervical canals, or confirmed by identifying a division of endometrial echo along the entire length of the uterine cavity. Magnetic resonance imaging is a useful complementary tool for assessing fetal urogenital anomalies when ultrasonography is inconclusive.<sup>5</sup> Comprehensive evaluation of Müllerian malformation is important to formulate appropriate therapeutic plan such as, resection of vaginal septum, hysteroscopic or trans abdominal metroplasty, depending on the anatomic features of the cervix and uterine cavity.

In an era where congenital disorders of development are screened, and reported more commonly than previously, due to the use of sophisticated equipment, familiarity of these types

of uterine anomaly, and technical expertise of the corrective operative procedures are required for providing complete relief of symptoms and prevention of further sequelae.

*Received 1st February 2006. Accepted for publication in final form 13th May 2006.*

*From the Department of Pathology & Laboratory Services (Muthukrishnan), Department of Obstetrics & Gynecology (Oyakhire), King Abdullah Hospital, Bisha, and the Department of Pathology (Uma Devi), Sapt Al-Alaya Hospital, Sapt Al-Alaya, Kingdom of Saudi Arabia. Address correspondence and reprint requests to: Dr. Ramachandran Muthukrishnan, Department of Pathology & Laboratory Services, King Abdullah Hospital, PO Box 60, Bisha 61922, Kingdom of Saudi Arabia. Tel. +966 (7) 6223333 Ext. 1220. Fax. +966 (7) 6223333. E-mail: muthukrishnan63@yahoo.com.*

### References

1. Bingham C, Ellard S, Cole TR, Jones KE, Allen LI, Goodship JA, et al. Solitary functioning kidney and diverse genital tract malformations associated with hepatocyte nuclear factor-1beta mutations. *Kidney Int* 2002; 61:1243-1251.
2. Evans JA, Greenberg CR. Tibial agenesis with radial ray and cardiovascular defects. *Clin Dysmorphol* 2002; 11:163-169.
3. The American Fertility Society classifications of adnexal adhesions, distal tubal occlusion, tubal occlusion secondary to tubal ligation, tubal pregnancies, mullerian anomalies and intrauterine adhesions. *Fertil Steril* 1988; 49: 944-955.
4. Nicolini V, Bellotti M, Bonazzi B. Can ultrasound be used to screen uterine malformation? *Fertil Steril* 1982; 47: 89.
5. Hayashi S, Sago H, Kashima K, Kitano Y, Kuruda T, Honna T, et al. Prenatal diagnosis of fetal hydrometrocolpos secondary to a cloacal anomaly by magnetic resonance imaging. *Ultrasound Obstet Gynecol* 2005; 26: 577-579.