

Hodgkin's lymphoma with exuberant granulomatous reaction

Jaudah A. Al-Maghrabi, FRCPC, FCAP, Ali S. Sawan, MD, PhD, Hassan D. Kanaan, MD, FCAP.

ABSTRACT

We report a 36-year-old woman, presented with cervical lymphadenopathy and low-grade fever. Two fine needle aspiration cytology and one excisional biopsy were performed in the referral hospital, all showed granulomatous lesions without necrosis. A tentative diagnosis of tuberculosis was made, and she started on antituberculous treatment. However, there was no clinical improvement. She presented to our institution one year after the initial diagnosis, and a new biopsy from the cervical lymph node revealed effacement of the whole node by marked non-necrotizing granulomatous reaction. However, there were scattered large cells with few classic Reed-Sternberg cells between the granulomas. Immunohistochemistry reveals strong reaction of CD15 and CD30, and negative staining for CD45RB, CD45RO, and CD20. These findings confirmed the diagnosis of Hodgkin's lymphoma with remarkable granulomatous reaction that almost masked the malignant component. She was treated with chemotherapy, and she showed an excellent response.

Saudi Med J 2006; Vol. 27 (12): 1905-1907

Granulomatous lymphadenitis is a common presentation in the Kingdom of Saudi Arabia (KSA). The chronic granulomatous inflammation can be necrotizing and non-necrotizing. The most common cause of the former type of inflammation in KSA is tuberculosis (TB). Less likely, the differential diagnosis includes the cat scratch disease, toxoplasmosis, and Kikuchi-Fujimoto disease. However, non-necrotizing granulomatous inflammation in the lymph node, the differential diagnosis includes also TB as well and other diseases such as sarcoidosis. However, we have to be aware that some known malignant conditions are rarely associated with granulomatous inflammation and very rarely in a very extensive manner that may mask the malignant component. We describe a case of an unusual Hodgkin's lymphoma that was associated

with exuberant granulomatous reaction and has been misdiagnosed and treated as TB for one year. The objective of reporting this case is to emphasize the importance of a very careful microscopic evaluation of the lymph nodes with granulomatous reaction searching for any associated tumor. The case also emphasizes the value of immunohistochemistry in highlighting the cell of interest and confirming the diagnoses.

Case Report. A 36-year-old woman presented with widespread cervical lymphadenopathy and low-grade fever. Physical examination revealed no other lymph node involvement. There was no hepatosplenomegaly. The chest x-ray was unremarkable. Investigations for the etiology included 2 fine needle aspiration cytology and

From the Department of Pathology (Al-Maghrabi, Kanaan), King Faisal Specialist Hospital & Research Center and the Department of Pathology (Sawan), King Abdulaziz University Hospital, Jeddah, Kingdom of Saudi Arabia.

Received 7th February 2006. Accepted for publication in final form 21st June 2006.

Address correspondence and reprint request to: Dr. Jaudah A. Al-Maghrabi, Department of Pathology, King Faisal Specialist Hospital & Research Center, PO Box 40047, Jeddah 21499, MBC#: J-10, Kingdom of Saudi Arabia. Tel. +966 (2) 6677777 Ext. 7573. Fax. +966 (2) 6632611. E-mail: jalmaghrabi@kfshrc.edu.sa / jalmaghrabi@hotmail.com

excisional biopsy. All showed granulomatous lesions of cervical lymph nodes without necrosis. A tentative diagnosis of TB was made. She was treated by anti-TB drugs for 6 months. However, there was no clinical improvement. She presented to our institution one year after the initial diagnosis and new cervical lymph was excised. Gross examination revealed a large lymph node that measure 3 x 2.5 x 2 cm. Microscopic examination revealed effacement of the whole node by marked non-necrotizing granulomas. However, between the granulomas there were scattered large cells with a few classic Reed-Sternberg cells (**Figure 1a**). Immunohistochemistry revealed strong reaction to CD15 and CD30 (**Figure 1b**), and negative staining for CD45RB, CD45RO, and CD20, which confirmed the diagnosis of Hodgkin's lymphoma with exuberant granulomatous reaction that almost masked the malignant component. Ziehl-Neelsen stain for acid-fast bacilli was negative as well as the fungal stains (periodic acid-Schiff and Grocott methenamine silver). Computed tomography scan of the abdomen revealed spleen involvement. However, there was no abdominal lymphadenopathy. Subsequently, standard chemotherapy for Hodgkin's lymphoma induced complete clinical remission.

Discussion. Rarely, the diagnosis of a lymphoma may be obscured by the presence of extensive granulomatous lesions. Lymphomas associated with marked granulomatous reaction are well documented in the literature including association with primary presentation or in relapse.¹⁻¹² The occurrence of a sarcoidosis associated with Hodgkin or Non-Hodgkin's lymphoma is an uncommon, but also well-described event.³⁻⁵ Malignant lymphomas and solid

tumors that mimic or are associated with epithelioid granulomas are a dilemma in cytological materials. Khurana et al¹⁰ described 6 malignant cases who presented with granulomatous reaction on cytology. The subsequent histologic findings in 2 cases revealed Hodgkin's disease with the exuberant granulomatous response, and the remaining 3 cases were found to be malignant neoplasms with epithelioid morphologic features and included one example of each diffuse large cell lymphoma, anaplastic carcinoma of the thyroid, and lymphoepithelial carcinoma. Hodgkin's disease associated with diffuse sarcoid-like reactions has been described.^{3,6-9} A prognostic relevance of the granulomatous reaction in Hodgkin's lymphoma is not clear.⁹ Granulomatous reaction after chemotherapy for Hodgkin's disease has been described in the literature.^{11,12} Hodgkin's primary splenic Hodgkin's lymphoma with remarkable granulomatous reaction has also been described.¹ Our patient presented with cervical lymphadenopathy and found to have Hodgkin's lymphoma associated with exuberant granulomatous reaction. This case emphasizes the importance of a very careful microscopic evaluation of the lymph nodes with non-necrotizing granuloma searching for any large atypical cells that may represent a hidden malignant cells that can be easily overlooked. Although, TB is the most common cause of caseating, and one of the common causes of non-caseating granulomatous lymphadenitis in our community, the second condition should be evaluated tremendously to exclude all the possible associated tumors particularly within the context of the low incidence of sarcoidosis in KSA. In patients with suboptimal response to anti tuberculous treatment given for tuberculous lymphadenitis, we recommend

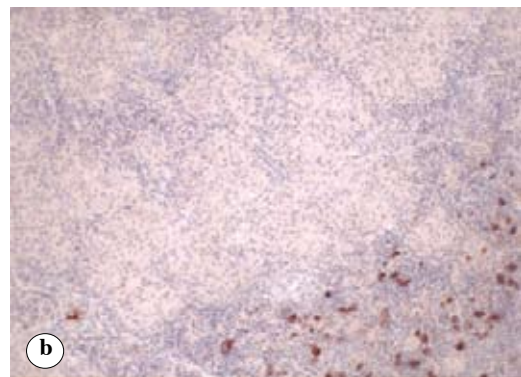
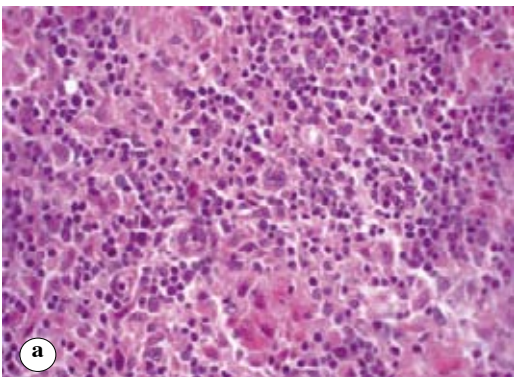


Figure 1 - a) Section from the cervical lymph node reveals non-necrotizing granuloma. Between the granulomas there are scattered large cells with few classic Reed-Sternberg cells (Hematoxylin and eosin stain, original power x400) **b)** Immunohistochemistry highlight the RS and RS variants with strong reaction to CD30 adjacent to numerous non-necrotizing granulomas. (original magnification x400).

a review of the pathological material searching for a possible hidden tumor. This case also emphasizes the value of immunohistochemistry in highlighting the malignant cell of interest and confirming the diagnoses. Tissue culture and molecular studies for TB are helpful to confirm or exclude the diagnosis of TB, particularly with a non-classic morphological appearance.

References

1. Tanaka M, Kanamori H, Fujisawa S, Taguchi J, Nakatani Y, Kawano N, et al. Primary splenic Hodgkin's disease with remarkable granulomatous reaction. *Leuk Lymphoma* 2001; 41: 225-227.
2. Colby TV, Warnke RA. The histology of the initial relapse of Hodgkin's disease. *Cancer* 1980; 45: 289-292.
3. de Hemricourt E, De Boeck K, Hilte F, Abib A, Kockx M, Vandevivere J, et al. Sarcoidosis and sarcoid-like reaction following Hodgkin's disease. Report of two cases. *Mol Imaging Biol* 2003; 5: 15-19.
4. Simsek S, van Leuven F, Bronsveld W, Ooms GH, Groeneveld AB, de Graaff CS. Unusual association of Hodgkin's disease and sarcoidosis. *Neth J Med* 2002; 60: 438-440.
5. Kornacker M, Kraemer A, Leo E, Ho AD. Occurrence of sarcoidosis subsequent to chemotherapy for non-Hodgkin's lymphoma: report of two cases. *Ann Hematol* 2002; 81: 103-105.
6. Huhn D. Pathophysiological aspects of Hodgkin's disease. *Klin Wochenschr* 1979; 57: 481-485.
7. Jensen MK PS, Johansen P. Suspected malignant lymphoma presenting with widespread granulomatous lesions in bones and lymph nodes and responding to combination chemotherapy. *Acta Haematol* 1996; 96: 237-241.
8. Kardon DE TL. A clinicopathologic series of 22 cases of tonsillar granulomas. *Laryngoscope* 2000; 110: 476-481.
9. Macak J, Smyslova O, Krc I, Duskova M, Zapletal P. [Hodgkin's disease with epithelioid granulomatous reaction]. *Cesk Patol* 1998; 34: 89-93.
10. Khurana KK, Stanley MW, Powers CN, Pitman MB. Aspiration cytology of malignant neoplasms associated with granulomas and granuloma-like features: diagnostic dilemmas. *Cancer* 1998; 84: 84-91.
11. Paydas S, Yavuz S, Disel U, Zeren H, Hasturk S, Hanta I, et al. Granulomatous reaction after chemotherapy for Hodgkin's disease. *Leuk Res* 2002; 26: 967-970.
12. Hirschi S, Lange F, Battesti JP, Lebargy F. [Pulmonary sarcoid-like granulomatosis associated with Hodgkin's disease and complicated by bleomycin-induced pulmonary nodules]. *Ann Med Interne (Paris)* 1998; 149: 164-166.