

# Anastomotic esophageal leak due to *Taenia saginata* following esophagectomy for esophageal cancer

Reem M. Baleela, MBBS, Mohamed Y. Huessain, MBBS, Mohamed E. Ahmed, MS, FRCSI.

---

## ABSTRACT

A 50-year-old female with squamous cell carcinoma of the lower third of the esophagus underwent an esophagectomy via laparotomy and right thoracotomy. She developed a major anastomotic leak on the third postoperative day. The chest tube slipped out on the 10th postoperative day and a segment of *Taenia saginata* tapeworm came out through the tube drain site and was extracted. She was given praziquantel tablets treatment; after which the leakage dropped dramatically and ceased completely after one week. Patients scheduled for esophagectomy who experienced recurrent abdominal pain in areas endemic with a tapeworm need to be screened for taeniasis before surgery.

Saudi Med J 2006; Vol. 27 (2): 241-243

---

Esophageal cancer is the most common gastrointestinal malignancy in Sudan with the majority of patients presenting with advanced disease; however, surgical resection remains the best modality for those with relatively early malignancy.<sup>1</sup> This is a major procedure that carries considerable morbidity and mortality. Esophageal anastomotic leak following esophageal resection for malignancy is one of the most serious postoperative complications.<sup>2</sup> *Taenia saginata* is a common intestinal tapeworm infestation in Sudan. It presents usually with abdominal colic and bowel disturbances. The diagnosis is established with stool examination and treatment is medical, using antihelminthic drugs, however, total cure is difficult and repeated regimens are needed. In this report, we present a case of esophageal leakage following esophagectomy due to taeniasis.

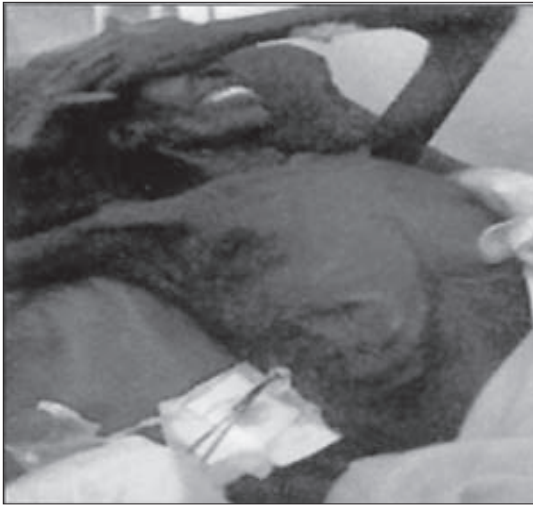**Case Report.** A 50-year-old female was admitted with progressive dysphagia and loss of weight for 8 weeks duration. She had a history of intermittent central colicky abdominal pain for the previous 12 months. This pain was associated with diarrhea and passage of whitish particles. The condition was diagnosed as taeniasis and was treated by several courses of praziquantel (antihelminthic), the dose was 400mg/day for 3 days. The findings of the physical examination revealed an emaciated pale female. Upper gastrointestinal endoscopy showed a tumor on the lower third of the esophagus, and the reported biopsy result was a moderately differentiated squamous cell carcinoma. Partial esophagectomy was carried out through an abdominal and right thoracotomy approach (Lewis-Tanner approach) using interrupted hand sewn 2 layers vicryl 3:0 for anastomosis in the right

---

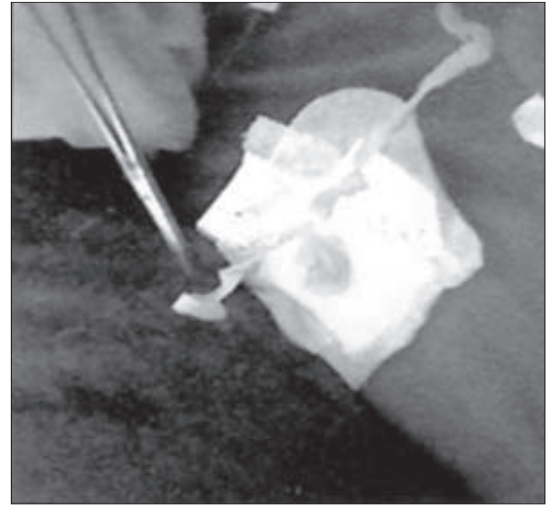
From the Department of Surgery, Faculty of Medicine, University of Khartoum, Khartoum, Sudan.

Received on 29th May 2005. Accepted for publication in final form 3rd October 2005.

Address correspondence and reprint request to: Prof. Mohamed E. Ahmed, Department of Surgery, Faculty of Medicine, PO Box 102, University of Khartoum, Khartoum, Sudan. Fax. +249 (18) 3782663. E-mail: rasheid@usa.net



**Figure 1** - *Taenia saginata* segment protruding from the drain site on the right side of the chest with an artery forceps holding the segment.



**Figure 2** - Close view showing the artery forceps pointing to the site of exit of the worm.

chest. A feeding jejunostomy was carried out using size 14 Folly's catheter tunneled for 2-3 inches under the serosa of the jejunum approximately 25-30 inches proximal to the J-flexure and the balloon inflated with 4-5 ml of saline. Feeding started after 24 hours using a high protein high calorie fluid diet formula (forceval protein). The histopathology confirmed the diagnosis of malignancy without lymph node involvement. On the third postoperative day, the chest tube started draining intestinal fluid between 500-600 mls/24 hours. This was considered as a major anastomotic leak and was managed conservatively. An average of 3-4 liters of forceval protein (2 sachets), in addition, to milk and juice was given 24 hours. Fluid balance was maintained with daily electrolyte balance of serum sodium and potassium. Serum plasma proteins and albumin were carried out every third day. She was put on intravenous third generation cephalosporins and chest physiotherapy was carried out on daily basis. On the 10th postoperative day, the chest tube slipped out, and the leakage continued. This was managed by frequent wound dressing. Two days later she developed central abdominal pain, diarrhea and vomiting. This episode was followed by protrusion of a 5 cm segment of taenia worm (**Figures 1 & 2**) that was extracted using an artery forceps for 7 cm length and the rest slipped back. She was administered with praziquantel using the jejunostomy tube. After one week, the esophageal leak ceased completely and she commenced oral feeding and was discharged home in good condition a week later.

**Discussion.** Esophageal anastomotic leak is a major postoperative complication that carries a high mortality rate of up to 60%.<sup>3</sup> Various biologic and technical factors were incriminated; albumin concentration below 3 gm/dl, neoplastic permeation of the anastomotic cut line and cervical anastomoses.<sup>4</sup> However, the most important predisposing factors are attributed to ischemia of the constructed gastric tube and surgical technique.<sup>5</sup> Ischemia may be suspected intraoperatively with edema, congestion and patchy cyanosis, and this have to be revised immediately. Surgical technique and experience as reflected on the volume of work are important factors in reducing both morbidity and mortality.<sup>6</sup> Early diagnosis of intrathoracic leaks and aggressive drainage is the key to successful management.<sup>7</sup> In our experience, early leak is usually major and indicates a major break in the anastomoses or major necrosis in part of the gastric tube. Early leak starting within the first postoperative week with clinical signs in elderly patients was found to predict fatal outcome.<sup>8</sup> Urschel<sup>5</sup> classified leaks as: 1) an early fulminant that occurs with the first 48 hours and is usually due to necrosis and gangrene of the part and needs surgical intervention, 2) a clinically apparent which usually occurs within a week and is treated conservatively as in this case, and 3) a silent leak that is diagnosed by gastrografin, and this is treated conservatively.<sup>5</sup> The adoption of conservative approach with a tube drainage is the rule in most cases, however, an operative drainage maybe resolved to in a very moribund patient. To manage esophageal leak is

early diagnosis of leaks, patients suspected with early signs of sepsis and increasing pulse rate or pulmonary complications. In those stable patients with persistent leak, the options are limited and exploration is a difficult task when dissecting through fibrous and infected tissues in order to reach the anastomotic defect and try to mobilize healthy margins to seal the gap. A trial of prosthetic placement may be considered as being recently reported.<sup>9</sup> The recurrent abdominal pain experienced by the patient prior to surgery was not considered seriously during this admission and no active steps were taken to diagnose taeniasis and treat by antihelminthic drugs. *Taenia saginata* is a common tapeworm in Sudan. Man is a known sole definitive host and is usually infected with one tapeworm. The worm can reach up to 6 meters length. The eggs are passed in stools when the gravid proglottids drop from the strobila and either rupture in the intestine allowing the eggs to pass in the stools or pass intact. The intermediate host is cattle that swallow the eggs and the larva cysts develop in the tissues. Man is infested when ingesting poorly cooked meat.<sup>10</sup> Surgical complications of intestinal worms are generally very rare. Ascariasis commonly presents with abdominal complications in children. The incidence of surgical complications are directly related to the parasite mucosal interaction, being less with taeniasis and more with ascariasis.<sup>11</sup> Taeniasis was reported to cause small bowel obstruction,<sup>12</sup> and colonic perforation in very rare situations.<sup>13</sup> However, upward migration of the worm to the stomach is unlikely. This is mainly due to the high gastric acidity. However, following esophagogastric resection, bile and pancreatic juice reflux might have changed the environment and allowed such migration. In an experimental work, rats infected with taenia worms led to retard of gastric secretion and hypergastrinemia.<sup>14</sup>

In conclusion, despite the fact that this patient was repeatedly treated for taeniasis, we recommend that patients with recurrent abdominal pain in areas where taeniasis is endemic to be investigated and treated prior to major surgical bowel resection as the leak stopped following praziquantel therapy. Esophageal

anastomosis always needs meticulous attention to the details of sound technique in constructing a well vascularized, carefully handled conduit and early detection and management of anastomotic leaks.

## References

1. Ahmed ME. The surgical management and outcome of esophageal carcinoma in Khartoum. *J R Coll Surg Edinb* 1993; 38: 16-18.
2. Lerut T, Coosemans W, Decker G, De Leyn P, Naftoux P, Van Raemondonck D. Anastomotic complications after esophagectomy. *Dig Surg* 2002; 19: 92-98.
3. Shuvro HR, Anthony AN, Kevin RW, Richard AJM, Peter CS, Christopher MSR, et al. Symptomatic malignant gastrointestinal anastomotic leak: management with covered metallic esophageal stent. *Am J Radiol* 2001; 176: 161-165.
4. Patil PK, Patel SG, Mistry RC, Deshpande RK, Desai PB. Cancer of the esophagus: esophagogastric anastomotic leak - a retrospective study of predisposing factors. *J Surg Oncol* 1992; 49: 163-167.
5. Urschel JD. Esophagectomy anastomotic leaks complicating esophagectomy: A review. *Am J Surg* 1995; 169: 34-40.
6. Begg MG, Cramer LD, Hoskins WJ, Brennan MF. Impact of hospital volume on operative mortality for major cancer surgery. *JAMA* 1998; 280: 1747-1751.
7. Whooley BP, Law S, Andreas A, Murthy SC, Wong J. Critical appraisal of the significance of intrathoracic anastomotic leakage after esophagectomy for cancer. *Am J Surg* 2001; 181: 198-203.
8. Alanezi KU. Mortality secondary to esophageal anastomotic leak. *Ann Thorac Cardiovasc Surg* 2004; 10: 71-75.
9. Mason GR. Esophageal perforations, anastomotic leaks, and strictures: The role of prostheses. *Am J Surg* 2000; 181: 195-197.
10. Zbigniew SP. Cestode infection. In: Kenneth SW, Adel AFM, editors. *Tropical and Geographical Medicine*. 2nd ed. New York: McGraw-Hill, Information Services Company; 2000. p. 490-493.
11. Louw JH. Abdominal complications of *Ascaris Lumbricoides* infection in children. *B J Surg* 1966; 53: 510-521.
12. Bordon LM. Intestinal obstruction due to *Taenia Saginata* infection: a case report. *J Trop Med Hyg* 1992; 95: 352-353.
13. Demiriz M, Gunhan O, Celasun B, Aydin E, Finci R. Colonic perforation caused by taeniasis. *Trop Geogr Med* 1995; 47: 180-182.
14. Oku Y, Yamamouchi T, Matsuda K, Abella JA, Ooi HK, Ohtsubo R, et al. Retarded gastric acid secretion in rats infected with larval taenia taeniaeformis. *Parasitol Res* 2002; 88: 872-873.