

# The treatment of masseter hypertrophy with botulinum toxin type A

*Hazem T. Al-Ahmad, MSc, FDSRCS (Eng), Mansour A. Al-Qudah, FFDRCSI, FDSRCS (Eng).*

## ABSTRACT

Masseter hypertrophy is a benign condition with variable causative factors, such as bruxism, temporomandibular disorders, malocclusion and others, but has an unclear etiology in the majority of cases. Surgical masseteric resection was the conventional method of treatment for the asymmetric swellings over the ramus and angle of the mandible on one or both sides, in addition to the generally unsuccessful treatments of occlusal adjustment, splint therapy, tranquilizers or others. An effective alternative was the local injection of very small doses of botulinum toxin type A into the masseter. The toxin binds permanently to the motor end plate preventing acetylcholine release causing pre-synaptic neuromuscular blockade, the muscle can be selectively weakened and local paralysis is followed by atrophy of the muscle. Four cases with their follow-up are reported. This technique provided a predictable and conservative method of treatment for this type of facial asymmetry.

**Saudi Med J 2006; Vol. 27 (3): 397-400**

Masseter hypertrophy is a benign condition characterized by a unilateral or a bilateral enlargement of the masseter muscles which was first described by Legg in 1880.<sup>1</sup> The highest incidence for this condition is in the second and third decades of life with no gender predilection.<sup>2</sup> The etiology in the majority of cases is unclear. However most cases have a clenching grinding habit,<sup>2</sup> other conditions such as temporomandibular joint disorders, bruxism and malocclusion have also been suspected as causative factors for this condition, other factors include unilateral chewing due to loss of teeth or dental pain, congenital atriovenous fistula, to focal dystonia.<sup>3</sup> The 'work hypertrophy' theory of Gurney<sup>4</sup> explains the asymmetric increase in size of muscles due to their habitual over activity.

Patients frequently complain of a dull aching pain deep within the masseter muscles, which might be associated with temporomandibular joint dysfunction

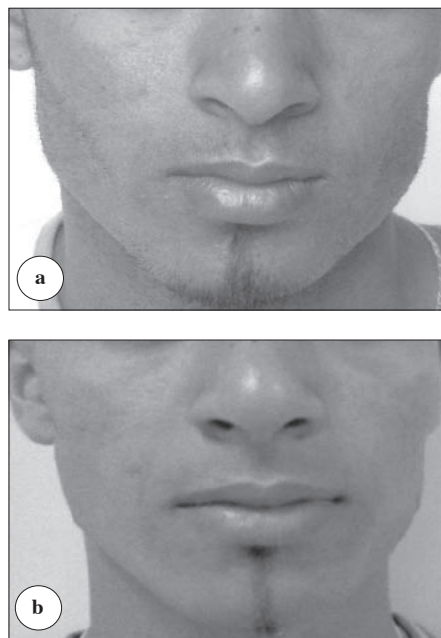
symptoms. Some might present complaining of the enlarged one side or both sides of the face with no history of facial pain. Clinical examination reveals asymmetric swelling/s over the ramus and angle of the mandible on one or both sides, which become more pronounced upon clenching the teeth together. Surgical masseteric resection or reduction of any bony hyperostosis through an intra or extra-oral route is the conventional method of treatment, in addition to the generally unsuccessful treatments of occlusal adjustment, splint therapy, tranquilizers or others.<sup>2</sup>

Botulinum toxin type A (BTA) was first reported for the treatment of masseter muscle hypertrophy in 1994.<sup>2,3</sup> The protein BTA is one of 7 immunologically distinct neurotoxins produced by the anaerobic organism *Clostridium botulinum*. It is a very potent bacterial toxin and is responsible for the clinical infection known as botulism. Local injection of very small doses of the toxin into a muscle produces

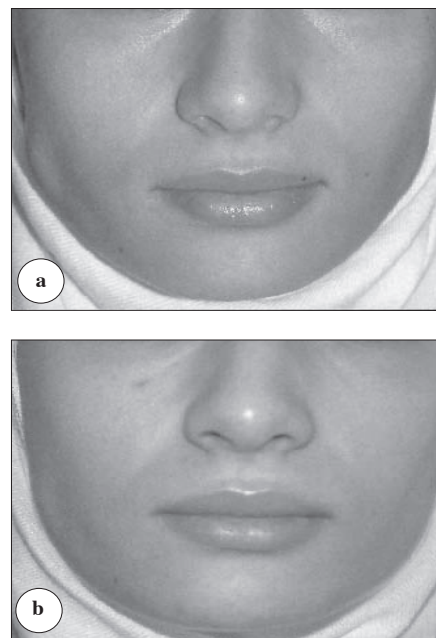
From the Department of Oral and Maxillofacial Surgery (Al-Ahmad), Faculty of Dentistry, University of Jordan and the Department of Oral and Maxillofacial Surgery (Al-Qudah), Faculty of Dentistry, University of Science and Technology, Jordan.

Received 15th August 2005. Accepted for publication in final form 22nd November 2005.

Address correspondence and reprint request to: Dr. Hazem T. Al-Ahmad, Department of Oral and Maxillofacial Surgery, Faculty of Dentistry, University of Jordan, PO Box 11942, Jordan. Tel. +962 (6) 5657028. Fax. +962 (6) 5926002. E-mail: halahmad@hotmail.com



**Figure 1** – A 21-year-old male with bilateral masseteric hypertrophy: a) on presentation. b) 14 months after treatment with botulinum toxin.



**Figure 2** – A 22-year-old female with unilateral masseteric hypertrophy: a) on presentation. b) 12 months after treatment with botulinum toxin.

local paralysis and therefore, individual muscles can be selectively weakened and atrophy of the muscle occurs. The toxin acts by permanently binding to the motor end plate at the neuromuscular junction which prevents the release of acetylcholine from the pre-synaptic vesicles causing pre-synaptic neuromuscular blockade.<sup>2</sup> It appeared that using this method, an effective alternative to the conventional surgical method with far less or no unwanted effects on patients can be considered. Side effects after treatment of masseter hypertrophy with BTA may occur from the deep or misplaced injections of the toxin, temporarily paralyzing nearby facial muscle groups, these effects may be expected to resolve within 2-4 weeks. Possible reactions after treatment are mild and include transient swelling at the injection site, low grade fever, and soreness. Excessive muscle weakness may also occur if the dose of botulinum is too high, but this usually does not last for more than 2 weeks.<sup>5</sup>

In this report, we present 4 cases of masseteric hypertrophy and their medical treatment using the botulinum toxin with a follow up period after treatment. This treatment modality provides patients and clinicians with a non-surgical option to treat this known medical condition.

**Case Report.** Four patients (3 with unilateral and one with bilateral masseter hypertrophy) have been treated with BTA. Clinical examination revealed asymmetric swelling/s over the ramus and angle of the mandible, which become more pronounced upon clenching the teeth together. **Table 1** summarizes the clinical details of these patients. Three patients presented for esthetic reasons and one primarily worried of having a malignant lesion in her facial lump which was excluded by clinical and radiological examination of the masseter muscle. Patients were warned of potential side effects such as facial muscle weakness, pain or bruise at site of injection. All patients declined surgical resection as a treatment option. One patient experienced facial muscle weakness mainly at the right corner of the mouth, which resolved in 3 months.

**Technique.** Botulinum toxin A is available commercially in 2 formulations: Botox (Allergan, Irvine, California) and Dysport (Ipsen Limited, Berkshire, United Kingdom) - active constituent: Clostridium botulinum type A toxin hemagglutinin complex. Botulinum toxin A is sold in 100 unit vials (Botox) or 500 units vials (Dysport) of lyophilized toxin- that must be reconstituted before use. The toxin is prepared for usage by adding 1 ml non-preserved

**Table 1** – Clinical details of 4 patients with unilateral / bilateral masseteric hypertrophy.

Patient	Age	Gender	Side of hypertrophy	Symptoms	Duration of symptoms	Follow up period
1	21	M	BI	S, B	3 years	14 months
2	22	F	UNI	S, B	2 years	12 months
3	19	F	UNI	S	18 months	9 months
4	22	M	UNI	S	2 years	9 months
M - male, F - female, UNI - unilateral, BI - bilateral, S - swelling, B - bruxism						

or preserved sterile saline to the vial, the vial should be gently rolled in the hands to mix the solution as shaking or frothing can inactivate the toxin. The solution is then drawn up in small syringes each containing 0.3 ml or 30 units of Botox / 150 units of Dysport. Syringes were stored with refrigeration for a maximum of 4 weeks. The manufacturers advise the use of the prepared toxin within 4 hours (Botox) or 8 hours (Dysport) of the preparation process, although it has been reported that with refrigeration, the reconstituted solution can be maintained for one month without loss of potency.<sup>6</sup> Stored syringes were as effective as fresh ones in treating our patients. All patients were queried regarding their medical condition, presence of pregnancy or contra-indicating factors. Examination shows the mass to correspond to the outline of the masseter muscle on bimanual palpation and palpation during contraction of muscle. Patients were seated in upright position and asked to clench the teeth. The bulkiest area is palpated and marked, 10-15 units of Botox (patients 1, 3, and 4) or 40-60 of Dysport (patient 2) are deposited percutaneously within the muscle (not superficially) at different sites of greatest muscle bulging (25-30 units of Botox or 100-120 units of Dysport are injected at each session). Patients were asked to return on a weekly basis and injections repeated to reach an acceptable symmetrical lower facial contour.

**Discussion.** In 1880, Legg<sup>1</sup> was the first to describe masseter hypertrophy, thereafter different surgical treatment approaches for the condition were proposed, but surgery was associated with different problems, such as the increased postoperative morbidity, risk to branches of the facial nerve, expected scar formation with the extra oral approach and others. Botulinum toxin offered patients a non-invasive alternative with less or no morbidity. It also provided the operator with more accuracy in judging the facial symmetry required with the ability to repeat BTA injections compared with the difficulty in deciding the correct amount of muscle to resect

surgically. In addition to its use in treating masseteric hypertrophy, BTA has been used in the field of oral and maxillofacial surgery to treat temporomandibular disorders and the associated symptoms. Other conditions such as the recurrent dislocation of the temporomandibular joint, facial nerve injuries, post-traumatic bruxism, zygomatic fractures and mentalis muscle dysfunction,<sup>7,8</sup> were also treated by BTA, therefore, BTA has been widely used in many clinical conditions since 1980 when it was injected into extra-ocular muscles to treat strabismus.<sup>9</sup>

Muscles injected with BTA atrophy and become weak within 2-20 days, recover over 4 months as new nerve terminal axon sprouts form, restoring neuromuscular transmission.<sup>3,2</sup> The masseter muscle atrophy that follows the treatment with BTA remained constant over a follow-up period of 25 months in some studies,<sup>10</sup> however, the effect may be temporary and further intramuscular injections may be required to maintain atrophy.

Many investigators reported using BTA to treat masseteric hypertrophy in a single dose within hours of its reconstitution. Alternatively, the successful storage of BTA with refrigeration enabled us of careful weekly evaluation of muscle mass and further BTA injections in appropriate sites following the muscle atrophy for 4 weeks using one vial. This can also help clinicians to stretch the 6-hour window in using BTA to treat several patients and extend the BTA vial use to 4 weeks.

In conclusion, BTA provides a new option for patients with masseteric hypertrophy who declined surgical treatment; it also provides a predictable and conservative method of treatment for this type of facial asymmetry.

## References

1. Legg JW. Enlargement of the temporal and masseter muscles on both sides. *Trans Pathol Soc Lond* 1880; 31: 361-366.
2. Smyth AG. Botulinum toxin treatment of bilateral masseteric hypertrophy. *Br J Oral Maxillofac Surg* 1994; 32: 29-33.

3. Moore AP, Wood GD. The medical management of masseteric hypertrophy with botulinum toxin type A. *Br J Oral Maxillofac Surg* 1994; 32: 26-28.
4. Gurney CE. Chronic bilateral benign hypertrophy of the masseter muscle. *Am Surg* 1947; 73: 137.
5. Pidcock FS, Wise JM, Christensen JR. Treatment of severe post-traumatic bruxism with botulinum toxin-A: case report. *J Oral Maxillofac Surg* 2002; 60: 115-117.
6. Mantell AM. Dilution, storage, and electromyographic guidance in the use of botulinum toxins. *Dermatol Clin* 2004; 22: 135-136.
7. Nixdorf DR, Heo G, Major PW. Randomized controlled trial of botulinum toxin A for chronic myogenous orofacial pain. *Pain* 2002; 99: 465-473.
8. Clark CL, Baur DA. Management of mentalis muscle dysfunction after advancement genioplasty: a case report. *J Oral Maxillofac Surg* 2004; 62: 611-613.
9. Scott AB. Botulinum toxin injection into extraocular muscles as an alternative to strabismus surgery. *J Pediatr Ophthalmol Strabismus* 1980; 17: 21-25.
10. Von Lindern JJ, Niederhagen B, Appel T, Berge S, Reich RH. Type A botulinum toxin for the treatment of hypertrophy of the masseter and temporal muscles: an alternative treatment. *Plast Reconstr Surg* 2001; 107: 327-332.