

Diagnostic approach and management strategy of childhood stroke

Mustafa A. Salih, Dr Med Sci, FRCPC, Abdel-Galil M. Abdel-Gader, PhD, FRCP.

ABSTRACT

Prompt recognition and early intervention, with pertinent management and medication, may reduce subsequent neurologic deficits in stroke, which constitutes a devastating event in children. This is due to the tasking and demanding consequences including death or residual neurological deficits, which may last for many decades, in over 60% of survivors. Evidence-based treatment for children with stroke is still lacking, reflecting scarcity in baseline epidemiological data on pediatric stroke, the multitude of underlying risk factors, and the ethical and practical challenges incurred in conducting clinical trials. Based on the experience we gained from a combined prospective and retrospective study on childhood stroke (covering 10 years and 7 months and involving a cohort of 104 Saudi children), a diagnostic algorithm, which outlines the approach to a child with suspected stroke/cerebrovascular lesion, was designed. This algorithm might also be of use for managing other children with stroke from the Arabian Peninsula and Middle Eastern Region with similar demographic, socioeconomic, and ethnic backgrounds. Underlying risk factors, which need special attention, include thrombophilia and hypercoagulable states and sickle cell disease (SCD), which contrary to previous studies from Saudi Arabia, were found to constitute a common risk factor with severe manifestations. Other risk factors include infections (especially neurobrucellosis), cardiac diseases, and hypernatremic dehydration. Recognition of an identifiable syndrome or inherited metabolic cause may unravel an underlying cerebrovascular disease. This is particularly important in this region, given the large pool of autosomal recessive diseases and the high rate of consanguinity. In the evaluation of a suspected case of stroke, important imaging modalities include cranial CT, MRI (including diffusion-weighted images), magnetic resonance angiography (MRA), magnetic resonance venography (MRV) and conventional angiography. Transcranial Doppler sonography of the intracranial vessels and Duplex scan of the neck are valuable modalities for detecting large vessel vasculopathy, which occur in SCD, moyamoya syndrome, arterial dissection, and stenosis. Antithrombotic drugs are increasingly being used in the acute phase of childhood ischemic stroke. These include unfractionated heparin, low-molecular-weight heparins, aspirin or warfarin, or both. Specialized stroke care and follow-up are needed for children with stroke, as well as their families.

Saudi Med J 2006; Vol. 27 Supplement 1: S4-S11

Stroke is a tragic event in children with tasking consequences including death, and residual neurological deficits, which last for many decades, in over 60% of survivors, in addition to an adverse socioeconomic impact for the victim, family and the community at large.^{1,4} Prompt recognition and early intervention with medication may reduce subsequent neurologic deficits. Of major concern, is the risk of

recurrence, which affects up to 25% of older infants and children, and is strongly influenced by the stroke mechanism.^{1,2,5,6} The presence of multiple risk factors increases the chances of recurrence.⁷ Evidence based treatment for children with stroke is still lacking, reflecting the paucity in baseline epidemiological data on pediatric stroke, the multitude of etiologies and the ethical as well as the practical challenges incurred in

From the Division of Pediatric Neurology (Salih), Department of Pediatrics, and the Department of Physiology (Abdel-Gader), College of Medicine, King Saud University, Riyadh, Kingdom of Saudi Arabia.

Address correspondence and reprint request to: Prof. Mustafa A. M. Salih, Division of Pediatric Neurology, Department of Pediatrics, College of Medicine, PO Box 2925, Riyadh 11461, Kingdom of Saudi Arabia. Fax: +966 (1) 4679463. E-mail: mustafa@ksu.edu.sa

conducting clinical trials.^{8,9} Several comprehensive reviews have outlined the diagnostic approach and treatment modalities of childhood stroke.¹⁰⁻¹² However, 2 sets of childhood stroke treatment guidelines were recently published, both including the grading of the quality of evidence and the strength of recommendation.^{13,14} Most recently, these guidelines were critically reviewed and compared by deVeber in a Rapid Review article.¹⁵ One of the objectives of a combined prospective and retrospective study¹⁶ on childhood stroke, covering 10 years and 7 months,

was to outline the diagnostic approach and treatment modalities. This study¹⁶ involved a cohort of 104 Saudi children and explored the epidemiology and underlying risk factors. Based on the experience gained from this¹⁶ and other studies,¹⁰ a diagnostic algorithm, which outlines the approach to a child with suspected stroke/cerebrovascular lesion, was designed (**Figure 1**). The algorithm might also be of use for managing other children from the Arabian Peninsula and Middle Eastern Region with similar demographic, socioeconomic, and ethnic backgrounds.

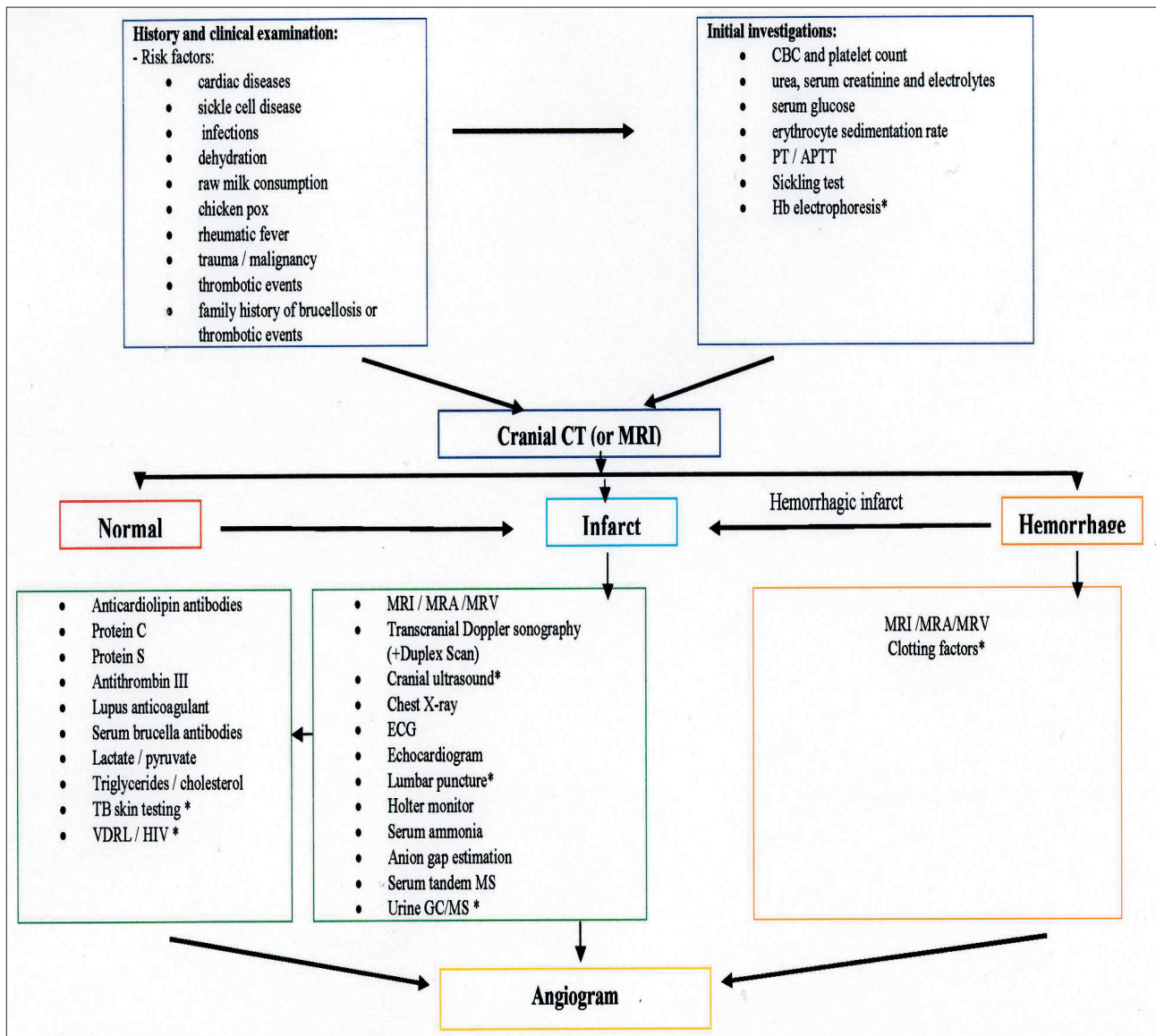


Figure 1 - The algorithm is based on experience obtained from the present study and other more comprehensive experience.¹⁰ The evaluation is curtailed when a likely etiology is detected early in the course of the work-up. *Investigations which are ordered only when clinically appropriate. APTT - activated partial thromboplastin time, CT - computed tomography, CBC - complete blood count, GC/MS - gas chromatography/mass spectrometry, Hb - hemoglobin, HIV - human immunodeficiency virus, MRA - magnetic resonance angiography, MRI - magnetic resonance imaging, MRV - magnetic resonance venography, PT - prothrombin time, TB - tuberculosis, VDRL - Venereal Disease Research Laboratory.

Diagnostic approach to stroke. The diagnostic approach to stroke has 3 main objectives, namely to confirm the presence of cerebrovascular lesion, eliminate other causes of neurological dysfunction that mimic stroke, and identify the cause of stroke. When the presence of a cerebrovascular lesion is confirmed, efforts should be consolidated in identifying factors which are both common and potentially treatable.¹⁰ Often the cause of stroke is suspected from the initial presentation, as with a child already known to have congenital heart or sickle cell diseases. Information gained from history and physical examination has considerable influence on directing the extent of needed investigations. Also, generally, more basic investigations with a high yield and low risk are undertaken first.¹⁰ Initial screening information gained from history and physical examination may identify several risk factors including cardiac diseases, sickle cell disease (SCD), infections, dehydration, vasculitis, and malignancy. Transient ischemic attacks frequently precede acute ischemic insults in children.¹² History of consuming raw milk, or visiting a farm, is of great value as has been shown in our study;¹⁷ since it may point to the diagnosis of neurobrucellosis. A family history of brucellosis is equally important. Other inquiries, which may provide clues to the etiology, include history of a recent infection (particularly chicken pox, in the preceding 12 months), rheumatic fever, and trauma (for a possible cervicocephalic arterial dissection). With regard to thrombophilia and hypercoagulable states, history should be obtained for thrombotic events (stroke, deep venous thrombosis, myocardial infarction, pulmonary embolism) occurring in the patient or any first-degree relative under the age of 55 years.^{18,19} Recognition of an identifiable syndrome may give a clue to an underlying cerebrovascular disease. This is particularly important in the Gulf Region, given the large pool of autosomal recessive diseases as a result of the high rate of consanguinity.²⁰⁻²³ Two of the patients in this study had moyamoya disease associated with autosomal recessively inherited dysmorphic syndromes.²⁴

Initial laboratory investigations should begin with complete blood count (CBC) and blood film examination, which may unravel isoimmune thrombocytopenic purpura (ITP), thrombocytosis, polycythemia, infection, or sickle cells. In this region, sickling test should be ordered at this stage pending the result of hemoglobin electrophoresis.²⁵ A remarkably raised erythrocyte sedimentation rate (ESR) may point towards neurobrucellosis, tuberculosis or malignancy.¹⁷ The prothrombin time (PT) and activated partial thromboplastin time (APTT) may also be needed as screening tests for a coagulation

defect. Serum urea, creatinine and electrolytes are needed to unravel hypernatremic dehydration as being causative, reflect the fluid balance state of the patient, and may also give clues to an underlying renal disease.²⁶ Blood glucose estimation is also important, and will add to the value of the biochemical assays of CSF, if this was carried out at a later stage.

Cranial CT or MRI should be carried out early in the evaluation of a suspected case of cerebrovascular disease, since hemorrhagic stroke, which may require urgent neurosurgical intervention, must be excluded.^{12,25,27} Although CT is often more readily available and takes less time to perform, MRI is more sensitive in detecting small and early infarcts, especially in the posterior fossa, as well as brainstem lesions.^{10,11} The purpose of neuroimaging at this stage is to confirm the occurrence of an acute cerebral ischemic event. It is useful in determining the extent and location of acute cerebral injury, the relative cerebral perfusion and the patency of intracranial and major neck arteries.^{11,18} Compared to CT, the MRI is also more sensitive in detecting hemorrhagic conversion of infarcts and recent modifications have improved its power on the early detection and the specificity of the diagnosis of the infarct.¹¹ These modifications include diffusion-weighted images, perfusion images, and proton magnetic resonance spectroscopic imaging.²⁸ Diffusion-weighted images demonstrate areas of cytotoxic edema and are more sensitive in showing acute ischemic stroke (AIS) in the unmyelinated brain of neonates.¹¹ Perfusion images are required to demonstrate areas of abnormal cerebral blood flow and mean transit time.¹² Other useful images include T1-weighted spin echo of the neck with fat saturation sequence, to exclude arterial dissection.¹² With proper planning, MRA can be carried out during a standard MRI session. It is an extremely helpful non-invasive screening examination for the major cerebral arteries, at the level of the circle of Willis and can readily diagnose moyamoya syndrome. In up to 80% of children with AIS, abnormalities of the cerebral arteries are found, most commonly stenosis or occlusion of the large intracranial arteries which are usually demonstrated by MRA.¹² Nevertheless, MRI/MRA misses abnormalities in medium and smaller arteries, specific signs of vasculitis or dissection and overestimates the degree of stenosis and presence of occlusion.¹¹ However, magnetic resonance venography (MRV) usually demonstrates the occluded sinus in cases of sinovenous thrombosis.¹⁷ Venous sinus thrombosis may be accompanied by hemorrhagic or bland infarction, typically involving the frontal, parietal, or occipital cortex.¹² One of the other advantages of MRI

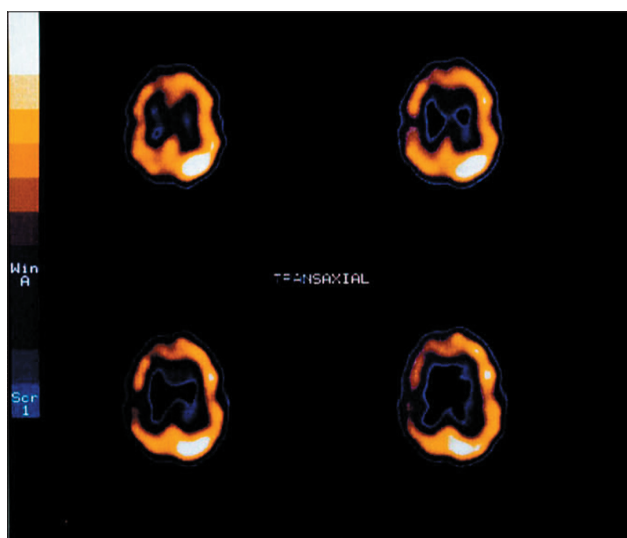


Figure 2 - Axial Single Photon Emission Computed Tomography (SPECT) brain scan of a 9-year-old boy who had hemiconvulsion-hemiplegia-epilepsy (HHE) syndrome showing hypoperfusion of the right cerebral hemisphere.

is that it can exclude alternative pathologies that mimic stroke. This has to be considered within the context of the clinical features and other ancillary investigations. Acute disseminated encephalomyelitis is usually clear on MRI. Epilepsy with post-ictal hemiparesis (Todd's paralysis) may be diagnosed by the EEG in addition to the finding of meningeal enhancement in the side of the brain that triggered the hemiconvulsion. Together with the EEG and single photon emission computerized tomography (SPECT), MRI is extremely useful in the diagnosis of hemiplegia, hemiconvulsion, epilepsy syndrome (**Figure 2**), of whom 6 cases were excluded from this study.^{16,30} In hemiplegic migraine, the EEG usually shows unilateral slow background activity. Neuroimaging with MRI is also helpful in delineating metabolic stroke, secondary to mitochondrial encephalopathy. This was evident in the 3 cases of Leigh syndrome and the case of MELAS included in this study.³¹ One of the neuroimaging features of MELAS is that the infarcts are usually not in a typically vascular distribution. Most recently, and despite its limited spacial coverage, perfusion CT emerged as a new modality, which advantageously competes with perfusion weighted MRI in an emergency setting, since it can easily be performed upon admission.²⁹ Transcranial Doppler (TCD) sonography of the intracranial vessels and Duplex scan of the neck are valuable modalities for detecting large vessel vasculopathy (for example, in sickle cell disease). Stenosing arteriopathies may manifest as dissection, stenosis, occlusion, fibromuscular

dysplasia or moyamoya syndrome.³² They were thought to result from a combination of genetic predisposition and environmental triggering factors such as Varicella-Zoster virus infection.^{12,33} Idiopathic stenoses are transient in most of the cases.³⁴ Extrapolating on the experience gained from the present and other studies,^{24,35} all cases of suspected large vessel vasculopathy require MRI of the neck with fat saturation and MRA (axial 2D time of flight) from the origin of the great vessels to the skull base.¹⁸ Since different management strategies are based on the specific vascular diagnosis, conventional angiography should be considered in situations where MRA and MRV are normal.^{11,12} Additional strong indications include suspicion of arterial dissection or small vessel disease, unexplained recurrences and in children with posterior circulation infarcts.^{36,37} Embolism is the most frequent cause of AIS in children and is secondary to an underlying congenital heart disease in 25% of cases.^{10,11} Acquired heart disease is also a common underlying condition. In most of these children stroke is triggered by additional risk factors such as cardiac procedures (surgery, biopsy, intervention) or other non-cardiac events, such as immobilization.¹² Careful cardiac examination is, therefore, needed in all cases of childhood stroke. Chest x-ray, ECG and precordial echocardiography are essential investigations.^{10,12,38} Ambulatory cardiac rhythm monitoring (Holter monitor) is occasionally useful and transesophageal echocardiography seems to be more sensitive than transthoracic echocardiography in the identification of a patent foramen ovale (PFO) in the older child. In some patients, a "bubble study" may be needed to exclude PFO that allows significant right-to-left shunting of blood and paradoxical emboli.¹⁸ When these former studies fail to suggest a cause for stroke and if the initial neuroimaging scans show no evidence of significantly raised intracranial pressure, a lumbar puncture should be considered. Examination of CSF is mandatory when stroke is associated with fever or signs of specific central nervous system infection.^{10,17} Diseases in which CSF examination is particularly helpful include neurobrucellosis, tuberculous meningitis, syphilis, HIV disease and mild subarachnoid hemorrhage not evident on imaging. As has been ascertained in one of our studies,²⁵ acquired or inherited prothrombotic disorders (due to deficiency of protein C, protein S, antithrombin III or the presence of anticardiolipin antibodies (ACA), or both, were the most common associated risk factors for childhood stroke. These disorders are increasingly being recognized and have recently been associated with stroke recurrence.⁵ Of these, ACA were detected in up to one third of children with stroke, but did not

seem to predict recurrence.⁶ Lupus anticoagulant, rarely found in healthy children, can be found in patients with SLE.¹¹ If the laboratory results indicate a prothrombic disorder, the patient should be screened in a specialized coagulation facility, 3-6 months after the acute stroke for these prothrombic defects.¹² When confirmed, other family members should also be screened as well. Since neurobrucellosis was an identified risk factor for stroke in our study cohort,¹⁷ serum brucella antibodies needs to be included in the investigation protocol. Screening blood by tandem mass spectrometry (MS/MS), and urine with GC/MS will cover several of the metabolic causes of childhood stroke (for example, homocystinuria and organic acidemias) which are relatively common in Saudi Arabia.³⁹ A patient suspected to have one of the mitochondrial disorders (for example, MELAS or Leigh disease) should have lactate and pyruvate levels assayed. Examination of muscle biopsy, including immunohistochemistry and assay of mitochondrial enzyme activities of muscle homogenate, will confirm the diagnosis. Mitochondrial DNA analysis might reveal the specific mitochondrial mutation. However, the assay of mitochondrial enzyme activities and DNA analysis are only carried out in a few specialized laboratories.³¹ Other studies will be guided by the clinical profile of the individual child with stroke.

Treatment modalities. Despite the presence of pertinent guidelines, there has been no randomized clinical trials for the acute treatment of ischemic stroke in children.^{2,10-12} Most recommendations have been adopted from studies in adults, taking into consideration the age-related differences in neurological, vascular and hemostatic systems.¹¹ During the acute phase of stroke, supportive care including fluid management and blood pressure monitoring are essential, since autoregulation of cerebral vasculature is impaired during stroke.⁴⁰ Avoidance of hypoglycemia or hyperglycemia by monitoring serum glucose is mandatory since hypoglycemia worsens the effect of stroke, whereas hyperglycemia increases the size of infarct.⁴¹ Seizures require prompt management and fever should be prevented, since infarct volume and outcome may be related to body temperature.¹² Exchange transfusion is strongly recommended following stroke in children with SCD. However, blood needs to be administered slowly to avoid the possibility of subsequent neurologic deterioration, which has been reported in some cases.⁴²⁻⁴⁴ The recent guidelines issued by the ACCP¹³ recommended therapy with intravenous hydration and exchange transfusion to reduce hemoglobin S (HbS) levels to <30%. Likewise, the Paediatric Stroke Working Group (PSWG) guideline¹⁴

recommended exchange transfusion to lower HbS to <30%. Intracranial pressure monitoring, or surgical decompression, or both, may be required in children who present with coma following large middle cerebral or cerebellar infarcts. During the acute phase, the treatment of hemorrhagic stroke depends on the cause and the condition of the patient. Intraventricular hemorrhage may require drainage, and evacuation of intracranial hematoma and this could be life saving.²⁵

Antithrombotic drugs. Antithrombotic drugs are increasingly being used in the acute phase of childhood AIS. In a recent population-based study,³ unfractionated heparin (UFH), low-molecular-weight heparins (LMWH), aspirin, or Coumadin, or both, have been used in >50% of children with AIS. The feasibility and safety of a prophylactic dose of LMWH and aspirin have recently been documented in an earlier study, which included a cohort of 135 consecutively recruited stroke children (aged 6 months to 18 years).⁴⁵ Although the use of these drugs is associated with the risk of systemic bleeding and hemorrhagic transformation of the infarct, in the acute phase of stroke they demonstrate several potential benefits.¹² These include limitation of thrombus spread, helping in its dissolution, reduction in the size of infarct, promoting intracranial arterial anastomosis, prevention of deep vein thrombosis in immobilized stroke patients, and also the prevention of the early recurrence of embolic events. In children, the most commonly used antiplatelet drugs are aspirin and dipyridamole.⁴⁵⁻⁴⁷ Early recurrence may be reduced if aspirin is administered during the acute phase of stroke in a dose of 3-5 mg/kg/day.¹² The dose can be reduced to 1-3 mg/kg/day during long term prophylaxis. However, recurrence occurs in approximately 10% of patients while on aspirin.¹² Identification of aspirin non-responders can be ascertained through monitoring platelet function using the platelet function analyzer (PFA-100).⁴⁸ The relatively low to medium dose of aspirin rarely causes side-effects and Reye's syndrome has not been described in children on low-dose aspirin prophylaxis.¹² The risk of Reye's syndrome may still be further reduced through giving influenza and varicella vaccines.¹² Dipyridamole, the second most commonly used antiplatelet agent in children, is given at doses of 2-5 mg/kg/day.¹³ It is sometimes combined with aspirin in patients with moyamoya syndrome. Monitoring of this drug, in treated patients, can be achieved by the assay of the adenosine diphosphate-induced platelet aggregation.¹² Unfractionated heparin (UFH) can be used in children with sinovenous thrombosis, arterial dissection, AIS of cardioembolic origin and other conditions with a high risk of early recurrence.¹² Prior

to its administration, cranial CT scan is mandatory, to rule out the possibility of pre-existing intracranial hemorrhage. Platelet count monitoring, in addition to the APTT are, likewise, mandatory since, as in adults, heparin-induced thrombocytopenia type II has also been reported in children.⁴⁹ The target increase in APTT is 1.5 fold compared with baseline values or 0.4-0.7 U/mL antifactor Xa assay.¹² The recommended dosage of UFH is 20 U/kg/hour for children >12 months and 28 U/kg/hour in neonates and infants.¹² A loading dose should be avoided in children with stroke to avoid the risk of hemorrhage.⁵⁰ Low-molecular weight heparin (enoxaparin) proved to be a safe and efficacious alternative to UFH in children with acute, non-hemorrhagic ischemic stroke.⁵¹ Clinical studies demonstrated several advantages of LMWH over standard UFH.¹² The frequency of heparin induced thrombocytopenia and bleeding complication are significantly lower. The need for frequent monitoring, via antifactor Xa assays, is minimized because the pharmacokinetics of LMWH are more predictable than those of UFH. This is important in pediatric patients with poor or non-existent venous access. Also, the relatively long half-life of LMWH allows for once/or twice-daily subcutaneous administration. Enoxaparin (LMWH) can be given subcutaneously in high doses of 1.5 mg/kg (neonates and infants) or 1 mg/kg (children >12 months of age), twice daily. It can also be given once daily as a prophylactic regimen.¹² For twice daily administration, monitoring by antifactor Xa activity is recommended.⁵² There is limited experience on the use of long term oral anticoagulation for the prevention of childhood cerebrovascular accidents.⁵³ Conditions where warfarin is recommended in children with stroke, on case-by-case bases, include congenital or acquired heart disease, arterial dissection and hypercoagulable states.¹² Warfarin therapy is monitored by the use of the PT and the international normalized ratio (INR). For most children on warfarin, an INR of 2-3 is appropriate.¹² However, for those with mechanical heart valves, an INR of 2.5-3.5 is recommended, and INR home monitoring is available.⁵⁴ Routine antithrombotic treatment is not required in neonates with AIS because they have negligible risk of recurrence.¹¹ In older infants and children, long term therapy with aspirin is needed to prevent recurrent transient ischemic attacks (TIAs) which occur in 7-20% of patients.¹¹ On the other hand, Coumadin or LMWH are frequently used and continued for several months in children who depict failure of aspirin in preventing recurrence, and in those with cardiogenic AIS, arterial dissection, high-grade stenosis of a cerebral artery or severe prothrombic conditions.¹² In

such cases, the risk factors of anticoagulant therapy (particularly bleeding) should be weighed against the risk of recurrent thrombotic events.

Thrombolytic agents. The actions of thrombolytic agents are mediated by converting endogenous plasminogen to plasmin. Tissue plasminogen activator (tPA, alteplase), when used during the acute phase, is associated with a 10% risk of hemorrhagic transformation in adults and has to be administered within 3 hours from the onset of stroke.¹² It is noteworthy that only one child in this cohort presented to KKUH within this window of 3 hours. Considering the potentially significant risk of hemorrhage in children with AIS, it is still recommended that the use of thrombolytic agents should only be in the setting of a clinical trial until safety and feasibility data are available.¹² Moreover, neither the PSWG guidelines¹⁴ or ACCP guidelines¹³ recommend the use of alteplase in acute childhood AIS. Further details of acute childhood stroke and maintenance therapy (drugs, dosages and duration) which has been recommended by the ACCP guidelines¹³ and PSWG guidelines¹⁴ are tabulated in the comprehensive Rapid Review of deVeber.¹⁵

Specialized stroke care and follow-up. Given the proven benefit of specialized stroke care in adults, the affected children should be referred, whenever it is feasible, to a tertiary care centre, with expertise in the management of stroke.^{11,55} Designing and implementing a childhood stroke registry that compiles, stores and processes data via the Internet, similar to the experience with congenital heart diseases, will be very useful.⁵⁶ In conjunction with Telemedicine, this can prove to be of great help in the initial management of patients at various district and regional hospitals in Saudi Arabia. The formulation of national networks focused on pediatric stroke research, similar to developments in several countries,^{3,15} will enable the sharing of expertise, pooling of data, the development of therapeutic trials and consensus for the best treatment options. Due to the significant and varied neuropsychiatric impairment, which follows childhood stroke, follow-up visits are better conducted in a multi-disciplinary setting.¹⁸ Rehabilitation programs require physical, occupational, speech, language, cognitive and behavioral therapies. Orthopedic care may also be required.⁵⁷ Education booklets would also be of great help for parents of the affected children helping to deal with the tasking challenges of stroke in a child.¹⁴

Acknowledgment. This work is part of a study on Stroke in Saudi children funded by the Prince Salman Center for Disability Research (Project No. B/M/4/15).⁵⁸

References

1. deVeber G, MacGregor D, Curtis R, Mayank S. Neurological outcome in survivors of childhood arterial ischemic stroke and sinovenous thrombosis. *J Child Neurol* 2000; 15: 316-324.
2. Lynch JK, Hirtz DG, DeVeber G, Nelson KB. Report of the National Institute of Neurological Disorders and Stroke Workshop on Perinatal and Childhood Stroke. *Pediatrics* 2002; 109: 116-123.
3. Max JE, Robin DA, Taylor HG, Yeates KO, Fox PT, Lancaster JL et al. Attention function after childhood stroke. *J Int Neuropsychol Soc* 2004; 10: 976-986.
4. Salih MA, Abdel-Gader AM, Al-Jarallah AA, Kentab AY, Al-Nasser MN. Outcome of stroke in Saudi children. *Saudi Med J* 2006; Vol. 27 Supplement 1: S91-S96.
5. Sebire G, Tabaraki B, Saunders DE, Leroy I, Liesner R, Saint-Martin C et al. Cerebral venous sinus thrombosis in children: risk factors, presentation, diagnosis and outcome. *Brain* 2005; 128: 477-489.
6. Lanthier S, Kirkham FJ, Mitchell LG, Laxer RM, Atenafu E, Male C et al. Increased anticardiolipin antibody IgG titres do not predict recurrent stroke or TIA in children. *Neurology* 2004; 62: 194-200.
7. Lanthier S, Carmant L, David M, Larbrisseau A, deVeber G. Stroke in children: the co-existence of multiple risk factors predicts poor outcome. *Neurology* 2000; 54: 371-378.
8. Nowak-Gottl U, Straeter R, Sebire G, Kirkham F. Antithrombotic drug treatment of pediatric patients with ischemic stroke. *Pediatr Drugs* 2003; 5: 167-175.
9. Kirkham F, Sebire G, Steinlin M, Strater R. Arterial ischemic stroke in children. Review of the literature and strategies for future stroke studies. *Thromb Haemost* 2004; 92: 697-706.
10. Roach ES, Riela AR, editors. Pediatric cerebrovascular disorders. Armonk (NY): Futura Publishing Company Inc; 1995.
11. DeVeber G. Arterial ischemic strokes in infants and children: An overview of current approaches. *Semin Thromb Hemostas* 2003; 29: 567-573.
12. Nowak-Gottl U, Gunther G, Kurnik K, Strater R, Kirkham F. Arterial ischemic stroke in neonates, infants, and children: an overview of underlying conditions, imaging methods and treatment modalities. *Semin Thromb Hemost* 2003; 29: 405-414.
13. Monagle P, Chan A, Massicotte P, Chalmers E, Michelson AD. Antithrombotic therapy in children: the Seventh ACCP Conference on Antithrombotic and Thrombolytic Therapy. *Chest* 2004; 126: 645S-687S.
14. Paediatric Stroke Working Group. Stroke in childhood: clinical guidelines for diagnosis, management and rehabilitation, 2004 (accessed July 3, 2005). Available from: URL: <http://www.vcplondon.ac.uk/pubs/books/childstroke/>.
15. deVeber G. In pursuit of evidence-based treatments for paediatric stroke: the UK and Chest guidelines. *Lancet Neurol* 2005; 4: 432-436.
16. Salih MA, Abdel-Gader AM, Al-Jarallah AA, Kentab AY, Alorainy IA, Hassan HH et al. Stroke in Saudi children. Epidemiology, clinical features and risk factors. *Saudi Med J* 2006; Vol. 27 Supplement 1: S12-S20.
17. Salih MA, Abdel-Gader AM, Al-Jarallah AA, Kentab AY, Gadelrab MO, Alorainy IA et al. Infectious and inflammatory disorders of the circulatory systems as risk factors for stroke in Saudi children. *Saudi Med J* 2006; Vol. 27 Supplement 1: S41-S52.
18. Nestoridi E, Buonanno FS, Jones RM, Krishnamoorthy K, Grant PE, Van Cott EM et al. Arterial ischemic stroke in childhood: the role of plasma-phase risk factors. *Curr Opin Neurol* 2002; 15: 133-138.
19. Kirkham FJ. Is there a genetic basis for pediatric stroke? *Curr Opin Pediatr* 2003; 15: 547-558.
20. al Rajeh S, Bademosi O, Ismail H, Awada A, Dawodu A, al-Freihi H et al. A community survey of neurological disorders in Saudi Arabia: the Thughbah study. *Neuroepidemiology* 1993; 12: 164-178.
21. Salih MA, Mahdi A, al-Rikabi AC, al-Bunyan M, Roberds SL, Anderson RD et al. Clinical and molecular pathological features of childhood autosomal recessive muscular dystrophy in Saudi Arabia. *Dev Med Child Neurol* 1996; 38: 262-270.
22. Salih MA, Mahdi AH, al-Jarallah AA, al-Jarallah AS, al-Saadi M, Hafeez MA. Childhood neuromuscular disorders: a decade's experience in Saudi Arabia. *Ann Trop Pediatr* 1996; 16: 271-280.
23. Salih MAM. Neuromuscular disorders among Arabs. In: Teebi AS, Farag TI, editors. Genetic disorders among Arab populations. New York, Oxford: Oxford University Press; 1997: 126-157.
24. Salih MA, Murshid WR, Al-Salman MM, Abdel-Gader AM, Al-Jarallah AA, Alorainy IA et al. Moyamoya syndrome as a risk factor for stroke in Saudi children. Novel and usual associations. *Saudi Med J* 2006; Vol. 27 Supplement 1: S69-S80.
25. Salih MA, Abdel-Gader AM, Al-Jarallah AA, Kentab AY, Alorainy IA, Hassan HH et al. Hematologic risk factors for stroke in Saudi children. *Saudi Med J* 2006; Vol. 27 Supplement 1: S21-S34.
26. Salih MA, Zahraa JN, Al-Jarallah AA, Alorainy IA, Hassan HH. Stroke from systemic vascular disorders in Saudi children. The devastating role of hypernatremic dehydration. *Saudi Med J* 2006; Vol. 27 Supplement 1: S97-S102.
27. Hoggard N, Wilkinson ID, Girffiths PD. The imaging of ischemic stroke. *Clin Radiol* 2001; 56: 171-183.
28. Gadian DG, Calamante F, Kirkham FJ, Bynevelt M, Johnson CL, Porter DA et al. Diffusion and perfusion magnetic resonance imaging in childhood stroke. *J Child Neurol* 2000; 15: 279-283.
29. Wintermark M, Cotting J, Roulet E, Lepori D, Meuli R, Maeder P et al. Acute brain perfusion disorders in children assessed by quantitative perfusion computed tomography in the emergency setting. *Pediatr Emerg Care* 2005; 21: 149-160.
30. Salih MAM, Kabiraj M, Al-Jarallah AS, El-Desouki M, Othman S, Palkar VA. Hemiconvulsion-hemiplegia-epilepsy syndrome: A clinical, electroencephalographic and neuroradiologic study. *Childs Nerv Syst* 1997; 13: 257-263.
31. Salih MA, Abdel-Gader AM, Zahraa JN, Al-Rayess MM, Alorainy IA, Hassan HH et al. Stroke due to mitochondrial disorders in Saudi children. *Saudi Med J* 2006; Vol. 27 Supplement 1: S81-S90.
32. Ganesan V, Prengler M, McShane MA, Wade A, Kirlleman FJ. Investigation of risk factors in children with arterial ischemic stroke. *Ann Neurol* 2003; 53: 167-173.
33. Askalan R, Laughlin S, Mayank S, Chan A, MacGregor D, Andrew M et al. Chickenpox and stroke in childhood: a study of frequency and causation. *Stroke* 2001; 32: 1257-1262.
34. Chabrier S, Rodesch G, Lasjaunias P, Tardieu M, Landrieu P, Sebire G. Transient cerebral arteriopathy: a disorder recognized by serial angiograms in children with stroke. *J Child Neurol* 1998; 13: 27-32.

35. Andeejani AM, Salih MA, Kolawole T, Gader AM, Malabarey TO, al Damegh S et al. Moyamoya syndrome with unusual angiographic findings and protein C deficiency: review of the literature. *J Neurol Sci* 1998; 159: 11-16.
36. Ganesan V, Kirkham FJ. Recurrence after ischaemic stroke in childhood. *Dev Med Child Neurol* 1998; 40 (Suppl 79): 7.
37. Husson B, Rodesch G, Lajjaunias P, Tardieu M, Sebure G. Magnetic resonance angiography in childhood arterial brain infarcts: a comparative study with contrast-angiography. *Stroke* 2002; 33: 1280-1285.
38. Salih MA, Al-Jarallah AS, Abdel-Gader AM, Al-Jarallah AA, Al-Saadi MM, Kentab AY et al. Cardiac diseases as a risk factor for stroke in Saudi children. *Saudi Med J* 2006; Vol. 27 Supplement 1: S61-S68.
39. Ozand PT, Devol EB, Gascon GG. Neurometabolic diseases at a national referral center. Five years experience at the King Faisal Specialist Hospital and Research Center. *J Child Neurol* 1992; 7 (Suppl): S4-S11.
40. Trescher W. Ischemic stroke syndromes in childhood. *Pediatr Ann* 1992; 21: 374-382.
41. Pulsinelli WA, Jacemicz M, Buchan AM. Stroke and hypoxic-ischemic disorders. In: Johnston MV, MacDonald RL, Young AB, editors. *Principles of Drug Therapy in Neurology*. Philadelphia (PA): FA Davis; 1991. p. 18-160.
42. Ware RE, Zimmerman SA, Schultz WH. Hydroxyurea as an alternative to blood transfusions for the prevention of recurrent stroke in children with sickle cell disease. *Blood* 1999; 94: 3022-3026.
43. Russel MO, Goldberg HI, Hodson A, Kim HC, Halus J, Reivich M et al. Effect of transfusion therapy on arteriographic abnormalities and on recurrence of stroke in sickle cell disease. *Blood* 1984; 63: 162-169.
44. Adams RJ. Lessons from the stroke prevention trial in sickle cell anemia (STOP) study. *J Child Neurol* 2000; 15: 344-349.
45. Strater R, Kurnik K, Heller C, Schobess R, Luigs P, Nowak-Gott U. Aspirin versus low-dose low-molecular-weight heparin: antithrombotic therapy in pediatric ischemic stroke patients: a prospective follow-up study. *Stroke* 2001; 32: 2554-2558.
46. Hathaway WE. Use of antiplatelet agents in pediatric hypercoagulable states. *Am J Dis Child* 1984; 138: 301-304.
47. Le Blanc J, Sett S, Vince D. Antiplatelet therapy in children with left-sided mechanical prosthesis. *Eur J Cardiothorac Surg* 1993; 7: 211-215.
48. Carcao MD, Blanchette VS, Dean JA, He L, Kern MA, Stain AM et al. The platelet function analyzer (PFA-100): a novel in-vitro system for evaluation of primary hemostasis in children. *Br J Haematol* 1998; 101: 70-73
49. Schmutz M, Risch L, Huber AR, Benn A, Fischer JE. Heparin-induced thrombocytopenia-associated thrombosis in pediatric intensive care patients. *Pediatrics* 2002; 109: U69-U72.
50. Andrew M, Marzinotto V, Massicotte P, Blanchette V, Ginsberg J, Brill-Edwards P et al. Heparin therapy in pediatric patients: a prospective cohort study. *Pediatr Res* 1994; 35: 78-83.
51. Burak CR, Bowen MD, Barron TF. The use of enoxaparin in children with acute, nonhemorrhagic ischemic stroke. *Pediatr Neurol* 2003; 29: 295-298.
52. Hofmann S, Knoefler R, Lorenz N, Siegert G, Wendisch J, Muller D et al. Clinical experience with low-molecular-weight heparins in pediatric patients. *Thromb Res* 2001; 103: 345-353.
53. Streif W, Andrew M, Marzinotto V, Massicotte P, Chan AK, Julian JA et al. Analysis of warfarin therapy in pediatric patients: a prospective cohort study of 319 patients. *Blood* 1999; 94: 3007-3014.
54. Massicotte P, Marzinotto V, Vegh P, Adams M, Andrew M. Home monitoring of warfarin therapy in children with a whole blood prothrombin time monitor. *J Pediatr* 1995; 127: 389-394.
55. Launois R, Giroud M, Megnigbeto AC, Le Lay K, Presente G, Mahagne MH et al. Estimating the cost-effectiveness of stroke units in France compared with conventional care. *Stroke* 2004; 35: 770-775.
56. Mitri W, Sandridge AL, Subhani S, Greer W. Design and development of an Internet registry for congenital heart defects. *Teratology* 2002; 65: 78-87.
57. Iannaccone ST. Neurorehabilitation after pediatric stroke. In: Roach ES, Riela AR, editors. *Pediatric cerebrovascular disorders*. Armonk (NY): Futura Publishing Company, Inc.; 1995. p. 335-348.
58. Salih MA, Abdel-Gader AM, Al-Jarallah AA. Study project on stroke in Saudi children. Conclusions, recommendations and acknowledgments. *Saudi Med J* 2006; Vol. 27 Supplement 1: S108-S110.