

## Emergency cerclage

### *A successful challenge despite advanced second trimester cervical dilatation*

*Khaled B. Soliman, MD, Mohamed M. Abbas, ABOG, Nisreen K. Aref, ABOG, Zamfira M. Zada, MD.*

---

#### ABSTRACT

A 22-year-old, primigravida  $\pm$ 20 weeks of gestation presented with abdominal pain. She was diagnosed as a case of advanced cervical incompetence. We carried out an emergency cerclage after 24 hours from her admission, while the cervix was fully dilated with bulging of the membranes and prolapse of both lower limbs in the middle of the vagina. She delivered normally at 38 weeks of gestation with favorable outcomes. We believe that even if miscarriage is inevitable, the so called emergency cerclage might be considered.

Saudi Med J 2006; Vol. 27 (4): 544-546

---

Cervical incompetence has traditionally been defined as “a physical defect in the strength of cervical tissue” that is either congenital or acquired. Cervical incompetence is still one of the most controversial obstetric entities. The treatment of patients with cervical incompetence presenting with advanced cervical changes in the second trimester remains a challenge to every obstetrician. Emergency cerclage operation may be the only hope for prolonging gestation until fetal viability is reached. Many patients require prolonged hospitalization or bed rest and few pregnancies reach full term. Emergency cerclage can be of benefit, although the incidence of complications is high. There is a particularly high rate of infectious complications and attention must be focused on preventing chorioamnionitis to improve the outcome of the procedure.

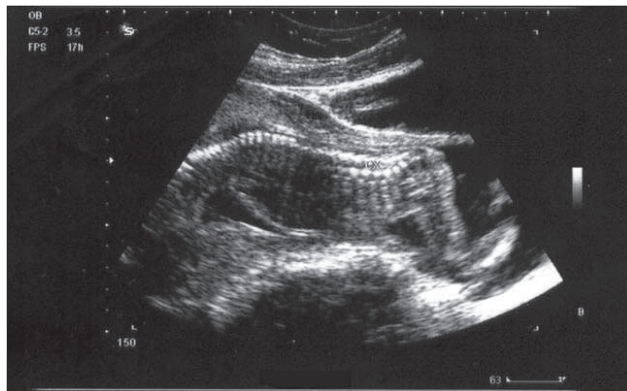
**Case Report.** A 22-year-old primigravida, unbooked, was admitted to our hospital complaining of abdominal pain. On the basis of the last known menstrual period, the gestational age was estimated to be 20 weeks and 2 days gestation. After full history taken, general and abdominal examination, no abnormalities were found. Vaginal examination, sterile speculum and digital examinations revealed that the cervix is dilated by 4-5 cm with bulging of the membranes into the vagina. Abdominal ultrasonography revealed cervical dilatation, bulging of membranes and prolapse of both lower limbs in the middle vagina (**Figures 1 & 2**). She had no fever, no evidence of infection in the midstream specimen of urine and in high vaginal swab. The plan was to keep her under close observation for 24 hours until stabilization of the case. After preterm rupture of

---

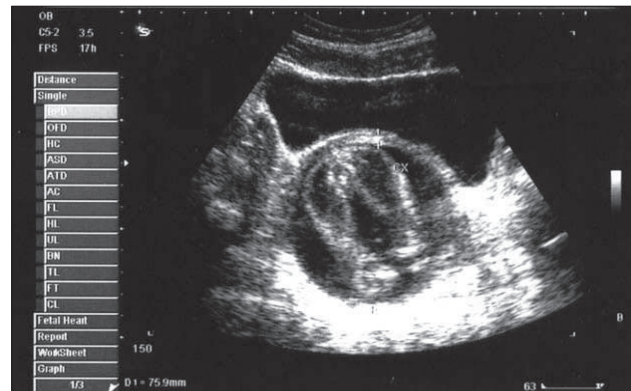From the Department of Obstetrics and Gynecology, King Abdul-Aziz Specialist Hospital, Taif, *Kingdom of Saudi Arabia*.

Received 13th August 2005. Accepted for publication in final form 12th December 2005.

Address correspondence and reprint request to: Dr. Khaled B. Soliman, Department of Obstetrics and Gynecology, King Abdul-Aziz Specialist Hospital, PO Box 10127, Taif, *Kingdom of Saudi Arabia*. Tel. +966 508219100. Fax. +966 (2) 7310801. E-mail: khaled\_b\_s@yahoo.com



**Figure 1** - Abdominal ultrasound showing an advanced cervical dilatation, bulging of membranes with prolapse of both lower limbs in the middle vagina (longitudinal scan).



**Figure 2** - Abdominal ultrasound showing an advanced cervical dilatation, bulging of membranes with prolapse of both lower limbs in the middle vagina (transverse scan).

membranes and chorioamnionitis were ruled out and in the absence of uterine activity, an emergency cervical cerclage was offered to the patient. With the belief that emergency cerclage might improve the outcome of such advanced case of cervical dilatation, the patient agreed, after proper counseling and a written informed consent was obtained. The patient was given indomethacin suppository 100 mg/12 hours to reduce intra-amniotic pressure and to obtain satisfactory tocolysis. After 24 hours, a rescue cerclage was carried out. At surgery, she was placed in a steep Trendelenburg position, and her vulva and vagina were cleaned with antiseptic solution. The assistant used 2 Bresky valves to expose the fetal membranes, and the cervix. The membranes were found to be bulging up to the middle vagina. The edges of the cervix were identified with difficulty, and grasped with atraumatic clamps. The membranes were gently pushed back by the aid of Foley catheter with 35 ml saline injected into the balloon. The balloon was then gently pushed the fetal membranes into the uterine cavity. The cervix was found to be almost fully dilated. A McDonald cervical cerclage was then carried out, using a Mersilene tape, one purse-string suture was inserted as high as possible. The balloon was deflated very slowly. The purse-string suture was tied as the catheter was gently withdrawn from the cervix. After the procedure, the patient started on a regimen consisting of intravenous antibiotics (cefuroxime and metronidazole) for 4 days beside the indomethacin suppository as before. Her postoperative recovery was uneventful. Her routine investigations together with C-reactive protein and screening for vaginal infection were within normal. She was discharged after 10 days of hospitalization in a fair condition and was advised for complete rest. She had regular prenatal visits with serial ultrasonographic examinations. Three weeks

after cerclage, the cervical length was 26 mm long with 6 mm in diameter and the suture was seen at the upper third of the cervix. A weekly scan was scheduled up to 28 weeks of gestation, then biweekly. To our surprise, marked improvement was noticed as the patient had an unremarkable antenatal course until delivery. Dexamethasone was given at 28 weeks of gestation to enhance fetal lung maturity. At 37 weeks and 3 days she was admitted with a complaint of mild abdominal pain which necessitated removal of the cerclage stitch. She was discharged after 24 hours as she had false labor pains and all her fetal well-being tests were normal. One week after, she was admitted again with true labor pains. She delivered a 3300 gm female baby, normal, 9 hours after admission. She was advised for early booking, proper prenatal and the high possibility of doing cervical cerclage in the subsequent pregnancies.

**Discussion.** We report a case of successful cervical cerclage in a nulliparous woman who presented with advanced dilatation of the cervix together with bulging of the membranes and had a uneventful postoperative period together with favorable outcomes. Cervical cerclage is a surgical procedure carried out during pregnancy, which involve suturing the cervix with a purse type stitch to keep the cervix closed. Currently, the available data suggest that cervical cerclage is likely to be of benefit for women considered at very high risk of second trimester miscarriage due to a cervical factor.<sup>1</sup> The management of cervical incompetence in the emergent setting, when cervical change documented on physical examination has already occurred, is more controversial.<sup>2,3</sup> Emergency cerclage in the second trimester is a recognized treatment for cervical dilatation and bulging of membranes. It has been

described as “heroic cerclage” due to its poor success rate.<sup>4</sup> There are few published evidence exists to assist in counseling patients who presented with cervical incompetence in the second trimester, regarding the probability of a desirable outcome after emergent cerclage placement.<sup>5</sup> Infection plays a major role in many cases of miscarriage in the second trimester and therefore screening for infection before insertion of the suture may predict prognosis. Also, in women with bulging membranes, delay in insertion of the suture increases the risk of infection due to increase exposure of the membranes to vaginal bacteria.<sup>4</sup> The most challenging presentation of cervical incompetence, the woman with prolapsed membranes at or beyond a dilated external cervical os, has never been a subject of randomized trial. Reported survival rates following emergency cerclage ranged from 12.5%<sup>6</sup> to 63%.<sup>7</sup> Some authors studied and compared a group of women who had cervical incompetence with bulging of the membranes who were treated with emergency cerclage versus treatment with only a bed rest. A 4-week difference in gestational age at delivery in favor of the emergency cerclage group was found.<sup>8</sup> Multivariable analysis showed that placement of emergent cerclage, when a pregnancy was at least 22 weeks of gestation, increased the likelihood of achieving at least 28 weeks. This is in contrast to previous reports of improved outcomes with emergent cerclage placed at earlier gestational ages (less than 20 weeks).<sup>9,10</sup> Chasen and Silverman.<sup>11</sup> concluded that, the presence of bulging membranes or advanced dilation of the cervix at 20 weeks was associated with lower cerclage-to-delivery intervals as well as a lower chance of reaching 28 weeks of gestation. With the advances of modern neonatal intensive care, fetal survival after 28 weeks of gestation exceeds 90%, and the incidence of severe handicaps and neonatal morbidity decreases dramatically after this point. Consequently, it seems reasonable to consider the achievement of this gestational age as a favorable pregnancy outcome.<sup>5</sup> Knowing the most relevant predictive variable that affects the outcome, is difficult. One outcome variable that has frequently been studied is fetal survival. Although this is clearly an important outcome, the most pressing concern of patients who are candidates for emergent cerclage is not that the intervention may result in pre-viable pregnancy loss, but rather that it may allow extension of the pregnancy only to a peri-viable gestational age, where the neonatal morbidity is high.<sup>12</sup> Katie et al,<sup>4</sup> proposed a theory of possible remodeling of

the cervix secondary to emergency cerclage. They also reported that by replacing the membranes and closing the cervix, the risk of exposure to vaginal bacteria is reduced and therefore the inflammatory-like process which is responsible for cervical ripening and the onset of uterine contraction is also reduced. This allows the cervix to close and lengthen, which suggests that the cervix is a dynamic organ capable of functional reconstruction during pregnancy.

In conclusion, despite the overall success rate of emergent cerclage is very low, a successful outcome sometimes occurs.

**Acknowledgments.** The authors would like to acknowledge with deep gratitude to the patient, and staffs who cared for her. Also, thanks to Ms. Maria Luisa C. David for her valuable secretarial help.

## References

1. Catrin TS, Andrea L, Zarko A, Paula RW. Cervical stitch (cerclage) for preventing pregnancy loss in women. *BMC Pregnancy and Childbirth* 2005; 5: 5.
2. Olatunbosun OA, Al-Nuaim L, Turnell RW. Emergency cerclage compared with bed rest for advanced cervical dilatation in pregnancy. *Int Surg* 1995; 80: 170-174.
3. Aarts JM, Brons JTJ, Bruinse HW. Emergency cerclage: A review. *Obstet Gynecol Surv* 1995; 50: 459-469.
4. Katie MG, Phillip RB, Darryl JM, Andrew HS. Successful cerclage at advanced cervical dilatation in the second trimester. *Br J Obstet Gynecol* 2001;108:1005-1007.
5. Mary CT, Barbara VP, Praveen K, William A. Grobman. Factors associated with success of emergent second trimester cerclage. *Obstet Gynecol* 2003; 101: 565-569.
6. Lipitz S, Libshitz A, Oelsner G, Kokia E, Goldenberg M, Mashiach S, et al. Outcome of second trimester, emergency cervical cerclage in patients with no history of cervical incompetence. *Am J Perinatol* 1996; 13: 419-422.
7. MacDougall J, Siddle N. Emergency cervical cerclage. *Br J Obstet Gynecol* 1991; 98: 1234-1238.
8. Olatunbosun OA, Dyck F. Cervical cerclage operation for a dilated cervix. *Obstet Gynecol* 1981; 57: 166-170.
9. Benifla JL, Goffinet F, Darai E, Proust A, DeCrepay A, Madelenat P. Emergency cervical cerclage after 20 weeks' gestation: A retrospective study of 6 years' practice in 34 cases. *Fetal Diagn Ther* 1997; 12: 274-278.
10. Yip SK, Fung HY, Fung TY. Emergency cervical cerclage: A study between duration of cerclage in situ with gestation at cerclage, herniation of fore-water, and cervical dilation at presentation. *Eur J Obstet Gynecol Reprod Biol* 1998; 78: 63-67.
11. Chasen ST, Silverman NS. Mid-trimester emergent cerclage: a ten year single institution review. *J Perinatol* 1998; 18: 338-342.
12. Schorr SJ, Morales WJ. Obstetric management of incompetent cervix and bulging fetal membranes. *J Reprod Med* 1996; 41: 235-238.