

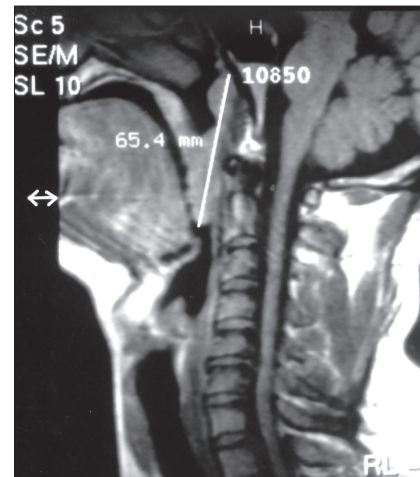
### Benign lateral pharyngeal band pathologies as a cause of sore throat

*Okay Basak, MD, Sema Basak, MD,  
Furuzan K. Doger, MD.*

Sore throat is one of the most common complaints encountered by primary care physicians and most often is caused by viral or bacterial tonsillopharyngitis.<sup>1</sup> The Waldeyer's ring is the most important site of involvement with these infections. The palatine tonsils, nasopharyngeal tonsil, and lingual tonsil constitute the major part of Waldeyer's ring. Although benign hypertrophy and infections are the most encountered and well known clinical conditions, the tubal tonsils and lateral pharyngeal bands rarely are exposed to and considered for these pathologies.<sup>2</sup> In addition, the non-Hodgkin's lymphomas primarily involve the Waldeyer's ring of the head and neck region.<sup>3</sup> Although it is rare, cases of Hodgkin's disease primarily involving the Waldeyer's ring have been reported.<sup>4</sup> We report 3 cases of lateral pharyngeal band pathologies presented with the complaint of sore throat.

**Patient 1.** A 35-year-old man presented with sore throat and difficulty in swallowing for one year. His complaints worsened progressively. He has been smoking for 20 years and has lost weight recently. An Ear, Nose, and Throat specialist of another hospital previously saw him for the same complaints. Pharyngeal examination and the MRI scan showed a soft tissue mass on the right side extending laterally from nasopharynx to hypopharynx (**Figure 1**). A punch biopsy was then taken from the mass and pathological examination was reported as suspicion of Hodgkin's disease. On our examination, he had a mass extending from behind the right posterior tonsillar pillar through the middle line to behind the uvula, with the overlying mucosa of the oropharynx. On flexible nasopharyngolaryngoscopy, the mass was seen to involve the whole lateral pharyngeal band. There was no cervical lymphadenopathy. After consultation with a hematologist, the mass was totally removed through the oral cavity. On microscopic and immunohistochemical examination, it was diagnosed as reactive lymphoid hyperplasia. The patient was free of complaint both postoperatively and on one-year follow.

**Patient 2.** A 62-year-old woman was seen by her family physician with complaints of sore throat, burning in throat, and cough for 3 days duration. Clinical examination revealed a mass of the right



**Figure 1** – Magnetic resonance imaging scan showed a soft tissue mass on the right side extending laterally from the nasopharynx to hypopharynx.

lateral pharyngeal band, which measured 2 cm in diameter, with overlying mucosa of the oropharynx. There were no enlarged cervical nodes. She had a low-grade fever. The palatine tonsils were normal bilaterally. The patient was treated symptomatically with a diagnosis of viral infection and the mass was completely decreased. She was free of complaint on follow-up consultations.

**Patient 3.** A 23-year-old woman complained of sore throat, weakness, muscle pains, and fever. Pharyngeal examination showed erythema of the oropharyngeal mucosa, hypertrophy of, and oxidative membrane on the right lateral pharyngeal band. The palatine tonsils were normal bilaterally. She had a fever of 38.5°C and jugulodigastric lymphadenopathy on the right side. The diagnosis was streptococcal pharyngitis. The patient was completely free of complaints after treatment with oral penicillin of 10 days duration.

All components of Waldeyer's ring are strategically located to perform regional immune functions as these structures are exposed to the antigens of both respiratory and alimentary tract.<sup>2</sup> For this reason, the most common disorder of Waldeyer's ring is enlargement of the adenoids and tonsils so that it leads to recurrent infections and problems in breathing and swallowing. Clinical findings attributed to smaller lymphoid tissues such as lateral pharyngeal bands, tubal tonsils and pharyngeal lymphoid tissues are generally ignored. There was isolated lateral pharyngeal band involvement in our second and third cases.

In the head and neck region, Waldeyer's ring is the most frequently involved extranodal site for Hodgkin's disease.<sup>5</sup> The presenting symptom of non-Hodgkin

## Clinical Notes

lymphoma is usually cervical lymphadenopathy. Our first case was considered as lymphoma on first pathologic evaluation. Lymphoid accumulations in the punch biopsies may be problematic in the differential diagnosis of the lymphomas. Immunohistochemical stains are needed for differential diagnosis. In this case, reactive lymphoid hyperplasia has been diagnosed after immunohistochemical investigation. Unusual hypertrophy in Waldeyer's ring, of course, should first be evaluated for lymphomas, in addition it should be borne in mind that benign hypertrophies can be seen in this region.

Received 2nd October 2005. Accepted for publication in final form 10th January 2006.

From the Department of Family Practice (O. Basak), Department of Otolaryngology (S. Basak) and the Department of Pathology (Doger), Adnan Menderes University, School of Medicine, Aydin, Turkey. Address correspondence and reprint requests to: Dr. Okay Basak, Adnan Menderes Universitesi, Tip Fakultesi, Aile Hekimligi AD, Aydin 09100, Turkey. Tel. +90 (256) 2121850. Fax. +90 (256) 2120146. E-mail: obasak@superonline.com/hsbasak@adu.edu.tr

## References

1. Vincent MT, Celestin N, Hussain AN. Pharyngitis. *Am Fam Physician* 2004; 69: 1465-1470.
2. Hellings P, Jorissen M, Ceuppens JL. The Waldeyer's ring. *Acta Otorhinolaryngol Belg* 2000; 54: 237-241.
3. Yaris N, Kutluk T, Yalcin B, Akyuz C, Buyukpamukcu M. Nasal-paranasal-ornasopharyngeal lymphomas in childhood: the role of staging system on prognosis. *Pediatr Hematol Oncol* 2000; 17: 345-353.
4. Sidhu JS, Rigotti R, Schotanus P. Primary adenoidal Hodgkin's disease. *Int J Surg Pathol* 2000; 8: 241-246.
5. Aloulou S, Farhat H, Bosq J, Vanel D, Ribrag V, Turhan AG, et al. Hodgkin's disease primarily involving the oropharynx: case report and review of the literature. *Hematol J* 2002; 3: 164-167.