

Topical phenytoin ointment increases autograft acceptance in rats

Abla Albsoul-Younes, PhD, Nidal A. Younes, MSc, MD, Darwish H. Badran, MD, PhD.

ABSTRACT

Objective: To examine the effectiveness of topical phenytoin in preserving the skin viability and increasing acceptance rate of autograft.

Method: We conducted this study in the Central Laboratory Animal House of Jordan University of Science and Technology, Irbid, Jordan during the period from September 2004 to June 2005. Forty-two rats were divided into 2 equal groups; full thickness dorsal skin wound (4 cm²) was created in the rats. Twenty-one rats were treated with phenytoin (10% w/w ointment), the other 21 (control) were treated with standard dressing and Vaseline. An autograft was performed one week after treatment. Rats were examined for the presence of healthy granulation tissue, reduction in wound surface dimensions, and time for complete graft attachment.

Results: Phenytoin ointment had significantly increased wound bed viability and the rate of graft acceptance (*p*-

value <0.0001). Twenty rats had successful grafting (10% phenytoin); while only 3 rats out of the 21 control had successful grafts. The mean time to complete graft attachment and hair growth in the grafted skin was 6.6 ± 0.5 days. The mean wound contraction measurements (taken just before grafting) were as follow: control group 59.2 ± 11.6%, and phenytoin group 55.7 ± 9.2, difference in skin contractility was not statistically significant. Skin viability was evident by increased vascularity and granular tissue formation at the edges of the wound.

Conclusion: Phenytoin appears to be an effective method for enhancing the take of the full-thickness skin graft. Further clinical use and evaluation of topical phenytoin ointment in skin grafting are merited.

Saudi Med J 2006; Vol. 27 (7): 962-966

Wound closure by skin graft is the simplest and most versatile method of wound management when direct skin approximation is not possible. Revascularization of skin graft "take" is a complex process that involves a set of cellular, physiological, and molecular events working to restore the blood supply and functional integrity to the donor skin. Development of granulation tissue in the wound is an important indicator for skin graft treatment. Granulation tissue has a high level of vascularity

resulting from abundance of new capillary formation. This degree of vascularity enables granulation tissue to accept and support skin grafts.¹⁻³

Phenytoin an anticonvulsant used in the management of epilepsy has been shown to have wound healing properties. Phenytoin healing properties have been attributed to its effect on many components in skin and skin growth. It has the ability to stimulate fibroblast proliferation, inhibit collagenase activity,

From the Department of Clinical Pharmacy (Albsoul-Younes), Jordan University of Science and Technology, Irbid, Department of Surgery (Younes), and the Department of Anatomy (Badran), College of Medicine, Jordan University, Amman, *Jordan*.

Received 14th February 2006. Accepted for publication in final form 16th April 2006.

Address correspondence and reprint request to: Dr. Abla Albsoul-Younes, Department of Clinical Pharmacy, Faculty of Pharmacy, Jordan University of Science and Technology, PO Box 3030, Irbid, 22110, *Jordan*. Tel. +962 (79) 5652216. Fax. +962 (2) 7095019. E-mail: ablabsou@just.edu.jo

promote collagen disposition, enhance granulation tissue formation, decrease bacterial contamination, reduce wound exudates formation, and most recently up-regulating the growth factors receptors.⁴⁻¹⁴

Despite the fact that phenytoin effect on wound healing has been widely tested, it was always used in the form of a powder, or a suspension. To our knowledge, it was not tested as an ointment, and its effect on the rate graft acceptance has not been evaluated. We compared the effect of phenytoin ointment applied to a full thickness wound versus the use of a standard normal saline dressing and Vaseline ointment on the rate of full thickness skin autograft take in rats.

Methods. Phenytoin powder British pharmacopoeia (BP) was obtained from Well Worth Medicines, India. It was triturated into white petrolatum BP (Vaseline, Al-Eman for cosmetic products, Jordan) at a ratio of 10% (w/w). Agents used for anesthesia were: Ketamine HCL USP (Hikma, Pharmaceuticals, Jordan), and Xylazine (Xxla Inj, Chemicals and pharmaceuticals Adwia, Egypt). This study was conducted during the period from September 2004 to June 2005, in the Central Laboratory Animal House of Jordan University of Science and Technology, Irbid, Jordan. Forty-two adult Wistar albino rats were divided into 2 equal groups. The first group weighing 320 - 450 g, mean weight 373.1 ± 38.3 grams (mean \pm SD) of both sexes was designated as the control and the second weighing 295 - 440 g, mean weight 357 ± 36.6 grams as the study group. Rats were housed individually in standard metal cages and provided with food and water and libitum.

Rats were anesthetized using intramuscular injection of ketamine (35 mg/Kg) and xylazine (7 mg/Kg). The dorsal regions were shaved with electric clipper and the surgical area disinfected with 70% alcohol. A predetermined area of 2 cm \times 2 cm (4 cm²) full thickness skin was excised. Excised skin was aseptically placed in dextrose saline water in the refrigerator (4-8°C) for a week to be autografted to the rats. Excised wounds were irrigated using normal saline solution, followed by administration of a thin layer of ointment (drug or control). The ointments (phenytoin ointment or just Vaseline) were applied twice daily to the wound area. Seven days post excision, the recipient wound was cleaned with normal saline and the superficial crust was removed. The excised skin was autografted to the exposed wound area. Due to wound contraction, one third of a slightly meshed skin taken originally was used. The graft was fixed using 4 stitches at the corners of the graft. Control drug or phenytoin was applied twice daily

for another 7-10 days post grafting. The progressive changes in wound area were monitored visually for wound dryness and appearance of granulation tissue; digital pictures were taken just before grafting and 6-7 days post grafting. Wound margin changes were measured for monitoring wound contraction. Wound contraction was expressed as percentage reduction of original wound size.

Measured parameters data from both groups were analyzed using the student's unpaired t-test through a computerized program Statistical Package for Social Science. A *p* value of <0.05 was considered statistically significant. The percentage wound contraction was calculated as percentage of the corresponding 0 days original wound area (cm²).

Results. Forty-two rats were used in this experiment. A full thickness dorsal skin wound (4 cm²) was created, and 21 rats were treated with standard dressing and phenytoin (10% w/w ointment), the other 21 (control) were treated with standard dressing and Vaseline. An autograft was performed one week after treatment. Rats were examined for the presence of healthy granulation tissue, reduction in wound surface dimensions, and time for complete graft attachment.

Treating the 4 cm² wounded areas with 10% phenytoin ointment increases the amount of granulation tissue formation. The rate of autograft acceptance was much higher in the phenytoin treated group as compared to the control group. In the phenytoin treated group, 20 rats had successful graft attachment, with a success rate of approximately 95%. Only 3 grafts were accepted in the control group. The Difference in skin graft acceptance was significant (*p*<0.0001). A summary of the results is shown in **Table 1**. The control group wounds started to dry out from day 2 post skin incision. Seven days post incision,

Table 1 - Summary of 42 rats with dorsal full thickness wound treated with Vaseline or phenytoin 10% ointment prior to skin grafting.

Measured parameters	Control (Vaseline)	Phenytoin (0% ointment)
Number of rats	21	21
Weight of rats (g)	373.1 ± 38.3	357 ± 36.6
Percent wound contraction*	$59.2 \pm 11.6\%$	$55.7 \pm 9.2\%$
Mean time to complete graft attachment and hair growth	6.6 ± 0.5 days	6.6 ± 0.5 days
Successful grafts number (%)	3 (14)	20 (95)**

*Wound contraction expressed as percentage reduction of original wound size.

**Difference in skin graft acceptance was significant *p*-value <0.0001.

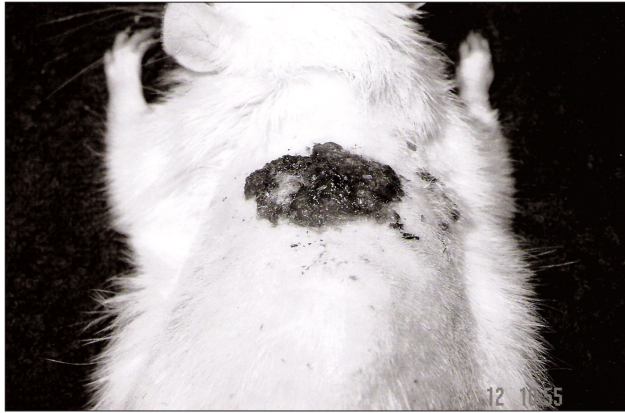


Figure 1 - At 7 days after wounding, the Vaseline (control) treated wound showing prominent contraction and epithelialization covered by dry scar.

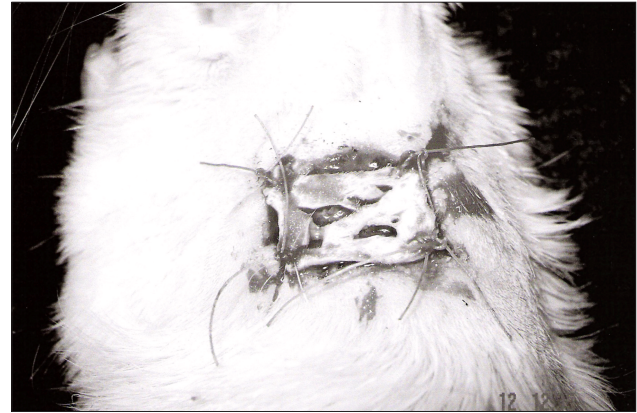


Figure 3 - Application of full thickness skin graft to the recipient site and fixation with absorbable sutures.

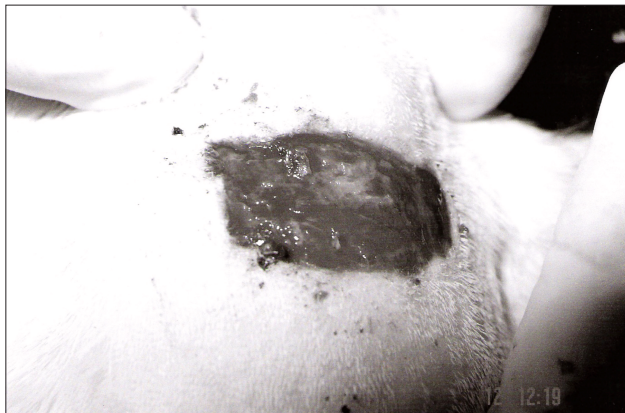


Figure 2 - At 7 days after wounding, the phenytoin treated wound showing prominent granulation tissue formation and less scarring.

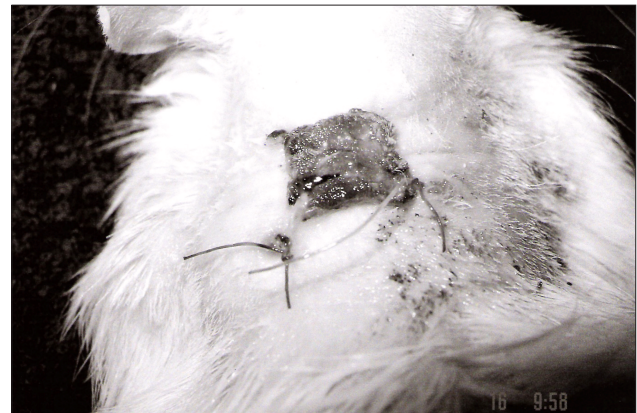

Figure 4 - The rat wound, 7 days after grafting, showing the donor skin fixed and hyperemic reflecting complete take in the phenytoin treated wound.

most of them had already dried and scarred. Whereas the phenytoin group showed prominent granulation tissue formation, **Figures 1 & 2**. The phenytoin treated group had more granulation tissue, and higher level of vascularity, when compared with the control group (**Figure 2**). Healthy granulation tissue appeared within 2-3 days in all phenytoin treated group, while it took up to 6-7 days in the control group. Most of the skin grafts of the control group did not attach well as the wound bed underneath was dry, and the grafts dried out and peeled-off in 3-4 days (18 out of 21). The graft acceptance was declared as successful when the grafted skin attached completely and epithelialization was apparent at the inspected edges. Some successfully grafted skins showed hair growth. The mean \pm SD time to complete graft attachment was in 6-7 days (6.6 ± 0.5 days). **Figures 3 & 4** show the skin graft at 0-7 days respectively post grafting in a phenytoin treated wound.

In our experiment, topical phenytoin therapy did not have a significant effect on wound contraction; actually the effect on contraction was statistically insignificant. The phenytoin treated group mean percent wound contraction was $55.7 \pm 9.2\%$ while the control group mean percent contraction was $59.2 \pm 11.6\%$.

Discussion. Skin grafting is defined as the transfer of free unattached donor skin to noncontiguous recipient area. Skin graft could be partial thickness, full thickness, or cultured graft; any of the previous could be an autograft or allograft. The full thickness autograft are preferable when cosmetic appearance of the wound is of great concern, as this method allows less wound contraction, less color and texture changes in the grafted skin.¹⁵ In this skin grafting model, full thickness slightly meshed skin grafts were used. The grafted skin was accepted in most of the wound

treated with 10% phenytoin ointment. The success of a skin grafting depends mainly on the recipient site and its ability to produce angiogenic factors, and the amount of supply available under the grafted skin.¹⁶ Biologically, 3 stages have been recognized in the process of grafting; inhibition phase (graft nourished and glued by exudates from underneath), inosculation phase (existing vessels attachment) and the neovascularity phase (formation of new vascular beds). The full circulation is usually restored in the fourth through the seventh day of grafting.¹⁷ Phenytoin is known for its effect in stimulation of granulation tissue formation.^{4,6} The exact mechanism is not well understood however, several mechanisms have been proposed; such as its effect on increasing fibroblast proliferation, increasing collagen content and maturation in the healing tissue, decreasing collagenase activity, inhibition of the release of lysosomal and cytoplasmic enzymes,^{7,18,19} decreasing the catabolic effect of cortisol,²⁰ having an anti-edema and anti-inflammatory actions,²¹ and modulation of prostaglandin's metabolism in the wound.²² More recently, phenytoin was shown to accelerates the autocrine and paracrine activity of growth factors by up-regulating the related receptors.¹⁴ Granulation tissue formation was visually detected 2-3 days post incision formation. Our results are consistent with another study that looked into effect of topical phenytoin on granulation tissue formation.²³

Phenytoin powder was used for topical application in almost all of the studies concerned with wound healing. Using phenytoin in a powder form is not an ideal way to enhance healing because of the dry nature of the powder and its direct application does not provide a moist healing environment necessary for the development of granulation tissue. The importance of moisture for granulation tissue formation is well recognized.²⁴ An ointment form of phenytoin using petrolatum (Vaseline) at a ratio of 10% (w/w) would provide a good coverage of the wound and maintains its inherent moisture and thus stimulating granulation tissue formation. It would up-regulate growth factors expression¹⁴ and allow tissues to be more viable for the process of grafting.

This full thickness skin graft provides a standardized model for the study of graft take in animals, as the graft can be practically preserved and maintained for a week during which time the local management of the wound is being conducted. The 10% Phenytoin appears to be an effective, low-cost, and safe method for enhancing the take of the full-thickness skin graft, comparing very favorably with other reported healing promoting agents. We found that recipient wound treatment with local phenytoin ointment, increased

the rate of autograft take compared to a standard dressing. Increasing the take of skin graft effect is possibly related to phenytoin's granulation tissue formation.

Acknowledgments. This work was supported in part by Deanship of Scientific Research at Jordan University of Science and Technology (JUST), and Hamdi Mango Center for Scientific Research, their support is gratefully acknowledged. Further thanks are due to the staff of Central Laboratory Animal House, at JUST.

References

1. Hom DB. The wound healing response to grafted tissues. *Otolaryngol Clin North Am* 1994; 27: 13-24.
2. Snyder MC, Moore GF, Johnson PJ. The use of full-thickness skin grafts for the skin-abutment interface around bone-anchored hearing aids. *Otol Neurotol* 2003; 24: 255-258.
3. Ratner D. Skin grafting. *Semin Cutan Med Surg* 2003; 22: 295-305.
4. Shapiro M. Acceleration of gingival wound healing in non-epileptic patients receiving diphenylhydantoin sodium (Dilantin, Epanutin). *Exp Med Surg* 1958; 16: 41-53.
5. Swann WP, Swenson HM, Shafer WG. Effects of dilantin on the repair of gingival wounds. *J Periodontol* 1975; 46: 302-305.
6. DaCosta ML, Regan MC, al Sader M, Leader M, Bouchier-Hayes D. Diphenylhydantoin sodium promotes early and marked angiogenesis and results in increased collagen deposition and tensile strength in healing wounds. *Surgery* 1998; 123: 287-293.
7. Matsu A, Yajima T. Cell proliferation and collagen fibrinogenesis of cultured fibroblasts. *Jpn J Oral Biol* 1985; 27: 56-63.
8. Pendse AK, Sharma A, Sodani A, Hada S. Topical phenytoin in wound healing. *Int J Dermatol* 1993; 32: 214-217.
9. El Zayat SG. Preliminary experience with topical phenytoin in wound healing in a war zone. *Mil Med* 1989; 154:178-180.
10. Lodha SC, Lohiya ML, Vyas MC, Bhandari S, Goyal RR, Harsh MK. Role of phenytoin in healing of large abscess cavities. *Br J Surg* 1991; 78: 105-108.
11. Dill RE, Iacopino AM. Myofibroblasts in phenytoin-induced hyperplastic connective tissue in the rat and in human gingival overgrowth. *J Periodontol* 1997; 68: 375-380.
12. Anstead GM, Hart LM, Sunahara JF, Liter ME. Phenytoin in wound healing. *Ann Pharmacother* 1996; 30: 768-775.
13. Habibipour S, Oswald TM, Zhang F, Joshi P, Zhou XC, Dorsett-Martin W, et al . Effect of sodium diphenylhydantoin on skin wound healing in rats. *Plast Reconstr Surg* 2003; 112: 1620-1627.
14. Swamy SM, Tan P, Zhu YZ, Lu J, Achuth HN, Moochhala S. Role of phenytoin in wound healing: microarray analysis of early transcriptional responses in human dermal fibroblasts. *Dermatol Online J* 2004; 10: 5.
15. Mellette JR Jr, Swinehart JM. Cartilage removal prior to skin grafting in the triangular fossa, antihelix, and concha of the ear. *J Dermatol Surg Oncol* 1990; 16: 1102-1105.

16. O'Donoghue MN, Zarem HA. Stimulation of neovascularization — comparative efficacy of fresh and preserved skin grafts. *Plast Reconstr Surg* 1971; 48: 474-478.
17. Converse JM, Smahel J, Ballantyne DL Jr, Harper AD. Inoculation of vessels of skin graft and host bed: a fortuitous encounter. *Br J Plast Surg* 1975; 28: 274-282.
18. Bergenholtz A, Hanstrom L. The effect of diphenylhydantoin upon the biosynthesis and degradation of collagen in cat palatal mucosa in organ culture. *Biochemical Pharmacology* 1979; 28: 2653-2659.
19. Goultchin J, Shoshaan S. Inhibition of collagen breakdown by diphenylhydantoin. *Biochimica et Biophysica Acta* 1980; 631: 188-191.
20. Houk JC, Jacob RA. Connective tissue. VII factors inhibiting the dermal chemical response to cortisol. *Proc Soc Exp Biol Med* 1963; 113: 692.
21. Bremer AM, Yamada K, West CR. Ischemic cerebral edema in primates: effects of acetazolamide, phenytoin, sorbitol, dexamethasone, and methylprednisolone on brain water and electrolytes. *Neurosurgery* 1980; 6: 149-154.
22. Katsumata M, Gupta C, Baker MK, Sussdorf CE, Goldman AS. Diphenylhydantoin: an alternative ligand of a glucocorticoid receptor affecting prostaglandin generation in A/J mice. *Science* 1982; 218: 1313-1315.
23. Rhodes RS, Heyneman CA, Culbertson VL, Wilson SE, Phatak HM. Topical phenytoin treatment of stage II decubitus ulcers in the elderly. *Ann Pharmacother* 2001; 35: 675-681.
24. Brem H, Lyder C. Protocol for the successful treatment of pressure ulcers. *Am J Surg* 2004; 188 (1A Suppl): 9-17.