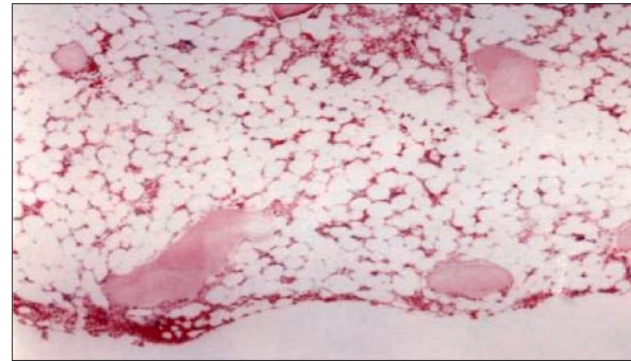


### Successful coronary artery bypass grafting in a patient with aplastic anemia and Sjogren syndrome

*Ismail Koramaz, MD, Mehmet Sonmez, MD,  
Zerrin Pulathan, MD, Umit Çobanoğlu, MD,  
Suleyman Sami Karti, MD.*

**A**plastic anemia (AA) is a disorder causing pancytopenia with a hypocellular bone marrow. Severe forms of the disease need treatment with immunosuppressive drugs or allogeneic bone marrow transplantation.<sup>1</sup> Patients with non-severe AA may live for many years with supportive treatment. However, when surgery is needed, especially open-heart surgery, it is a major problem in such patients as they are prone to hemorrhage and infection. Sjögren's syndrome (SS) is a chronic autoimmune disease characterized by lymphocytic infiltration of the lacrimal and salivary glands and presents with xerostomia and xerophthalmia. It may be primary or secondary to other connective tissue diseases, such as systemic lupus erythematosus, rheumatoid arthritis, scleroderma or polymyositis. The association of SS with AA has been rarely reported.<sup>2</sup> Herein, we describe a patient with AA and SS who successfully underwent coronary artery bypass graft (CABG) surgery.

A 63-year-old man was admitted to our hospital with xerostomia, xerophthalmia and arthralgia of 4 months duration. On his physical examination, he had bilateral enlarged cervical lymph nodes, and Schirmer's test was positive (right eye 2.5 mm, left eye 1.5 mm after 10 minutes). Blood count showed pancytopenia with hemoglobin (Hb) of 10.1 gr/dl [normal range (NR)=12-17 gr/dl]; platelets  $98 \times 10^9/l$  (NR=130-400  $\times 10^9/l$ ); mean corpuscular volume 111.5 fl; leukocytes  $2.7 \times 10^9/l$  (NR=4.8-10.8  $\times 10^9/l$ ) composed of 51% neutrophils (NR=43-65%), 4% eosinophils (NR=0.9-2.9%), 43% lymphocytes (NR=20.5-45.5%), 2% monocytes (NR=5.5-11.7%). Bone marrow aspirate and trephine biopsy examination revealed a hypoplastic bone marrow with 10% cellularity (NR=15-100%) (**Figure 1**). Rheumatoid factor and anti-DNA antibody tests were negative. Thyroid stimulating hormone and free T4 were normal. Protein electrophoresis was normal. Serological tests for HIV, Epstein-Barr virus, cytomegalovirus, hepatitis types B and C were negative. The thorax and abdominal tomography showed no lymphadenopathy or organomegaly. Lymph node biopsy from the cervical region revealed follicular lymphoid hyperplasia. He was diagnosed



**Figure 1** - Bone marrow trephine biopsy showing hypocellularity (Hematoxylin & Eosin)

as SS associated with AA. Since the AA was not severe, no medication was commenced and he was given palliative treatment for SS such as eye drops containing artificial tears. Three months later, he was admitted to the emergency clinic with angina pectoris. An ECG revealed ST segment depressions and T negativity on precordial derivations and cardiac enzymes were elevated. He was diagnosed as non-Q myocardial infarction. Coronary angiography was performed on the 4th day of the hospital stay because his angina worsened although all the medical treatment modalities were commenced. Selective coronary angiograms revealed 90% stenosis of the left main coronary artery. Whole blood count showed Hb of 11.7 gr/dl; leukocytes  $2,800 \times 10^9/l$  (absolute neutrophil count was  $700 \times 10^9/l$ ); platelets  $38 \times 10^9/l$ . Two units of platelets were transfused on operation day and platelet count increased to  $118 \times 10^9/l$ . Since he was neutropenic, 30 million IU granulocyte colony stimulating factor (G-CSF) was administered subcutaneously on the night prior to operation. General anesthesia was induced with fentanyl, midazolam, vecuronium, and etomidate. After the median sternotomy, preparation of the left internal mammary artery (IMA) and left radial artery (RA) were performed. Left IMA and RA graft were anastomosed to the left anterior descending artery and the major branch of the left circumflex artery, and the proximal anastomosis of the RA graft was constructed under partial clamping of the aorta. Extracorporeal circulation was discontinued after 40 minutes with an aortic cross-clamp time of 24 minutes. Intraoperative blood cell count showed Hb 7.4 g/dl, platelets  $40 \times 10^9/l$ . Two units of packed red blood cell (RBC), 2 units of platelets, and 2 units of fresh frozen plasma were transfused intraoperatively. During the postoperative period in the intensive care unit (ICU), the repeated blood count showed Hb 9.1 g/dl; platelets  $30 \times 10^9/l$ ;

## Clinical Notes

and leukocytes of  $5.2 \times 10^9/l$ . Within the first 18 hours postoperatively, thoracic drainage produced 1475 ml and a total of 6 units packed RBC, 4 units fresh frozen plasma and 6 units of platelet concentrates were transfused. Extubation was performed on the 18th postoperative hour. On the second day, he was in a good general health with stable blood counts and was discharged from the ICU.

Bleeding and infections are the major complications of cardiovascular surgery and even in hematologically normal patients the platelet count decreases significantly during CABG.<sup>3</sup> In diseases such as AA or myelodysplastic syndrome (MDS) causing cytopenia; these risks increase significantly and there are not enough data for the management of such cases during and after the operation. There are only a few reported cases of MDS with pancytopenia who had successfully undergone CABG.<sup>3,4</sup> In our case, the platelet count was  $38 \times 10^9/l$  on operation day and it was increased to  $118 \times 10^9/l$  with 2 apheresis units of platelets preoperatively. Platelet counts were maintained at safe levels with intra-operative and postoperative platelet transfusions, and no major bleeding episode occurred. Such patients with chronic thrombocytopenia frequently develop allo-antibodies, such as lymphocytotoxic or antiplatelet antibodies, or both, due to frequent transfusions, and become refractory to platelet transfusions.<sup>5</sup> Fortunately, our patient was not transfused previously and platelet transfusions increased the platelet count of the patient to the safe limits. Infections such as mediastinitis, pneumonia, deep sternal infection and subsequent sepsis are major infectious complications seen during the postoperative period. Neutropenic patients are more prone to such complications. On the operation day, the absolute neutrophil count of the patient was

$<1000 \times 10^9/l$ . By the help of G-CSF, the neutrophil count was increased and he was discharged without any bacterial infection.

In conclusion, if there is indication of CABG in a patient with a chronic hematological disorder causing pancytopenia such as MDS or AA, the operation can be performed with appropriate measures such as platelet transfusions and colony stimulating factors.

Received 31st December 2005. Accepted for publication in final form 15th March 2006.

From the Department of Cardiovascular Surgery (Koramaz, Pulathan) Department of Internal Medicine Division of Hematology (Sonmez, Karti) and the Department of Pathology (Cobanoglu), Karadeniz Technical University, School of Medicine, Trabzon, Turkey. Address correspondence and reprint requests to: Dr. Ismail Koramaz, Department of Cardiovascular Surgery, Karadeniz Technical University, School of Medicine, Trabzon TR-61187, Turkey. E-mail: ismailkoramaz@yahoo.com

## References

1. Quiquandon I, Morel P, Lai JL, Bauters F, Dresch C, Gluckman E, et al. Primary Sjogren's syndrome and aplastic anemia. *Ann Rheum Dis* 1997; 56: 438.
2. Matsumoto N, Kagawa H, Ichiyoshi H, Iguchi T, Yamanaka Y, Kishimoto Y, et al. Aplastic anemia complicating Sjogren's syndrome. *Intern Med J* 1997; 36: 371-374.
3. Yamagishi T, Fuse K, Saito T, Kato M, Misawa Y, Kamisawa O, et al. Successful coronary artery bypass grafting for a patient with myelodysplastic syndrome: report of a case. *Surg Today* 1996; 26: 740-743.
4. Miyagi Y, Yamauchi S, Suzuki S, Kitagawa A, Masaki Y, Gomibuchi M, et al. Investigation of coronary artery bypass grafting for a patient with myelodysplastic syndrome. *Ann Thorac Cardiovasc Surg* 2001; 7: 250-253.
5. Klingemann HG, Self S, Banaji M, Deeg HJ, Doney K, Slichter SJ, et al. Refractoriness to random donor platelet transfusions in patients with aplastic anemia: a multivariate analysis of data from 264 cases. *Br J Haematol* 1987; 66: 115-121.