

# The proportions of the white and red pulps of the human fetal spleen

*Bahadır Ungor, MD, Mehmet A. Malas, MD, PhD, Soner Albay, MD, Esra Cetin, MD, Kadir Desdicioglu, MD, Nermin Karahan, MD.*

## ABSTRACT

**Objectives:** To compare the proportions of white and red pulps of the human spleen during the fetal period.

**Methods:** We performed this study in the Department of Anatomy and Pathology of Suleyman Demirel University, Faculty of Medicine, Isparta, Turkey, from the period between 2002-2003. Splens from 137 dead fetuses aged between 9 and 40 weeks were embedded into paraffin blocks following classical histological steps and stained with hematoxylin and eosin. White and red pulps could be differentiated only in 25 cases (13 males, 12 females). The proportions of the areas of white and red pulps (the trabeculae were included into the red pulp and the groups of lymphocytes were included into the white pulp) were estimated by point counting method on the sections taken from different parts of the splens by systematic randomized sampling technique.

**Results:** It has been ascertained that the white pulp has

been distinguished from 20th week onwards during the fetal period. The proportion of the white pulp area has been found to be 22.3% (of total white and red pulp areas) at the 20th week and has come to 37.6% at the 40th week. Concerning the trimesters, the proportion of the white pulp area has been found to be 30% (of total white and red pulp areas) at the 2nd trimester and has come to 36% at full term. While the white pulp area had a positive correlation with the gestational age ( $r: 0.34$ ), the red pulp area had a negative one ( $r: -0.34$ ). No difference has been found among gender.

**Conclusion:** Reference values have been obtained about the proportions of white and red pulp areas of human fetal spleen.

**Saudi Med J 2006; Vol. 27 (9): 1315-1319**

The primordium of the spleen appears in human embryos, in the fifth week of gestational age.<sup>1</sup> The preliminary stage lasts up to 12th week and called as the stage of the primary vascular reticulum. Areas of red and white pulps can not yet be distinguished. The period from the 13th week up to 16th week is called as the transformation stage, the splenic primordium becomes organized into angioarchitectural units, the so called lobules of Mall. The axis of this lobule is

oriented by a central artery and these areas have not yet been invaded by lymphoid cells.<sup>1</sup> The red pulp differentiates at the periphery of these lobules.<sup>1</sup> The period which is related with the development of the white pulp is called the stage of lymphoid colonization and lasts from the 16th week up to the 22nd week.<sup>1</sup> Beginning with the 15th week, single lymphoblastic cells are seen intravascularly and scattered in the splenic parenchyma.<sup>1,2</sup> During the 16th week these

From the Department of Anatomy (Ungor, Malas, Albay, Cetin, Desdicioglu), Gaziosmanpasa Universitesi Tip Fakultesi, and the Department Pathology (Karahan), Medical Faculty, Suleyman Demirel University, Isparta, Turkey.

Received 25th February 2006. Accepted for publication in final form 11th June 2006.

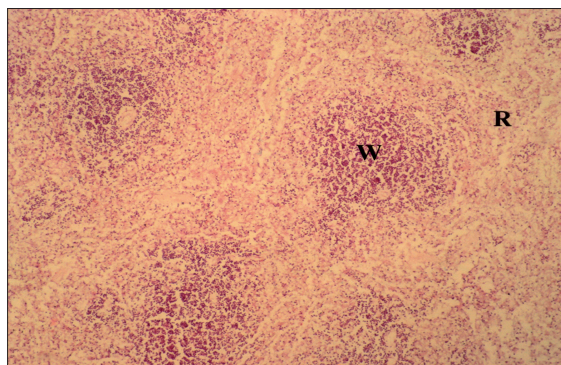
Address correspondence and reprint request to: Dr. Bahadır Ungor, Gaziosmanpasa Universitesi Tip Fakültesi, Anatomi Anabilim Dalı, Kışla Yolu 60100 Tokat, Turkey. Tel. +90 (356) 2121746/1232. Fax. +90 (356) 2133179. E-mail: bungor04@yahoo.com

lymphoid cells become more numerous and an accumulation of lymphocytes around the central arteries can be recognized at the 17th and 18th weeks. These lymphoid cells show morphological and immunohistochemical characteristics of T-precursor cells. Around the 21st week, the assemblage of primary follicles is discernible at the periphery of the periarterial lymphoid sheath and represent the beginning of formation of the B-cell region.<sup>1</sup> The lymphoid tissue in the human fetal spleen differentiates rather late compared with such peripheral lymphatic organs as lymph nodes and the tonsilla palatina and the interval between the beginning differentiation of T-cell regions and B-cell regions is longer. A remarkable growth of the lymphatic tissue can be followed between the 18th and 22nd weeks while the red pulp seems to cease its extension and in the 22nd week, the white pulp occupies about half of the organ volume which is in flagrant contradiction to the proportion in the postnatal spleen, where the red pulp makes up more than 80% of the volume.<sup>1</sup> At a study on low birth weight human fetuses,<sup>3</sup> as a reaction to antigenic influences, a high increase in the number of lymphoblasts and partly of macrophages in the spleen and lymph nodes, but when the antigenic influences were severe, a decrease in the number of small lymphocytes, lymphoblasts and macrophages have been observed. Germinal centers do not form prenatally, but it appears at the end of the 1st postnatal month.<sup>1,4,5</sup> While an immunologically important marginal zone of special B-cells at the periphery of the lymphoid follicle in the adult human spleen has been distinguished, no separate subcompartments could be discerned but the splenic lymphoid follicle have been observed to be consisted of intermediate size lymphocytes by the study of Timens *et al*<sup>6</sup> on human fetuses. The amounts of white and red pulps of both the human and the rat spleen may change in postnatal period in some conditions<sup>7-14</sup> and the data about the proportion of the areas of white and red pulps of the human fetal spleen may also have importance in the assessment of spleen development and of congenital hematologic and immunologic pathologies. When researching the literature, we have noticed a deficiency about the knowledge of the proportions of white and red pulps, especially for the period from the 22nd week until the birth and aimed to investigate on this subject.

**Methods.** This study was carried out on 137 dead fetuses (72 males and 65 females) with no external anomaly or pathology with an age range between 9-40 weeks of gestation (crown-rump length [CRL]: 60-420 mm). This study took place in the Department

of Anatomy and Pathology of Suleyman Demirel University, Faculty of Medicine, Isparta, Turkey, in the years 2002-2003. Data were collected with the families' consent from Isparta Maternity and Children's Hospital between the years 1996 and 2002 and was preserved at the laboratory of the Department of Anatomy. Approval from The Ethics Committee of Suleyman Demirel University Medical Faculty was obtained before the study. The ages of the fetuses have been determined by the crown-rump length until the 12th week and by biparietal width, head circumference and foot length thereafter. Fetuses aged between 9-12 weeks comprised the 1st group (1st trimester), 13-25 weeks comprised the 2nd group (2nd trimester), 26-37 weeks comprised the 3rd group (3rd trimester), and 38-40 weeks comprised the 4th group (full term). The cases detected with any visible anomaly or pathology at the abdominal dissection were also excluded in the study and the spleens from grossly normal cases have been taken into 10% formaldehyde solution. Following the routine histological methods, the spleen pieces have been embedded into paraffin blocks and 3 different slices at 5  $\mu$ m thicknesses have been obtained by the systemic and randomized sampling method. They have been stained by hematoxylin and eosin. Due to lysis or low fetal age, the white and red pulp areas could not be distinguished clearly on the most of the spleen slices, but the proportions of them could be calculated only for 25 fetuses (13 males, 12 females) whose gestational ages ranged from 20 to 40 weeks (**Figure 1**). A 100 x 100 pointed grid was placed onto each slice under 4x objective and the images have been transferred to a monitor. Point counting method have been applied for the white and red pulp areas on the monitor screen. A total of 391 points were present on each assessed area. One area from each of 3 slices from each spleen has been assessed and the mean value for each spleen has been calculated. Especially for the bigger spleens, areas away from the capsule have been preferred. The trabeculae have been counted in the red pulp. Lymphocyte groups within the red pulp have been included into the white pulp because it was impossible for us to differentiate the lymphoid follicles from these lymphocyte groups since the slices may not have passed across the central arteries which define the follicles. The relation of the proportions of white and red pulp areas with the gestational age and gender differences have been investigated by using the SPSS statistical program.

**Results.** The white pulp has been distinguished clearly in the spleens of fetuses which were 20 weeks old as earliest, the proportions of the white and red



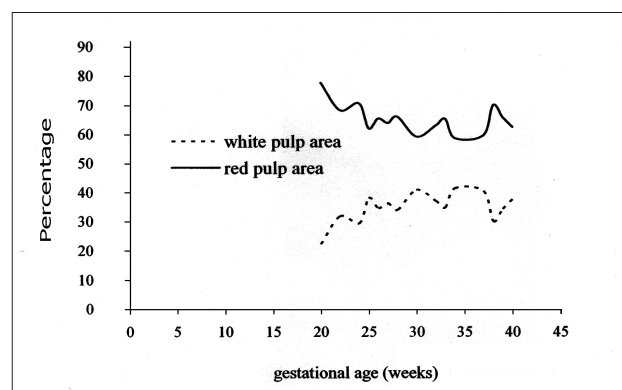
**Figure 1** - The white and red pulp areas of the spleen of a 40-week-old male fetus. W - white pulp, R - red pulp. hematoxylin and eosin x 120.

pulp areas have been calculated and the mean values were taken for each week (**Table 1**). The proportion of the white pulp area has been found to be 22.3% (of total white and red pulp areas) at the 20th week and has come to 37.6% at the 40th week. While the white pulp area had a positive correlation with the gestational age (r: 0.34, **Figure 2**), the red pulp area had a negative one (r: -0.34, **Figure 2**). As a consequence the proportion of white pulp area to the red pulp has increased with the gestational age. Concerning the trimesters, the proportion of the white pulp area has been found to be 30% (of total white and red pulp areas) at the 2nd trimester, 37% at the 3rd trimester and has come to 36% at the full term. No difference has been found among gender.

**Table 1** - The mean proportions of white and red pulp areas for the during the fetal period.

Age (weeks)	Case no.	Proportion of white pulp area, % (mean)	Proportion of red pulp area, % (mean)	White pulp area/red pulp area ratio (mean)
20	1	22.3	77.7	0.29
22	1	31.8	68.2	0.47
24	1	29.4	70.6	0.42
25	1	38.0	62.0	0.61
26	2	34.6	65.4	0.53
27	1	36.2	63.8	0.57
28	1	34.0	66.0	0.52
30	2	40.9	59.1	0.69
32	3	37.1	62.9	0.59
33	1	34.8	65.2	0.53
34	1	41.4	58.6	0.71
37	1	40.4	59.6	0.68
38	1	30.1	69.9	0.43
39	3	34.3	65.7	0.52
40	5	37.6	62.4	0.60

**Discussion.** In the literature,<sup>1,5,15</sup> it has been reported that the white and red pulps begin to be distinguished at the 6th month of gestation, as being in accordance with the result of our study.



**Figure 2** - The proportions (percentages) of the white and red pulp areas at the fetal period.

**Table 2** - The proportions of white and red pulp areas compared with other studies.

Reference	Period	Mean age or period (n)	White pulp area (%)	Red pulp area* (%)
Myhre and Kristensen <sup>7</sup>	Postnatal	49 years (10)	13.4	86.6
Van Krieken et al <sup>8</sup>	Postnatal	60 years (60)	13.5	86.5
Milicevic et al <sup>9</sup>	Postnatal	71 years (8)	14.4	85.6
Gurevich et al <sup>3</sup>	Fetal†	22-32 weeks (11)	22.3	77.7
Present study	Fetal	20-40 weeks (25)	35.7	64.3

\*trabeculae included within the red pulp, †in low-birth-weight human fetuses

Concerning the fetal period, we have come across with only 2 studies reporting regarding proportions of the pulps.<sup>1,3</sup> Vellguth et al<sup>1</sup> study on the fetuses between 12th and 22nd weeks, they observed that the white pulp occupies about half of the organ volume in the 22nd week. But whether the lymphocyte groups within the red pulp have been included to the white pulp has not been denoted. Although we included them to the white pulp in our study, the white pulp area comprised 31.8% of the total pulp area at the 22nd week and reached to a maximum level of 41.4% at the 34th week. In a different study made on adults, the total amount of the lymphocyte groups within the red pulp has been detected to be equal to the white pulp located around the central arteries.<sup>16</sup> The second study has been made on low birth weight human fetuses (gestational ages were ranging from 22 weeks to 32 weeks) and the mean values were 22.3% for the white pulp area and 77.7% for the red pulp area including the trabeculae (Table 2).<sup>3</sup> In the same study, it has been denoted that the white pulp area had a positive correlation with the increasing fetal weight (r: 0.75) and the moderate degree of antigenic stimulus have caused the white pulp area ratio to increase a mean level of 25% of total pulp area but a high degree of antigenic stimulus have caused to decrease a mean level of 13.3%. Since the definition of follicular area has been used as corresponding to the white pulp, we conclude that the lymphocyte groups within the red pulp were not included. In our study, for the fetuses ranging from 22 to 32 weeks, 35.97% of the total pulp area has been consisted of the white pulp as a mean and the white pulp area received a positive correlation with an increasing fetal weight (r: 0.47). In adult humans, the red pulp constitutes the majority (about 75%) of the total splenic volume.<sup>17</sup> In previous studies,<sup>7-9</sup> the percentages of the white and red pulp were summarized in Table 2. In those studies, the spleens from either patients with carcinoma or non-neoplastic, miscellaneous cases including the accidental and incidental splenectomy applications have been used. From the descriptions, it has been concluded that most probably the lymphocyte groups within the red pulp have not been counted in the white pulp in these previous studies. Furthermore, it must be considered that both the white and red pulps are divided into subcompartments and sometimes they are counted together and sometimes separately. For example, the perifollicular zone, which is characterized by macrophage sheathed capillaries and difficultly distinguished in routine hematoxylin and eosin sections is included in the red pulp but sometimes it can be regarded as a separate compartment.<sup>16</sup>

In humans concerning the postnatal period, the white pulp area has been observed to be diminished in

cases of Wiscott Aldrich syndrome (characterized by immunodeficiency and thrombocytopenia),<sup>10</sup> the non-filtering area of the red pulp, containing fair amounts of lymphoid cells (lymphocyte groups), has decreased in Hodgkin's disease,<sup>8</sup> white pulp area proportion has increased in traumatic and splenectomized cases,<sup>9</sup> the lymphoid follicular diameter has increased while the T-dependent area has not in FTP cases.<sup>11</sup> In cases of autoimmune hemolytic anemia and hereditary spherocytosis, red pulp has increased both in real and proportional amount,<sup>7</sup> and in Felty syndrome which is characterized by granulocytopenia, the spleen has been found to be enlarged mainly due to expansion of the red pulp.<sup>12</sup> Additionally, on adult rats ethanol has caused the lymphoid follicular volume to decrease,<sup>13</sup> and on adult mice the hypoxia has caused the red pulp amount to increase but after a critical level hypoxia has caused the red pulp amount to decrease.<sup>14</sup> By this study, reference values have been obtained about the proportions of the areas of white and red pulps of the human fetal spleen. We hope that it can contribute to the assessment of pathologies related with the fetal spleen. By using fresh cadavers and aiming the sub-level compartments of the fetal spleen pulps, both for normal and special cases, more valuable results can be obtained in future studies.

## References

1. Vellguth S, Von Gaudecker B, Muller-Hermelink HK. The development of the human spleen ultrastructural studies in fetuses from the 14th to 24th week of gestation. *Cell Tissue Res* 1985; 242: 579-592.
2. Playfair JHL, Wolfendale MR, Kay HEM. The leucocytes of peripheral blood in the human foetus. *Brit J Haematol* 1963; 9: 336-344.
3. Gurevich P, Czzernobilsky B, Ben-Hur H, Nyska A, Zuckerman A, Zusman I. Pathology of lymphoid organs in low-birth-weight human fetuses subjected to antigen-induced influences: a morphological and morphometric study. *Pediatr Pathol* 1994; 14: 679-693.
4. Odaci E, Aydin S, Tekelioglu Y, Arvasi H, Ozoran Y. Comparison of the development of 6-9th months-old human fetus spleen with the adult human spleen by histological methods and histochemical reaction. *Morfoloji Dergisi* 1998; 6: 30-35.
5. Kyriazis AA, Esterly JR. Fetal and neonatal development of lymphoid tissues. *Arch Path* 1971; 91: 444-451.
6. Timens W, Rozeboom T, Poppema S. Fetal and neonatal development of human spleen: an immunohistological study. *Immunology* 1987; 60: 603-609.
7. Myhre JO, Kristensen J. Red pulp of the spleen in autoimmune haemolytic anemia and hereditary spherocytosis: Morphometric light and electron microscopy studies. *Scand J Haematol* 1986; 36: 263-266.
8. Van Krieken JHJM, Te Velde J, Welvaart K. The splenic red pulp; a histomorphometrical study in splenectomy specimens embedded in methylmethacrylate. *Histopathology* 1985; 9: 401-416.

9. Milicevic Z, Cuschieri A, Xuereb A, Milicevic NM. Stereological study of tissue compartments of the human spleen. *Histol Histopathol* 1996; 11: 833-836.
10. Vermi W, Blanzuoli L, Kraus MD, Grigolato P, Donato F, Loffredo G, et al. The spleen in the Wiskott-Aldrich syndrome: histopathologic abnormalities of the white pulp correlate with the clinical phenotype of the disease. *Am J Surg Pathol* 1999; 23: 182-191.
11. Arendt T, Nizze H. B- and T-lymphocyte compartments in the spleen in idiopathic thrombocytopenic purpura. *Folia Haematol Int Mag Klin Morphol Blutforsch* 1988; 115: 711-718.
12. Van Krieken JHJM, Breedveld FC, Te Velde J. The spleen in Felty's syndrome: A histological, morphometrical, and immunohistochemical study. *Eur J Haematol* 1988; 40: 58-64.
13. Budec M, Milicevic Z, Koko V. Stereological study of rat spleen following acute ethanol treatment. *Indian J Exp Biol* 2000; 38: 462-466.
14. Clegg EJ. Morphometric studies of the spleen of the hypoxic mouse. *J Microsc* 1983; 131: 155-161.
15. Skandalakis PN, Colborn GL, Skandalakis LJ, Richardson DD, Mitchell WE, Skandalakis JE. The surgical anatomy of the spleen. *Surg Clin North Am* 1993; 73: 747-767.
16. Van Krieken JHJM, Te Velde J. Normal histology of the human spleen. *Am J Surg Pathol* 1988; 12: 777-785.
17. Bannister LH. Haemolymphoid system. In: Williams PL, editor. *Gray's Anatomy*. 38 ed. London: Churchill Livingstone Medical Division of Longman UK; 1995. p. 1400-1450.