

Arterial homograft and medical therapy in pseudoaneurysm of infrarenal aorta concomitant with recurrent right ventricular thrombus in Behçet's disease

Jalal Vahedian, MD, FIAS, Ali Sadeghpour, MD.

ABSTRACT

Pseudoaneurysm of the infrarenal aorta due to Behçet's disease is very rare. We report a case of pseudoaneurysm associated with Behçet's disease in a 17-year-old boy with a recurrent right ventricular thrombus successfully treated with revascularization using arterial homograft patch. Echocardiography examination revealed a right ventricular mass, thought to be a thrombus in an unusual location. Postoperatively, the findings of the pathologic examination confirmed the mass as a thrombus. When the patient was subsequently re-admitted to the emergency unit with complaints of severe abdominal pain, fever, fatigue, sinus tachycardia, and a pulsating and tender abdominal mass, a right ventricular thrombus and a large pseudoaneurysm of the abdominal aorta were found on echocardiography and angiography. The patient underwent resection of the aortic aneurysm and aortoplasty, using arterial homograft patch, and received immunosuppressive and anticoagulation therapy. The thrombus of the right ventricle disappeared 4 months later. This case indicates that a right ventricular thrombosis in Behçet's disease may be managed by medical therapy.

Saudi Med J 2006; Vol. 27 (9): 1401-1403

Behçet's disease is a multisystem inflammatory disease of unknown cause. Its major pathologic feature is vasculitis. It is seen most often in young adults of Asian and Mediterranean basin population. It is characterized by relapsing uveitis, and oral and genital ulcerations. The typical vascular feature is medium- and large- vessel involvement; which causes both arterial occlusive disease and aneurysm formation. The cessation of nutrient flow to the arterial wall due to inflammatory obliteration of the vasa vasorum can lead to perforation of artery followed by pseudoaneurysm formation. Our objectives in reporting this case were to highlight the

need for awareness of Behçet's disease in a patient suffering bizarre pseudoaneurysm and/or right heart thrombus. Moreover, this heart complication can be resolved non-surgically by means of managing the underlying disease. We report the case of a boy with Behçet's disease who had a big pseudoaneurysm of the abdominal aorta, concomitant with recurrence of right ventricular thrombosis. The pseudoaneurysm and ventricular thrombosis were managed by surgical and medical therapy.

Case Report. In April 2005, a 17-year-old young man who had been experiencing severe abdominal

From the Department of Cardiovascular Surgery, Rajaie Hospital and Research Center, Tehran, Iran.

Received 3rd January 2006. Accepted for publication in final form 22nd March 2006.

Address correspondence and reprint request to: Dr. Jalal Vahedian, Department of Cardiovascular Surgery, Rajaie Hospital and Research Center, Adjacent to Mellat Park, Vali-Asr Ave. PO Box 1996911151, Tehran, Iran. E-mail: jalvahedian@yahoo.com

pain, high grade fever, anorexia, and weight loss, was referred to our center because of a rapidly expanding and pulsatile abdominal mass. On admission, the patient was hemodynamically stable. Physical examination revealed an emaciated boy that flexed knees toward his abdomen to reduce pain. A round mass about 15-cm-diameter founded in the left para umbilical area. Arterial pulses from femorals to pedals were normal. He underwent cardiac surgery for removing a right ventricular mass during one-month previous admission. Pathological examination revealed an old and organized thrombus. A detailed medical history revealed that the patient had relapsing genital ulcerations and oral aphthous ulceration. Papulopustular skin lesions were visible in lower extremities. Results of routine laboratory tests were normal except for moderate leukocytosis (white blood cells = 11300; neutrophil = 78%, lymphocyte = 15% and eosinophil = 7%), high erythrocyte sedimentation rate (ESR) = 103 mm/1st hour), and positive antiphospholipid antibody. Multislice computed tomography angiography revealed a pseudoaneurysm in the abdominal aorta (**Figure 1**). While investigating the source of fever, a transthoracic echocardiography was performed and revealed a nonhomogenous mass in the right ventricle approximately 2.5 x 1.6-cm-diameters attached to the site of previous mass one month before (**Figure 2**).

Surgical technique. After the induction of general endotracheal intubation, and insertion of arterial and central venous lines, a long midline celiotomy was carried out. An inflammatory and pulsatile mass covering with edematous posterior peritoneum about 10x10 cm-diameters encountered in the left antero-lateral aspect of vertebral column. Patchy necrosis was present over the mass. Its tissue was fragile. Anticoagulation state achieved by intravenous injection of 200 IU/kg heparin. Then, aorta in proximal and distal to the mass explored and controlled by vascular clamps. The sac of the aneurysm opened. Its wall was necrotic containing pus-like materials. Debridement was carried out onto the aorta wall. Harvested material submitted to pathologic and microbiologic studies. Impression of mycotic pseudoaneurysm was made by intra-operation findings. Between alternative procedures, such as prosthetic graft, frozen aortic homograft was used for repair of the aortic defect measuring 5x2 cm-diameter. The patient had an uneventful postoperative course. The results of the laboratory showed no infections. Histological examination of the aneurysm wall revealed full thickness aortitis. According to the rheumatologist consultation and based on the criteria of the International Study Group for Behçet's disease¹

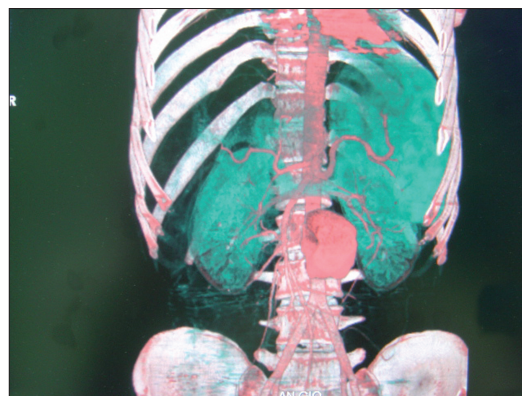


Figure 1 - Echocardiogram reveals a right ventricular thrombus in a patient suffering from Behçet's disease.

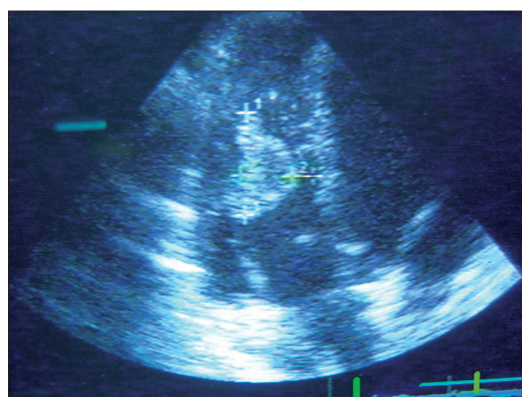


Figure 2 - Computerized tomography angiography reveals a pseudoaneurysm of infra renal aorta in patient suffering from Behçet's disease.

consisting of oral and genital ulcers, papulopustular skin lesion, cardiac thrombus, and pseudoaneurysm of aorta, associated with aortitis, diagnosis of Behçet's disease was made. Immunosuppressive therapy was begun. The patient was discharged home on the 9th postoperative day. Sequential follow-up examination showed that the patient was in good condition. But, on the last follow-up there is a moderate cushingoid appearance due to corticosteroid therapy. Transthoracic echocardiography revealed no mass in any chambers of his heart with good ejection fraction.

Discussion. Hulusi Behçet, a dermatologist in 1937 reported a triad of "oral ulcers, genital ulcers and relapsing uveitis" as the diagnostic criteria of Behçet's disease.² This disease is now regarded as a systemic illness manifesting with recurrent oral or genital ulcers or large-vessel vasculitis, arthritis and meningoencephalitis.² It is estimated that the rate of vascular involvement in Behçet's disease varies

from 7-29%. Large arterial lesions are infrequent in Behçet's disease; they are estimated to occur in 1.5-2.2% of all patients with Behçet's disease.³ However, cardiac involvement is uncommon and occurs sporadically in Behçet's disease.⁴ Diffuse aortitis with resultant proximal aortic dilatation may lead to severe aortic regurgitation, requiring valve replacement.⁵ Occasionally, coronary arterial involvement results in myocardial infarction.^{6,7} Cardiac thrombosis is a rare finding in Behçet's disease. Unfortunately, there are few case reports about this unusual complication.^{2,8} Behçet's disease is a form of vasculitis syndrome characterized by inflammation of any size blood vessel wall.² Intravascular thrombus formation in patients with Behçet's disease is attributed to endothelial cell injury from this vascular inflammation. Endothelial injuries leading to platelet aggregation, immune complexes causing impairment in fibrinolysis and decrease in the release of tissue plasminogen activator are the possible mechanisms in the pathogenesis of intravascular thrombus formation in vasculitis.^{9,10} Another explanation for thrombus formation in patients with Behçet's disease is the presence of antiphospholipid antibodies, found in 18% of patients.¹¹ Our patient had positive antiphospholipid antibody. This antibody has been identified in one patient with Behçet's disease and intracardiac thrombi.² Antiendothelial cell antibodies have been associated with vascular involvement.¹¹ However, there is no published evidence specific to intracardiac thrombosis. It is not known whether the antiendothelial cell antibodies are also directed against antigens presented by the endocardial cell. It is recognized that organ involvement in Behçet's disease varies geographically, for instance gastrointestinal involvement is common in Japan but rare in Turkey.¹² Mogulkoc et al¹² in a systematic review found only one case complicated by intracardiac thrombus among Far Eastern patients. This is consistent with the geographic variability in a model of clinical presentation and systemic organ involvement, suggesting that genetic predisposition may be highly relevant in determining systemic organ involvement in the disease.

In conclusion, this case has demonstrated that Behçet's disease should be considered in terms of the heart and vessels, especially in the presence of right heart thrombus or bizarre involvement of the vascular tree. In such situations, heart thrombi can be treated medically.

Acknowledgment. We would like to thank Pedram Amouzadeh for editing the article.

References

1. Criteria for diagnosis of Behçet's disease. International Study Group for Behçet's Disease. *Lancet* 1990; 335: 1078-1080.
2. Dincer I, Dandachi R, Atmaca Y, Erol C, Caglar N, Oral D. A recurrent right heart thrombus in a patient with Behçet's disease. *Echocardiography* 2001; 18: 15-18.
3. Hamza M. Large artery involvement in Behçet's disease. *J Rheumatol* 1987; 14: 554-559.
4. Atzeni F, Sarzi-Puttini P, Doria A, Boiardi L, Pipitone N, Salvarani C. Behçet's disease and cardiovascular involvement. *Lupus* 2005; 14: 723-726.
5. Lee CW, Lee J, Lee WK, Lee CH, Suh CH, Song CH, et al. Aortic valve involvement in Behçet's disease. A clinical study of 9 patients. *Korean J Intern Med* 2002; 17: 51-56.
6. Kaseda S, Koiwaya Y, Tajimi T, Mitsutake A, Kanaide H, Takeshita A, et al. Huge false aneurysm due to rupture of the right coronary artery in Behçet's syndrome. *Am Heart J* 1982; 103 (4 Pt 1): 569-571.
7. Eryol NK, Topsakal R, Abaci A, Oguzhan A. A case of atrioventricular complete block due to Behçet's disease. *Jpn Heart J* 2002; 43: 697-701.
8. Gurgun C, Sagcan A, Cinar CS, Yagdi T, Zoghi M, Tekten T, et al. Right atrial and ventricular thrombi in Behçet's disease: a case report and review of literature. *Blood Coagul Fibrinolysis* 2000; 11: 107-110.
9. Schmitz-Huebner U, Knop J. Evidence for an endothelial cell dysfunction in association with Behçet's disease. *Thromb Res* 1984; 34: 277-285.
10. Jordan JM, Allen NB, Pizzo SV. Defective release of tissue plasminogen activator in systemic and cutaneous vasculitis. *Am J Med* 1987; 82: 397-400.
11. Hull RG, Harris EN, Gharavi AE, Tincani A, Asherson RA, Valesini G, et al. Anticardiolipin antibodies: occurrence in Behçet's syndrome. *Ann Rheum Dis* 1984; 43: 746-748.
12. Mogulkoc N, Burgess MI, Bishop PW. Intracardiac thrombus in Behçet's disease: a systematic review. *Chest* 2000; 118: 479-487.