

# Satellite implantation of the skin with malignant melanoma

*Abdulqadir M. Zangana, CABS, FICS.*

---

## ABSTRACT

We report a 68-year-old female patient referred to the Surgical Department of Erbil Teaching Hospital (university hospital), Erbil, Iraq with the diagnosis of malignant melanoma of the right upper thigh of one-year duration. Six months after primary lesion, she developed a satellite skin nodule of malignant melanoma over the unhealthy skin of the anterior abdominal wall in direct contact with the primary lesion. She also had a pendulous abdominal wall. This kind of spread of melanoma is unusual, and of non-classical route. We also discussed herein, similar cases admitted to our hospital.

Saudi Med J 2006; Vol. 27 (9): 1404-1406

---

Melanoma is considered in Iraq as an important malignancy due to its increased incidence during the last decade, and its occurrence at an earlier age group. Compared to Europe and the United States, the mean age of occurrence was 53 years versus 46 years in Iraq, which is probably due to environmental causes.<sup>1,2</sup> Melanoma occurs in all age groups (mean age of 38 years), it arise anywhere in the skin anywhere in the body.<sup>3,4</sup> The lower legs are the most common site in women, and in the back for men. In most studies the incidence of melanoma is doubling every 6-10 years.<sup>5-7</sup> Most current staging system divides melanoma into 3 clinical stages: localized disease (stage I), regional metastases (stage II), and distant metastases (stage III).<sup>8-10</sup> Under the new staging system the Breslow and Clark microstaging method categories divided melanoma into 5 staging levels according to the depth of penetration, which is important from the prognostic point of view.<sup>11,12</sup>

The aim of this study was to ascertain other non-classical routes of spread in malignant melanoma by

implantation, probably by direct prolonged contact with unhealthy skin far from the primary lesion.

**Case Report.** We report a 68-year-old female patient referred to Erbil Teaching Hospital, Erbil, North of Iraq on September 15, 2005 with a large ulcerative lesion on the upper part of the thigh of 12 months duration. A solitary satellite nodule of the skin over the anterior abdominal wall was observed in direct contact with the primary lesion. This satellite nodule appeared 6 month after the primary lesion. No other lesions of the skin were detected. The patient had a pendulous abdomen due to multiparty (site of continuous friction, moisture and superimposed fungal infection).

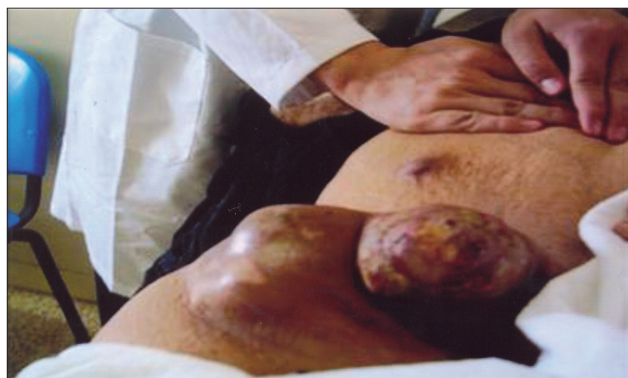Physical examination revealed a well built elderly anemic woman with an ulcerative lesion of the upper thigh measuring 10 × 8 cm, and a black nodule on the skin of the anterior abdominal wall at the site of contact with primary lesion of 6 months duration (**Figure 1**). Clinical investigation revealed the following; hemoglobin of 8.6 gm/dl (normal range (NR): 11-15 gm/dl), and erythrocyte sedimentation rate of 98 mm/

---

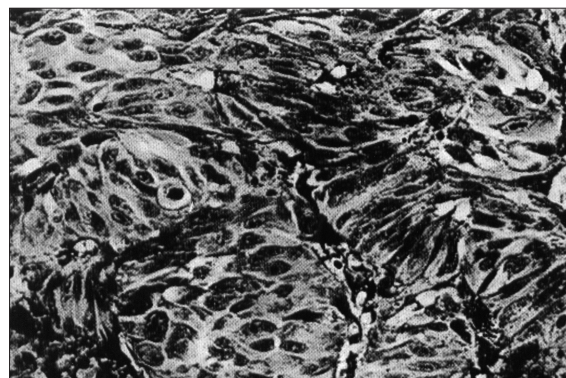
From the Department of Surgery, College of Medicine, University of Salahaddin, Erbil, Iraq.

Received 30th November 2005. Accepted for publication in final form 15th March 2006.

Address correspondence and reprint request to: Dr. Abdulqadir M. Zangana, Head, Department of Surgery, College of Medicine, University of Salahaddin, Erbil, Iraq. Fax: +964 (70) 4512938. E-mail: draqzangana@yahoo.com



**Figure 1** - Malignant melanoma in the upper thigh with satellite nodule on the skin of anterior abdominal wall.



**Figure 2** - Malignant melanoma in skin showing characteristic of acinar grouping of cells 275. (Biopsy from skin of the anterior abdominal wall in contact with the primary lesion of the thigh).

hour (NR: <20 mm/hour), biochemical study was normal including liver function tests (LFT), which is an appropriate screening test for occult metastasis disease. Clinical and radiological examination of the chest was normal, as well as results of computed tomography scanning, ultrasonography, and magnetic resonance imaging of the abdomen, with no evidence of intracranial metastases.

Incisional biopsy from the primary lesion showed junctional nevus with malignant transformation involving all layers of the epidermis, whereas excisional biopsy of the satellite lesion showed a malignant melanoma in skin with the characteristic of acinar grouping of cells (**Figure 2**) without involvement of the nearby lymphatic vessels.

**Discussion.** Cancer Registration Center in Mousl (Nuclear Medical Hospital), to which most of cancer patients were referred to for chemoradiotherapy showed that the annual incidence of malignant melanoma in the North of Iraq including Mousl, Erbil, Dohuk, and Sulymania governorates (6.5 million populations) before 1991 was 2 per 100,000 and by 2002 the incidence had risen to 6 per 100,000.<sup>13</sup>

Ulceration in melanoma is an important histologic feature that reflects a more biologically aggressive tumor, and is best diagnosed as a disruption of the epithelium overlying the melanomas as seen on microscopic slides.<sup>14-16</sup> Although skin metastases is common in malignant melanoma, we exclude all cases where the secondary skin lesions were far from the site of the primary lesions, and all cases with distant and multiple metastases, considering its spread was through the lymphatic vessels and blood streams.

Ninety-three cases with malignant melanoma referred to our hospital between years 1999 and 2002.

Thirty one lesions were arising in the lower limb, 24 cases were female patients and 7 male. Eight of them had lesions in the upper most part of the thigh and half of them had satellite nodules over the site of contact with the skin of the anterior abdominal wall. Twenty eight patients with melanoma of the upper limb, 18 females and 10 male. Seven patients with primary lesions in the uppermost medial part of the arm (lateral axillary wall), 3 of them with satellite lesions in the medial wall of the axilla (in direct contact to the primary lesion) with no palpable axillary nodes. The incidence of satellite implantation in malignant melanoma in a total number of 93 patients was 7 cases (7.6%) in the areas where the skin is indirect contact with the primary lesions, and the appearance of these nodules were ranged between 6 month and 18 month from the diagnosis of primary tumors, which indicate that they need along time of contact before its appearance. From our observations on 93 patients with malignant melanoma, we found that in the areas of contact of unhealthy skin with the primary lesions of malignant melanoma probably there is a good chance for satellite implantation of malignant cells to the unhealthy opposite skin due to continuous friction, abrasion, moisture and usually super imposed fungal infection probably creates a good culture media for growth to be implanted, as well as other factors such as immunocompromised patients all these factors plays an important role in this implantation, which is probably another route of melanoma spread beside through the lymphatic vessels and blood stream.

In conclusion, this study hoped to guide healthcare professionals, oncologist, and cancer specialist for open discussion with pathologists, cancer epidemiologist, and oncologist surgeons. Further studies, extensive investigations, and probably experimental studies are

needed to clear out these facts, and answer questions related to this route of metastasis.

**Acknowledgments.** We would like to thank the following respective Drs. for their help and advice: 1. Dr. Birhym, FRCPATH (London) Professor of Pathology, University of Mousl, Iraq. 2. Dr. Nawal Allash, FRCPATH (London), Professor of Pathology, University of Baghdad, Iraq. 3. Dr. Salah Abu-Baker, (Board Pathology, Iran) Senior Lecturer in Pathology, University of Salahaddin, Erbil, Iraq.

## References

- Balch CM, Milton CW, editors. Cutaneous melanoma, clinical management and Treatment Results Worldwide. Philadelphia: JB Lippincott; 1985.
- Clark W, Goldman L, Mastrengeolo M. Human Malignant Melanoma. New York: Grune and Strattan, 1979.
- Fee HJ, Robinson DS, Sample WF. The determination of lymph node spread to colloidal gold scanning in patients with malignant melanoma. A preliminary study. *Surgery* 1978; 84: 626.
- Guiliaano AE, Moseley H, Morton DL. Clinical Aspects of unknown primary melanoma. *Ann Surg* 1980; 191: 98.
- Lee jah. Melanoma and exposure to sunlight. *Epidermal Rev* 1982; 4: 110.
- Roces DF, Harris MN, Ackerman AB. Diagnosis and Management of Cutaneous Malignant Melanoma. Vol. 27. Philadelphia: WB Saunders; 1983.
- Alberitni JJ, Cruse CW, Parker SL, Tong T, Bolden S, Wingo PA, et al. Intraoperative radio-lympho-Scintigraphy improves sentinel lymph node identification for patients with melanoma. *Ann Surg* 1996; 223: 217.
- Balch CM, Houghton AN, Taboada CF, McMurray JD, Jordan RA, Seybold WD, et al. Cutaneous melanoma. 2nd ed. Philadelphia: JB Lippincott; 1992.
- Barnhim RL, Busan KL. Pathology of Melanocytic nevi and Malignant Melanoma. New York; Batterworth-Heinemann: 1995.
- Lee CA, Fritz KA, Einom LH, Burgess MA, Valleios C, Bodey GP Sr., et al. Second cutaneous malignancies in patients with mycosis fungoids treated with nitrogen masterd. *J Am Acad Dermatol* 1982; 7: 590.
- Wick MR. Malignant tumours of the epidermis in farmer. Hood AF, editor. Pathology of the skin. Norwalk (CT): Appleton and Lange; 1990. p. 568.
- Webb WR, Gamsu G. Thoracic metastasis in malignant melanoma: a radiographic survey of 65 patients. *Chest* 1977; 71:176-181.
- Rogers RSIII, Gibson LE. Mucosal, genital, and unusual clinical variants of melanoma. *Mayo Clin Proc* 1997; 72: 362-366.
- Kadir A, Kadir Z. Thyroid cancer in the north of Iraq after the second Gulf war. Vol. 8. Iraq. J Dohuk Univ.; 2005. p. 95-99. Available from URL://<http://Dohukjournal.com>
- Swettes SM. E-medicine. Malignant Melanoma. 2001. Available from URL:<http://www.emedicine.com/>
- Breslow A. Prognosis in cutaneous melanoma: Tumour thickness as a guide to treatment. *Athol Ann* 15; 1: 1980.