

### Successful initial treatment with caspofungin alone for hepatosplenic candidiasis in a patient with acute myeloblastic leukemia

Abdullah Altintas, MD, Orhan Ayyildiz, MD,  
Abdurrahman Isikdogan, MD, Engin Atay, MD,  
Mehmet A. Kaplan, MD.

Chronic disseminated candidiasis or Hepatosplenic candidiasis (HSC) is a rare and potentially morbid and mortal complication encountered in febrile neutropenic patients. It is generally associated with recovery from neutropenia, and may occur after the treatment of an episode of acute hematogenous candidiasis. Clinical signs and symptoms include fever unresponsive to antibiotics, abdominal pain and tenderness, and hepatosplenomegaly. Laboratory examination shows negative blood cultures and elevated hepatic enzymes. Multiple abscesses were seen in the liver, spleen, lung, and kidneys. Immediate recognition of this complication and initiation of appropriate treatment is crucial to control the infection and decrease morbidity and mortality.<sup>1</sup>

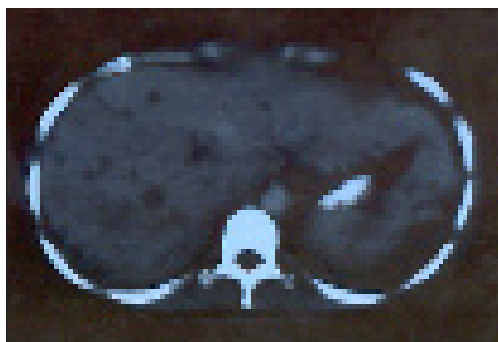A 27-year-old female was admitted to our clinic with the diagnosis of acute myeloblastic leukemia M2 in February 2005. Cytosine arabinoside (ara-C) and Daunorubicin were administered as standard remission induction treatment. 100mg/m<sup>2</sup> of Ara-C for 7 days and 45 mg/m<sup>2</sup> of Daunorubicin for 3 days were administered. Complete remission was achieved on the 14th day of treatment. In March 2005, a high dose of ara-C was administered for post-remission consolidation therapy. Although blood, sputum, and urinary cultures were negative, imipenem was administered empirically. On thorax CT, ground-glass opacity was detected in the apico-posterior and inferior lingular segment of the left lung and anterobasal segment of the lower lobe of the right lung. Caspofungin was administered in the dose of 70 mg on the first day and 50 mg for subsequent days for the persistency of fever and tomographic findings. In the recovery period of neutropenia, she suffered from right and left upper abdominal pain, nausea, and vomiting. High levels of alkaline phosphatase (ALP) and bilirubin (3.77 mg/dl) persisted. Remission was determined with bone marrow aspiration during this period. She was reevaluated with abdominal ultrasonography and tomography; hepatosplenomegaly, and multiple hypodense lesions with a maximal size of 2 cm in diameter were detected (Figure 1). She was considered as possible hepatosplenic candidiasis according to the

guidelines of the European Organization for Research and Treatment of Cancer, and the Mycosis Study group.<sup>2</sup> The liver biopsy could not be performed due to dismissal of the patient. The symptoms resolved on the 15th day of caspofungin administration. She was improved clinically, and the size of the liver and spleen reduced. In the same period, the level of ALP was not reduced, and radiologic findings resolved completely. Fluconazole was started in the dose of 400 mg/day subsequent to clinical recovery. She was followed as an outpatient. In clinical follow up, she was hospitalized 4 times for postremission chemotherapy. Five mg/kg amphotericin B was used in the neutropenic period, and discontinued after discharge. Lesions resolved completely in the spleen and partially in the liver in the abdominal CT on the 9th month of treatment (Figure 2).

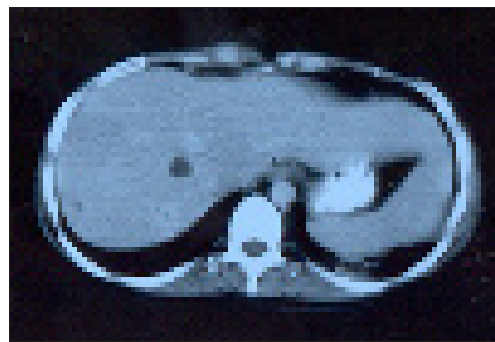
Invasive fungal infections have a poor prognosis due to late diagnosis, uncontrolled underlying disease, and lack of effective nontoxic treatment. Typically, the recognition and diagnosis of HSC are established in the remission period. The optimal first-line treatment for serious chronic disseminated candidiasis is a controversial issue. Until recently, Azoles and Amphotericin B were the traditional agents in the management of HSC. Management of invasive fungal infections has recently benefited from the development of new anti-fungal agents. Caspofungin is the first approved agent from a new class of antifungals, and displays potent in vitro and in vivo activity against a wide range of yeast and fungi, including most clinically relevant *Candida* and *Aspergillus* species. The echinocandins inhibit the synthesis of  $\beta$ -1,3-D-Glucan, an essential component of the cell wall of many pathogenic fungi, including *Candida Caspofungin*, which is equal to, or more potent than the azoles itraconazole and fluconazole, the new triazoles voriconazole, posaconazole and amphotericin B against *Candida albicans*, and *glabrata* and *tropicalis*.<sup>3</sup>

In 2001, caspofungin was licensed for the treatment of the following fungal infections; invasive candidiasis in adult patients, invasive aspergillosis in adult patients who are refractory to or intolerant to both amphotericin and itraconazole, empirical therapy for presumed fungal infections (such as *Candida* or *Aspergillus*) in febrile, and neutropenic adult patients.<sup>4</sup> Mora-Duarte et al,<sup>5</sup> reported that caspofungin was effective for the treatment of invasive candidiasis, more specifically, candidemia. The favorable response was found as 71.7%, and the percentage of patients with a favorable outcome was higher in the caspofungin group than amphotericin B group

## Clinical Notes



**Figure 1** - Abdominal computerized tomography showing hepatosplenomegaly and multiple hypodense lesions with a maximal size of 2 cm in diameter.



**Figure 2** - Abdominal computerized tomography showing completely resolved lesions in the spleen and partially in the liver on the 9th month of treatment.

in patients with candidemia. Nivoix et al,<sup>6</sup> reported that the success of adding a caspofungin to azoles or amphotericin B in patients that were previously unresponsive to other antifungals was 71%. When compared with amphotericin B, caspofungin was more cost-effective, and drug-related adverse events were less frequent.

Few data are available on the use of caspofungin in the treatment of HSC. In our limited experience, caspofungin is an effective and well-tolerated drug for the initial treatment of invasive candidiasis, and no side effects were detected during a long time period.

Received 30th January 2006. Accepted for publication in final form 22nd March 2006.

From the Department of Hematology - Oncology, Internal Medicine, Dicle University, Turkey. Address and reprint request to Assist. Prof. Abdullah Altintas, Internal Medicine, Department of Hematology - Oncology, Dicle University, 21280, Diyarbakir, Turkey. Tel. +90 (412) 2488233. Fax. +90 (412) 2488440. E-mail: draaltintas@dicle.edu.tr

## References

1. Sallah S, Semelka B, Kelekis N, Worawattanakul S, Salah W. Diagnosis and monitoring response to treatment of hepatosplenic candidiasis in patients with acute leukemia using magnetic resonance imaging. *Acta Haematol* 1998; 100: 77-81.
2. Ascioğlu S, Rex JH, de Pauw B, Bennett JE, Bille J, Crokaert F, et al. Defining opportunistic invasive fungal infections in immunocompromised patients with cancer and hematopoietic stem cell transplants: An international consensus. *Clin Infect Dis* 2002; 34: 7-14.
3. Maertens J, Boogaerts M. Caspofungin in the treatment of candidosis and aspergillosis. *Int J Infect Dis* 2003; 7: 94-101.
4. Keady S, Thacker M. Caspofungin in the treatment of invasive fungal infections. *Intensive Crit Care Nurs* 2006; 22: 59-62.
5. Mora-Duarte J, Betts R, Rotstein C, Colombo AL, Thompson-Moya L, Smietacoma J, et al. Comparison of Caspofungin and Amphotericin B for Invasive Candidiasis. *N Engl J Med* 2002; 347: 2020-2029.
6. Nivoix Y, Zamfir A, Lutun P, Kara F, Remy V, Lioure B, et al. Combination of caspofungin and an azole or an amphotericin B formulation in invasive fungal infections. *J Infect* 2006; 52: 67-74.