

# Effects of salmon calcitonin on fracture healing in ovariectomized rats

Xiaolin Li, MD, PhD, Xinle Luo, MD, Nansheng Yu, MD, Bingfang Zeng, MD.

## ABSTRACT

**Objectives:** To explore the effects of salmon calcitonin on the healing process of osteoporotic fractures in ovariectomized rats.

**Methods:** We performed this study in The First Affiliated Hospital of Guangzhou Medical College, Guangzhou, China, during the period March 2002 to December 2004. We used 120 female adult Wistar rats in this experiment, among which 90 underwent ovariectomy (OVX) and the other 30 had sham-operation. All rats had their left tibias fractured 3 months later. The 90 OVX rats were randomly divided into 3 groups with 30 in each, while the 30 sham-operated rats served as control group. After the fracture the rats had subcutaneous injection of normal saline, salmon calcitonin and estrogen, respectively. X-ray film, histological examination, bone mineral density (BMD) measurement and biomechanics testing were carried out to evaluate the fracture healing.

**Results:** Compared with OVX rats treated with normal saline, the rats with salmon calcitonin had significantly higher BMD values in the left tibia, higher max torque, shear stress of the left tibia 8 weeks after fracture ( $p < 0.05$ ), and presented with stronger callus formation, shorter fracture healing time and faster normalization of microstructure of bone trabeculae.

**Conclusions:** Salmon calcitonin can, not only increase BMD in osteoporotic bone, but also enhance the bone biomechanical properties and improve the process of fracture healing in fractured osteoporotic bone.

*Saudi Med J 2007; Vol. 28 (1): 60-64*

*From the Department of Orthopedic Surgery (Li, Zeng), Shanghai Sixth People's Hospital, Shanghai Jiao Tong University, Shanghai, Department of Orthopedic Surgery (Luo, Yu), The First Affiliated Hospital of Guangzhou Medical College, Guangzhou, China.*

*Received 21st May 2006. Accepted 9th September 2006.*

*Address correspondence and reprint request to: Dr. Bingfang Zeng, Department of Orthopedic Surgery, Shanghai Sixth People's Hospital, Shanghai Jiao Tong University, 600 Yishan Road, Shanghai 200233, China. Tel. +86 (21) 64369181. Fax. +86 (21) 64701361. E-mail: bingfangz@yahoo.com.cn*

Low bone mass and deterioration of bone micro-architecture are the major characteristics of osteoporosis, which results in decreased bone strength and an increased risk for fracture.<sup>1,2</sup> Salmon calcitonin has been widely used for the treatment of postmenopausal osteoporosis.<sup>3-5</sup> In the Prevent Recurrence of Osteoporotic Fractures trial carried out in the United States, Chessnut et al<sup>6</sup> found that 5-year treatment with calcitonin at a dosage of 200 IU per day reduced the risk of new vertebral fractures by 33% in postmenopausal women with established osteoporosis. It is believed that salmon calcitonin inhibits bone resorption, reduces bone mass loss and relieves bone pain without the side effects of estrogen.<sup>7,8</sup> Although it has been well documented that calcitonin can enhance the bone density for those fractured bones,<sup>9</sup> whether this agent can improve the bone quality, including the construction and biomechanical functions, requires further investigation. In this study, female adult Wistar rats had ovariectomy (OVX) and were then used as osteoporosis model to explore the effects of salmon calcitonin on the bone mass and fracture healing process.

**Methods.** This study was carried out in The First Affiliated Hospital of Guangzhou Medical College, Guangzhou, China, during the period March 2002 to December 2004. The experimental protocol received approval from the Medical Ethical Committee of the First Affiliated Hospital of Guangzhou Medical College.

One hundred and twenty female Wistar rats, aged 6 months, weighted 280±30 grams and without copulation (Guangdong laboratory animal center, Guangdong, China), were involved in this study. Rats were housed on a 12-hour light/dark cycle in an environmentally controlled room maintained at a temperature of 20-26°C, a relative humidity of 40-70%. A high calcium (1.5%) intake diet and water were available ad libitum.

All the 120 rats were anesthetized by intraperitoneal injection of 1% pentobarbital sodium (30 mg/kg) and had their bilateral ovaries exposed. Ninety rats then underwent bilateral OVX and the other 30 rats had their ovaries left alone (sham operation).

Three months after operation, all the rats were anesthetized again with the same manner to have their left tibias fracture at the middle segment artificially with the use of a 3-point bending device and then the intramedullary fixation was made by inserting K-wires from tibia tubercle. The position and characteristics of fractures were confirmed radiographically immediately after surgery. In the period from 1 week before and 8 weeks after fracture, the rats had subcutaneous injection of different solutions, according to the design of the experiment.

The 90 rats with OVX were randomly subdivided into 3 groups with 30 in each for experimentation. Group A had subcutaneous injection of salmon calcitonin (Beijing Novartis Pharma Ltd, 2 IU/Kg once daily),<sup>10</sup> group B had subcutaneous injection of estrogen (0.1 mg/kg once every 3 days)<sup>11</sup> and group C had subcutaneous injection of normal saline once daily. The 30 rats with sham operation were treated with normal saline once daily and served as the controls (group D).

Bone mineral density (BMD) ( $\text{g}/\text{cm}^2$ ) of the midshaft of the left tibia were measured before and 8 weeks after fracture by Hologic QDR 2000 dual-energy x-ray bone densitometer with the small animal software (Hologic, Waltham, MA, USA). The whole body was scanned with the Hologic rat whole body scan protocol (version 4.76), in which the lumbar spine was analyzed as a subregion of interest, the left tibia was scanned with the Hologic rat subregion Hi-res scan protocol (version 4.76).

The plain x-ray films of the fractured tibias were taken at 2, 4 and 8 weeks after internal fixation, respectively. At the end of the study, all the radiographs of each rat were evaluated blindly by 2 orthopedic surgery residents using the scoring system introduced by Severns et al,<sup>12</sup> which ranged the callus formation from 0 to 4 as follows: 0-No callus; 1-Minimal callus; 2-Callus evident but healing incomplete; 3-Callus evident and stability expected (clinically healed); and 4-Complete healing with bone remodeling complete. The mean radiologic score was calculated for each group.

Each group had 6 rats sacrificed at 2, 4 and 8 weeks after tibia fracture and internal fixation. Immediately after sacrifice, 4 fracture calluses were selected from each treatment group for histologic examination. The tissue samples were fixed in 10% buffered formalin, decalcified, sectioned longitudinally through the fracture site, embedded in paraffin, and stained with hematoxylin and eosin.

A single blinded observer examined the stained slides and the fracture calluses were graded according to the relative amounts of fibrous tissue, cartilage, woven bone, and mature bone.<sup>13</sup> Grade 1 indicated fibrous tissue; Grade 2 indicated predominantly fibrous tissue

with some cartilage; Grade 3 indicated equal amounts of fibrous tissue and cartilage; Grade 4 indicated all cartilage; Grade 5 indicated predominantly cartilage with some woven bone; Grade 6 indicated equal amounts of cartilage and woven bone; Grade 7 indicated predominantly woven bone with some cartilage; Grade 8 indicated entirely woven bone; Grade 9 indicated woven bone and some mature bone; and Grade 10 indicated lamellar (mature) bone. Four slides were examined from each fracture. The mean value of histological grade was calculated for each group.

The torsion and shear but 3-point bending testing were carried out to detect the changes in the bone as the fractured tibias had been intramedullary fixed with Kirschner wires. All the remaining rats were sacrificed 8 weeks after fracture, and the soft tissues were removed from each harvested tibia. The tibias were stored in gauze soaked in normal saline solution at  $-20^\circ\text{C}$ . Before testing, the specimens were thawed completely at room temperature for 2 hours. Both bone ends were embedded in liquid methyl methacrylate coagulant (Shanghai Dental Material Factory, 9299) and powdery methylmethacrylate coagulant (The Oral Cavity Material Factory, Shanghai Second Medical University, 881124). The embedded bulks were loaded onto the MTS 858 Bionix test system (Minneapolis, MN, USA). A 15-mm section of tibia centered on the fracture was exposed. A custom jig ensured consistent alignment of the bony axis with the axis of the testing machine. Specimens were tested to failure in torsion at room temperature on testing machine at a rate of  $5^\circ$  per second with no axial load.

Differences in the BMD values, the mean torsional strength and torsional stiffness among each group were analyzed using the Student t test. Differences in the radiographic scoring results were analyzed statistically using a one-way Kruskal-Wallis analysis of variance on Ranks with group as a factor. Statistical analysis was performed with Statistical Package for Social Sciences 10.0 software (SPSS/PC Inc., IL, USA). A  $p < 0.05$  was considered statistically significant.

**Results.** Measured 8 weeks after fracture, the BMD values of the tibial fracture sites in group A or group B were significantly higher than those measured just before fracture with P values being less than 0.05 (Table 1). In group D, the BMD values of the left tibia before and after fracture showed no significant difference. However, the BMD value continually and significantly decreased 8 weeks after fracture in group C ( $p < 0.05$ ).

On the serial x-ray examinations performed 2, 4 and 8 weeks after fracture, compared with the group C, an abundant callous formation and earlier bone union were observed in the same stage at the fracture sites in

group A (Figure 1). The same results were also found in the group B and group D. At all the 3 examined time points, the scores of callus formation and bone remodeling in group A, B and D were significantly higher than that in group C ( $p < 0.05$ ) (Table 2).

Two weeks after fracture, fibrous callus, some cartilaginous callus and a few primitive trabeculae were observed at the fracture sites in group A, group B and group D, whereas few such changes were seen in group C. Four weeks after fracture, woven bone formation was found around the edge of cartilaginous callus, and the primitive trabeculae were replaced by mature trabeculae in all animals except for the rats group C, in which there was only sparsely and deranged trabecular formation. Eight weeks after fracture, the transition from cartilaginous callus to bony callus occurred in group A, group B and group D, while the maturation of trabeculae delayed in group C. The values of histological grade in group C at different time points were significantly lower than that in the other 3 groups ( $p < 0.05$ ) (Table 2) (Figure 2).

The torque and stiffness of the left tibia in group A, group B and group D were significantly higher than those in group C ( $p < 0.05$ ). However, no significant

differences in the torque and stiffness of the left tibia existed among the former 3 groups (Table 3).

**Discussion.** The OVX rats are widely accepted as an animal model for the investigation on osteoporosis.<sup>5,14-16</sup> This model combines the easy manageability of rats with the main features of postmenopausal osteoporosis in women. Bone changes in rats and women during the early stages of estrogen deficiency are qualitatively similar, both exhibiting rapid cancellous bone loss associated with increased bone turnover.<sup>17</sup> Hence, the OVX rats model were employed in this experiment, too. When a significant decrease of BMD was found in all the ovariectomized rats 3 months after ovariectomy, it was confirmed that an optimal osteoporotic rat model was successfully established. Then their left tibias were fractured, serving as the model to study the healing progress in osteoporotic fracture. Since the bone remodeling process is coupled with the OVX induced acute estrogen deficiency, estrogen administration was done to some OVX rats, thus serving as a positive control. Estrogen affects bone by acting directly on its related receptors, which are located on osteoblasts and osteoclasts. Estrogen causes a depletion in number of the osteoclasts cells on bone by inhibiting the maturation

**Table 1 -** Alteration of bone mineral density of the left tibia of rats.

Group	Bone mineral density (g/cm <sup>2</sup> , mean ± SD)	
	Before treatment	After treatment
A (n = 12)	0.5259 ± 0.0693	0.5491 ± 0.0948*
B (n = 12)	0.5468 ± 0.0386	0.5665 ± 0.0397*
C (n = 12)	0.5024 ± 0.0412	0.4893 ± 0.0435
D (n = 12)	0.5861 ± 0.0491	0.5882 ± 0.0378*

A - ovariectomy (OVX) + salmon calcitonin; B - OVX + estrogen; C - OVX + normal saline; D - sham + normal saline  
 $p < 0.05$ , vs group C

**Table 3 -** Torsion test indexes of the left tibia of rats.

Group	Torque	Stiffness
	(N.m, means ± SD)	(N.m/degree, means ± SD)
A (n = 12)	0.85 ± 0.07*	0.13 ± 0.01*
B (n = 12)	0.87 ± 0.05*	0.15 ± 0.01*
C (n = 12)	0.66 ± 0.08	0.07 ± 0.04
D (n = 12)	0.82 ± 0.03*	0.16 ± 0.01*

A - ovariectomy (OVX) + salmon calcitonin; B - OVX + estrogen; C - OVX + normal saline; D - sham + normal saline  
Compared with the values obtained from group C  $p < 0.05$ .

**Table 2 -** Radiographic score and histological grade of the left tibia.

Group	Radiographic score (means ± SD)			Histological grade (means ± SD)		
	2 weeks (n=6)	4 weeks (n=6)	8 weeks (n=12)	2 weeks (n=6)	4 weeks (n=6)	8 weeks (n=6)
A	0.22 ± 0.02*	3.02 ± 0.09*	3.49 ± 0.20*	2.3 ± 0.9*	7.5 ± 0.5*	9.0 ± 0.8*
B	0.19 ± 0.07*	2.85 ± 0.12*	3.71 ± 0.31*	2.0 ± 0.5*	7.3 ± 0.3*	9.2 ± 0.5*
C	0.08 ± 0.04	1.80 ± 0.23	2.63 ± 0.14	1.5 ± 0.7	5.3 ± 0.6	6.8 ± 0.3
D	0.24 ± 0.08*	2.99 ± 0.17*	3.54 ± 0.42*	1.9 ± 0.3*	7.9 ± 0.8*	9.5 ± 0.5*

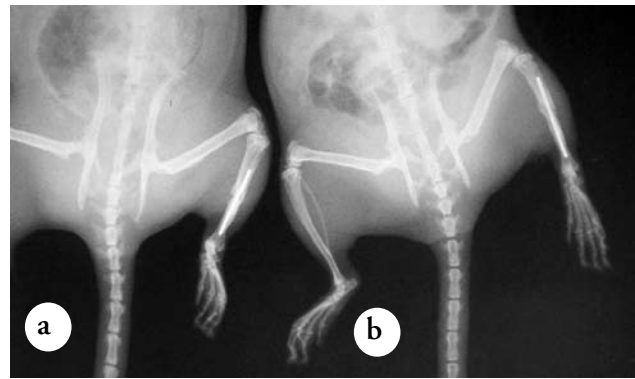
A - ovariectomy (OVX) + salmon calcitonin; B - OVX + estrogen; C - OVX + normal saline; D - sham + normal saline, \* $p < 0.05$ , vs group C

at the cell level. The major action of estrogen is in the suppression of bone loss.<sup>18</sup> However, the stimulating role of estrogen in bone formation is still controversial.<sup>19</sup> The use of hormone replacement therapy (HRT) has some restrictions due to the potential risks of breast cancer, venous thromboembolism, migraine, coronary heart disease and strokes.<sup>20</sup> Calcitonin has been shown to be a good alternative in treatment of postmenopausal osteoporosis.<sup>21</sup> The basic action of calcitonin is also inhibition of bone resorption. It is believed that the binding of calcitonin and its receptor on osteoclasts reduces the number and life-span of osteoclasts by inducing apoptosis, which, in turn, inhibits the bone resorption.<sup>3,22,23</sup> Femtomolar calcitonin concentrations inhibit the resorptive function of mature osteoclasts, with quiescence being followed by margin retraction. These kinetically separable morphological changes are exerted through separate cAMP- and Ca<sup>2+</sup>-dependent signaling pathways involving distinct G proteins.<sup>24,25</sup> In this study, the bone densitometry measurements of the lumbar vertebrae showed that calcitonin and estrogen treatments prevented the bone loss in OVX rats, but no significant increase in cancellous bone volume was observed, being similar to the previous studies.<sup>26,27</sup>

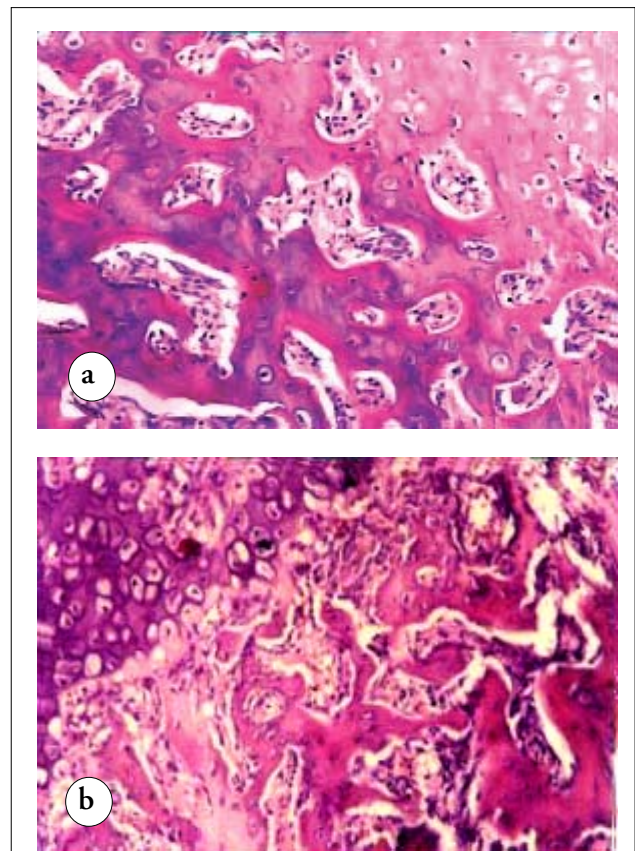
The cancellous bone volume is a very important impact factor for fracture healing in the osteoporotic model, as its loss is the major characteristics of osteoporosis.<sup>28</sup> However, results of studies on the effect of calcitonin on the cancellous bone volume have been controversial. Several studies have shown that the bone mass loss in experimental osteoporosis can be reversed by calcitonin treatment,<sup>29,30</sup> while the others have failed to confirm this effect.<sup>31,32</sup>

There is evidence of the direct effects of calcitonin on cartilage proliferation as well as the vascularization of the callus. Calcitonin is found to promote the cartilaginous phase of fracture healing. Several studies in animals and in humans, shown that salmon calcitonin administration has been found to have a beneficial effect on fracture healing.<sup>33</sup> In the present study, the x-ray and histological examination demonstrated stronger callus formation, shorter fractures healing and faster normalization of microstructure of the trabeculae in rats treated with salmon calcitonin than OVX rats receiving normal saline. Similarly, the biomechanical testing results revealed that max torque and shear stress in the rats treated with salmon calcitonin were significantly higher than those in OVX animals receiving normal saline, but similar to those in the rats treated with estrogen, indicating that calcitonin administration has at least the same effect as estrogen on improving the structure and strength of the osteoporotic bones.

In conclusion, salmon calcitonin can not only prevent bone loss in the osteoporotic rats, but also



**Figure 1** - X-ray photos of the fractured tibia 8 weeks after internal fixation. (a) An unclear but visible fracture line and sparsely callus formation were found in ovariectomize (OVX) rats receiving normal saline, implying that the fracture healing process was delayed. (b) In OVX rats with salmon calcitonin treatment, compacted callus was found while the fracture line was not visible, suggesting that the fracture was healed.



**Figure 2** - Callus histological examination of the fractured tibia 8 weeks after internal fixation. (a) At 8 weeks after fracture, compacted trabeculae and the transition of cartilage to bony callus were noted obviously in rats with salmon calcitonin treatment, (b) while the trabeculae were thin and deranged, and only cartilaginous callus was observed in ovariectomized rats receiving normal saline.

improve the process of fracture healing and enhance bone biomechanical properties of the fractured bone in OVX rats, suggesting that salmon calcitonin may be useful in prevention of osteoporosis and treatment of osteoporotic fractures.

## References

- Kleerekoper M. Prevention of postmenopausal bone loss and treatment of osteoporosis. *Semin Reprod Med* 2005; 23: 141-148.
- Wu XP, Liao EY, Zhang H, Dai RC, Shan PF, Cao XZ, et al. Determination of age-specific bone mineral density and comparison of diagnosis and prevalence of primary osteoporosis in Chinese women based on both Chinese and World Health Organization criteria. *J Bone Miner Metab* 2004; 22: 382-391.
- Munoz-Torres M, Alonso G, Raya MP. Calcitonin therapy in osteoporosis. *Treat Endocrinol* 2004; 3: 117-132.
- Lyritys G, Boscainos PJ. Calcitonin effects on cartilage and fracture healing. *J Musculoskelet Neuronal Interact* 2001; 2: 137-142.
- Mahakala A, Thoutreddy S, Kleerekoper M. Prevention and treatment of postmenopausal osteoporosis. *Treat Endocrinol* 2003; 2: 331-345.
- Chesnut CH, 3rd, Silverman S, Andriano K, Genant H, Gimona A, Harris S, et al. A randomized trial of nasal spray salmon calcitonin in postmenopausal women with established osteoporosis: the prevent recurrence of osteoporotic fractures study. PROOF Study Group. *Am J Med* 2000; 109: 267-276.
- McDermott MT, Kidd GS. The role of calcitonin in the development and treatment of osteoporosis. *Endocr Rev* 1987; 8: 377-390.
- Patel S, Lyons AR, Hosking DJ. Drugs used in the treatment of metabolic bone disease: Clinical pharmacology and therapeutic use. *Drugs* 1993; 46: 594-617.
- Nieves J, Komar L, Cosman F, Lindsay R. Calcium potentiates the effect of estrogen and calcitonin on bone mass: review and analysis. *Am J Clin Nutr* 1998; 67: 18-24.
- Salmon DM, Azria M, Zanelli JM. Decreased responsiveness to chronic salmon calcitonin treatment in rat kidney and calvaria studied using quantitative enzyme cytochemistry. *Acta Endocrinol (Copenh)* 1985; 108: 570-576.
- Qi MC, Zhou XQ, Hu J, Du ZJ, Yang JH, Liu M, et al. Oestrogen replacement therapy promotes bone healing around dental implants in osteoporotic rats. *Int J Oral Maxillofac Surg* 2004; 33: 279-285.
- Severns AE, Lee YP, Nelson SD, Johnson EE, Kabo JM. Metabolic measurement techniques to assess bone fracture healing: a preliminary study. *Clin Orthop Relat Res* 2004; 424: 231-238.
- Altman RD, Latta LL, Keer R, Renfree K, Hornicek FJ, Banovac K. Effect of nonsteroidal antiinflammatory drugs on fracture healing: a laboratory study in rats. *J Orthop Trauma* 1995; 9: 392-400.
- Jee WS, Ma Y. Animal models of immobilization osteopenia. *Morphologie* 1999; 83: 25-34.
- Davey RA, Morris HA. The effects of salmon calcitonin-induced hypocalcemia on bone metabolism in ovariectomized rats. *J Bone Miner Metab* 2005; 23: 359-365.
- Mizoguchi T, Nagasawa S, Takahashi N, Yagasaki H, Ito M. Dolomite supplementation improves bone metabolism through modulation of calcium-regulating hormone secretion in ovariectomized rats. *J Bone Miner Metab* 2005; 23: 140-146.
- Wronski TJ, Cintron M, Dann LM. Temporal relationship between bone loss and increased bone turnover in ovariectomized rats. *Calcif Tissue Int* 1988; 43: 179-183.
- Vaananen HK, Harkonen PL. Estrogen and bone metabolism. *Maturitas* 1996; 23: S65-S69.
- Abe T, Chow JMW, Lean JM, Chambers TJ. Estrogen does not restore bone lost after ovariectomy in the rat. *J Bone Miner Res* 1993; 8: 831-838.
- Writing Group for the Women's Health Initiative Investigators. Risks and benefits of estrogen plus progestin in healthy postmenopausal women: Principal results from the Women's Health Initiative randomized controlled trial. *JAMA* 2002; 228: 321-333.
- Munoz-Torres M, Alonso G, Raya MP. Calcitonin therapy in osteoporosis. *Treat Endocrinol* 2004; 3: 117-132.
- Martin TJ, Sims NA. Osteoclast-derived activity in the coupling of bone formation to resorption. *Trends Mol Med* 2005; 11: 76-81.
- Komarova SV, Shum JB, Paige LA, Sims SM, Dixon SJ. Regulation of osteoclasts by calcitonin and amphiphilic calcitonin conjugates: role of cytosolic calcium. *Calcif Tissue Int* 2003; 73: 265-273.
- Zaidi M, Datta HK, Moonga BS, MacIntyre I. Evidence that the action of calcitonin on rat osteoclasts is mediated by two G proteins acting via separate post-receptor pathways. *J Endocrinol* 1990; 136: 473-481.
- Chen Y, Shyu JF, Santhanagopal A, Inoue D, David JP, Dixon SJ, et al. The calcitonin receptor stimulates the tyrosine receptor phosphorylation and Erk1/2 activation. Involvement of Gi protein kinase C and calcium. *J Biol Chem* 1998; 273: 19809-19816.
- Geusens P, Boonen S, Nijs J, Jiang Y, Lowet G, Van Audekercke R, et al. Effect of salmon calcitonin on femoral bone quality in adult ovariectomized ewes. *Calcif Tissue Int* 1996; 59: 315-320.
- Zizic TM. Pharmacologic prevention of osteoporotic fractures. *Am Fam Physician* 2004; 70: 1293-1300.
- Dempster DW. The pathophysiology of bone loss. *Clin Geriatr Med* 2003; 19: 259-270, v-vi.
- Hayashi T, Yamamuro T, Okumura H, Kasai R, Tada K. Effect of (Asu1,7)-eel calcitonin on the prevention of osteoporosis induced by combination of immobilization and ovariectomy in the rat. *Bone* 1989; 10: 25-28.
- Peichl P, Marteau R, Griesmacher A, Kumpan W, Schedl R, Prosquil E, et al. Salmon calcitonin nasal spray treatment for postmenopausal women after hip fracture with total hip arthroplasty. *J Bone Miner Metab* 2005; 23: 243-252.
- Tuukkanen J, Jalovaara P, Vaananen K. Calcitonin treatment of immobilization osteoporosis in rats. *Acta Physiol Scand* 1991; 141: 119-124.
- Nakatsuka K, Nishizawa Y, Hagiwara S, Koyama H, Miki T, Ochi H, et al. Effect of calcitonin on total body bone mineral contents of experimental osteoporotic rats determined by dual photon absorptiometry. *Calcif Tissue Int* 1990; 47: 378-382.
- Lyritys G, Boscainos PJ. Calcitonin effects on cartilage and fracture healing. *J Musculoskelet Neuronal Interact* 2001; 2: 137-142.