

# Morel-Lavallee lesion

## *Results of surgical drainage with the use of synthetic glue*

Murat Demirel, MD, Ferit Dereboyl, MD, Ali Ozturk, MD, Egemen Turhan, MD, Tarik Yazar, MD.

### ABSTRACT

**Objectives:** To evaluate the results of surgical drainage and use of synthetic glue in Morel-Lavallee lesions.

**Methods:** We treated 7 Morel-Lavallee lesions in Ankara Bayindir Hospital, Ankara, Turkey between April 2003 and June 2004. These lesions developed in 5 male patients due to crush under a vehicle or a traffic accident. The mean age was 32.8 years; range 16-55. All lesions were localized in thigh. One patient had surgery due to acetabulum fracture and one had an urological operation for urethral rupture. All patients were operated 6-48 hours after the injury. After surgical drainage, soft tissues were attached with the use of synthetic glue and compressive bandage was applied. We defined healing as the loss of fluctuation and elicitation of the normal mobility of the injured skin on manual examination. The mean follow-up was 11.6 months (range 8-20 months).

**Results:** One patient was operated for acetabulum fracture and had a bilateral Morel-Lavallee lesion 2 days after the operation. This patient was reoperated for drainage. All lesions were healed with a mean of 5 weeks (range 3-8 weeks). No infection, necrosis or recurrences were detected during the follow-up.

**Conclusion:** Results of the treatment with the use of synthetic glue and surgical drainage in Morel-Lavallee lesion are satisfactory with early healing time without recurrence.

*Saudi Med J 2007; Vol. 28 (1): 65-67*

*From the Department of Orthopedics and Traumatology, Ankara Bayindir Hospital, Ankara, Turkey.*

*Received 15th April 2006. Accepted 17th September 2006.*

*Address correspondence and reprint request to: Dr. Murat Demirel, Turan Gunes Bulu 71.sok 14/5, Cankaya 06550, Yildiz Ankara, Turkey. Tel. +90 (312) 4428757. E-mail: perthes2000@yahoo.com*

Closed internal degloving is a significant soft-tissue injury associated with a pelvic trauma in which the subcutaneous tissue is torn away from the underlying fascia.<sup>1</sup> When this closed internal degloving occurs over the greater trochanter, it is known as a Morel-Lavallee lesion.<sup>1</sup> In the mid 19th century, Morel-Lavallee first thoroughly described this lesion as a traumatic detachment of skin from subjacent layers.<sup>1</sup> He thought that the accumulated fluid consisted of a blood serum concentrate resulting from small vessel shear.<sup>1</sup> Since his original description, the eponym has been applied to describe similar lesions in other and more distant anatomic sites.<sup>2</sup> The mechanism that causes the Morel-Lavallee lesion involves the application of violent, direct, and tangentially applied forces to the superficial integument over unyielding aponeurotic fascia.<sup>3</sup> Transaponeurotic vessels are subjected to shear, resulting in hematoma or lymphocele formation, further jeopardizing the vascular supply to the contused integument. Segmental vessel interruption renders the skin dependent on the randomly oriented dermal plexus. Peripheral vascular embarrassments with resultant gangrenous changes and secondary sepsis have been described as a potential sequelae. Predisposed detachable zones include the lumbodorsal fascia, gluteal region, and the anteroexternal and iliotibial tract regions of the thigh.<sup>3</sup> In the literature, management of lesions are variable. Conservative treatment and surgical procedures including small incision debridement and compression dressing application, tube drainage and some alternative therapeutic options, including aspiration, use of sclerosing agents, and internal drainage via surgical fascial fenestration can be considered only with caution.<sup>3-7</sup> We present the results of 7 Morel-Lavallee lesions in 5 patients managed with surgical drainage and use of synthetic glue.

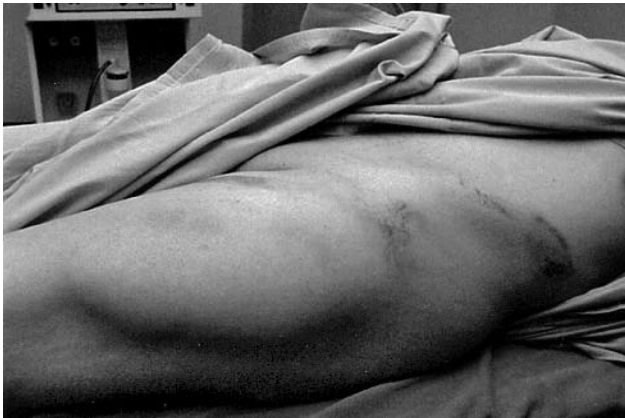**Methods.** Between April 2003 and June 2004, 5 patients with 7 Morel-Lavallee lesions were treated with surgical drainage and synthetic glue (Glubran 2, General Enterprise Marketing, Viareggio, Italy). All patients were male and aged between 16-55 years (average, 32.8 years). Three patients were struck under tire of bus (n=2) and tractor (n=1) (Figure

1) and the other 2 were traffic accidents. All lesions were localized in thigh. One patient with acetabular fracture was operated 3 hours after the injury. But during the follow-up bilateral Morel-Lavallee lesions occurred in thigh. Two days after the first operation, surgery was performed for these lesions. Another patient with Type A2.3 fracture according to Tile classification was operated due to urethral rupture. The other patients had no bony problems. We performed the procedures under general anesthesia. We performed surgical drainage with lateral longitudinal incision (Figure 2). All necrotic fat and hematoma were debrided and Glubran 2 was applied to the detached areas with equal distances. Cultures were taken from the lesion at the time of the operation. Average operation time was 30 minutes (range, 20-40 minutes). Compressive elastic bandage was applied to all patients. Vacuum drainage was left for 48 hours postoperatively. Patients were evaluated

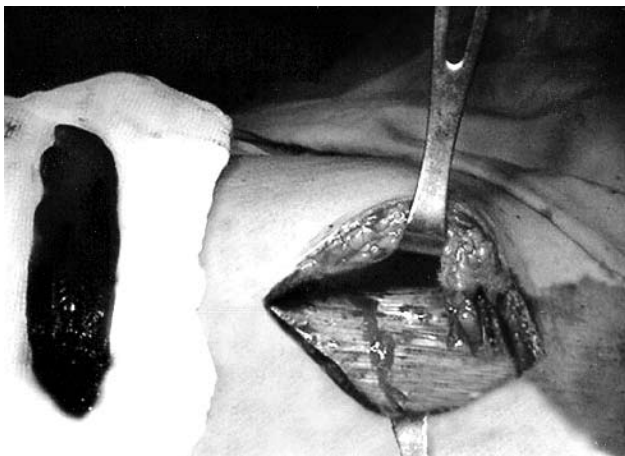
according to the loss of fluctuation and elicitation of the normal mobility of the injured skin on manual examination. The skin was checked for necrosis and infection (Figure 3). Mean follow-up was 11.6 months (range, 8-20 months).

**Results.** Re-operated patients with missed Morel-Lavallee lesions healed later when compared with others (left thigh 8 weeks, right thigh 6 weeks). Operated acetabular fracture was on the left side. Other patients with fracture also had long healing periods (right thigh 8 weeks, left thigh 6 weeks). Three patients without fracture healed with a mean of 3.3 weeks (range, 3-4 weeks). All lesions healed with a mean of 5 weeks (range 3-8 weeks). All cultures were negative. No infection, necrosis or recurrences were detected during the follow-up.

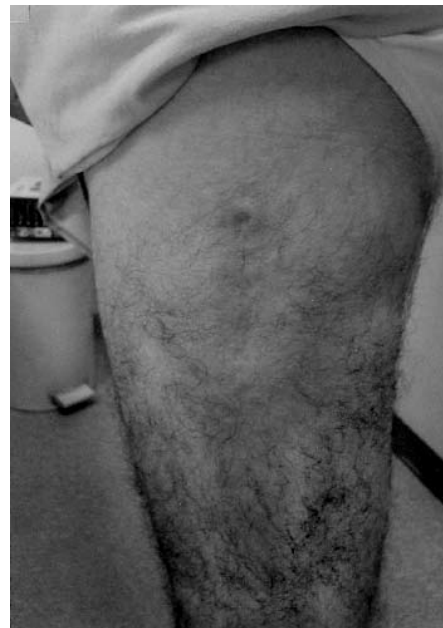**Discussion.** Closed degloving injuries are an uncommon clinical condition. When we look at the literature about closed degloving injuries, the number of patients were changing between 5 and 24.<sup>1,4,8-11</sup> Although the number in our study is small, promising results were obtained when these injuries were managed with synthetic glue. Glubran 2 surgical glue exerts an adhesive and hemostatic action on tissues. It is used in open and laparoscopic surgery and in treating digestive tract endoscopy, interventional radiology and vascular neuroradiology. It may be applied alone or in combination with sutures, even in patients being treated



**Figure 1** - Morel-Lavallee lesion located at the left thigh of the patient.



**Figure 2** - During the operation, all necrotic fat and hematoma were debrided. We can easily see the detachment of skin from subjacent layers.



**Figure 3** - After the operation the skin was checked for necrosis and infection.

with heparin and in hypothermia. Closed internal degloving injuries may occur in association with pelvic and acetabular fractures but may also occur in the absence of any fractures.<sup>4</sup> A history of direct crush to the pelvis or high-speed motor vehicle crash is common. In our study, 2 patients had fracture and both of them were trapped under the tires of vehicles. Various methods have been suggested for the treatment of these degloved areas, including conservative treatment, aspiration, injection of sclerosing agents such as tetracycline, deep fascial fenestration, compression dressings, and prolonged closed surgical drainage.<sup>3-7</sup> To our knowledge there are no reported case in the literature using synthetic glue for treatment of ML. It has been reported that primary closure of the degloved area has resulted in a high incidence of complications, including reaccumulation of hematoma, wound breakdown, and infection.<sup>3,8</sup> In the present study, we did not observe complications although the primary closure was performed. The mean healing time was varying between 3 and 12 weeks.<sup>10,11</sup> In this study, the mean healing time was 5 weeks (range 3-8 weeks). Longer healing periods were seen in the patients with fracture and struck under tire. The greater the initial trauma and accompanying fracture is the later the healing of the wound is.

The results of the treatment with the use of synthetic glue and surgical drainage in Morel-Lavallee lesion are satisfactory with early healing time without recurrence. We recommend this alternative technique for the patients with large lesions accompanying with fracture.

## References

1. Hak DJ, Olson SA, Matta JM. Diagnosis and management of closed internal degloving injuries associated with pelvic and acetabular fractures: the Morel-Lavallee lesion. *J Trauma* 1997; 42: 1046-1051.
2. Bertrand JCH, Guilbert F, Couly G, Descrozailles JM, Vaillant JM. The equivalent of the Morel-Lavallee syndrome in the cheek associated to a fistula of Stensen's duct. *Rev Stomatol Chir Maxillofac* 1978; 79: 295-301.
3. Kottmeier SA, Wilson SC, Born CT, Hanks GA, Iannacone WM, DeLong WG. Surgical Management of Soft Tissue Lesions Associated With Pelvic Ring Injury. *Clin Orthop* 1996; 329: 46-53.
4. Hudson DA, Knottenbelt JD, Krige JEJ. Closed degloving injuries: results following conservative surgery. *Plast Reconstr Surg* 1992; 89: 853-855.
5. Letts RM. Degloving injuries in children. *J Pediatr Orthop* 1986; 6: 93-97.
6. Helfet DL, Schmeling GJ. Complications. In: Tile M, editor. *Fractures of the Pelvis and Acetabulum*. 2nd ed. Baltimore (MD): Williams and Wilkins; 1995. p. 451-467.
7. Matta J. Surgical treatment of acetabular fractures. In: Browner BD, Jupiter JB, Levine AM, Trafton PG, editors. *Skeletal Trauma*. Philadelphia (PA): WB Saunders; 1992. p. 899-922.
8. Hudson DA. Missed Closed Degloving Injuries: Late Presentation as a Contour Deformity. *Plast Reconstr Surg* 1996; 98: 334-337.
9. Letournel E, Judet R. *Fractures of the Acetabulum*. 2nd ed. Berlin, Germany: Springer-Verlag; 1993 p. 363-397
10. Harma A, Inan M, Ertem K. The Morel-Lavallee lesion: A conservative approach to closed degloving injuries. *Acta Orthop Traumatol Turc* 2004; 38: 270-273.
11. Zhang K, Li BC, Gao JM. Management of extensive closed internal degloving injury in lower limb and peripelvis. *Chin J Traumatol* 2003; 6: 254-256.