

# Can saline be an alternative to aesthetic surgery in extended breast quadrantectomy?

Maha SA. Abdel Hadi, FRCSI, FACS.

## ABSTRACT

**Objective:** To explore other simpler options sparing the patients the morbidity and cost in extended breast quadrantectomy.

**Methods:** This prospective study was undertaken at King Fahd Hospital of the University, Al-Khobar, Eastern Province of Saudi Arabia between 1999-2005. Factors considered for patients undergoing breast-conserving surgery were based on age, tumor size, pathological characteristics, and patient's preference. Frozen section was adopted in all procedures to insure negative margins. After extended quadrantectomy, 200-400 cc was injected into the cavity to retain breast contour. Magnetic resonance imaging was used for postoperative assessment.

**Results:** Twenty-four patients were included, aged 28-43 years and tumor size 3-5 cms. All margins were negative on frozen section. The contour of the breast was restored with saline, MRI was employed for follow up at the immediate post operative period and at 4-6 months, it demonstrated restored breast contour and the saline filled cavity replaced by lipo-fibrous tissue. Follow up after 4-24 months showed that all patients noticed some degree of asymmetry, yet were satisfied with the result, none required or requested additional surgery.

**Conclusions:** In large tissue excisions injecting saline into cavities temporarily prevents the caving in of the redundant skin, which has the tendency to permanently adhere to the fascia thereby preventing gross deformities. It has proven effective, contour storing and scored high satisfaction among patients. It certainly does not replace cosmetic breast surgery, however, it should be considered in centers where onco-plastic surgery is not readily available.

*Saudi Med J 2007; Vol. 28 (2): 201-205*

*From the Department of Surgery, King Fahd Hospital of the University, Al-Khobar, Kingdom of Saudi Arabia.*

*Received 24th April 2006. Accepted 19th September 2006.*

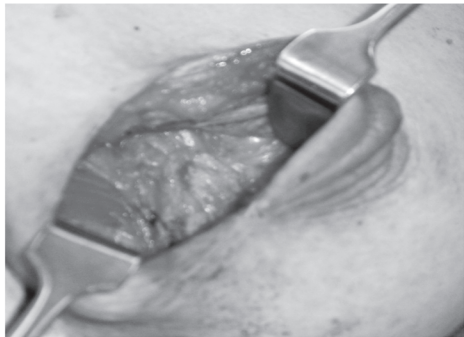*Address correspondence and reprint request to: Dr. Maha SA. Abdel Hadi, PO Box 40293, Al-Khobar 31952, Kingdom of Saudi Arabia. Tel. +966 505843710. E-mail: abdelhadi\_m@hotmail.com*

Breast conserving surgery (BCS) has gained popularity over recent years giving hope to breast cancer patients sparing them the agony and morbidity of the mutilating effects of mastectomy with and without reconstruction. Thus, the use of lumpectomy and irradiation is fundamentally based on cosmetic concern: that any amputation of a body part can cause severe distress without an attendant increase in survival.<sup>1</sup> Despite this, currently many surgeons still adopt mastectomy in patients with breast cancer based on personal or patients' preference, or they are considered non eligible for BCS as in cases where extended quadrantectomy would have been a feasible option, mastectomy tends to dominate in an attempt to avoid the obvious deformity resulting from the extensive tissue loss. Cosmetic surgery for breast cancer is the most appealing option, especially in our set up due to young age at presentation, thus helping to restore the patient's confidence and self-esteem. A modified reconstructive contouring in extended quadrantectomy is usually needed, such as breast prosthesis or modified mammoplasty. Here, a simpler option is explored, filling the cavity with saline helps temporarily to keep the cavity open and prevents caving in of the loose redundant skin thereby temporarily retaining the breast contour until the process of tissue remodeling takes place. This option may help reduce prolonged procedures' and risks however small.

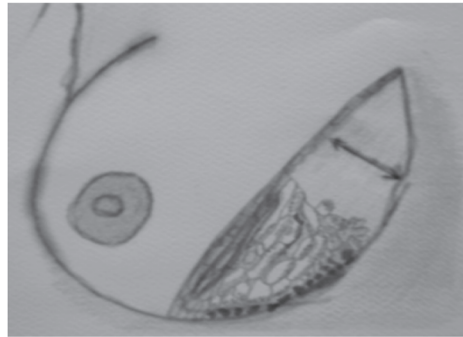
**Methods.** This prospective study was undertaken at King Fahd Hospital of the University, Al-Khobar, Eastern Province of Saudi Arabia between 1999-2005. Considered factors for patients undergoing breast-conserving surgery were based on age, tumor size, pathological characteristics, and patient's preference. Strictly adhering to the ethical guidelines for research, the patients were fully informed and consented regarding the details of the procedure. Twenty-four patients were included, they underwent extended

excision of the affected quadrant down the pectoral fascia (Figure 1). The margins were evaluated with frozen section to insure negativity. Hemostasis was then meticulously secured within the cavity. Closure was performed using interrupted absorbable size 4/0 (Dexon) for the subcutaneous tissue and non absorbable 4/0 (Dermalone) for the skin, only leaving a small opening for the plastic cannula to be inserted at the edge of the wound for saline introduction to fill the cavity. Then 200-400 cc of saline dependent on the size of the cavity was injected, which is expected to be absorbed and replaced by the therapeutic seroma (Figure 2a). Axillary lymph node dissection was performed through a separate incision. Hospital stay ranged between 1-3 days. All patients were advised to wear external support to avoid the dragging sensation produced by the heavy saline filled cavity for 4-6 weeks until the created therapeutic seroma is absorbed, and tissue remodeling takes place. Clinical examination and MRI were both employed for post operative assessment and follow up on outpatient basis. All patients underwent postoperative adjuvant therapy. Chemotherapy started 2 weeks after surgery in the form of 4-6 cycles each 3 weeks apart, followed by radiotherapy.

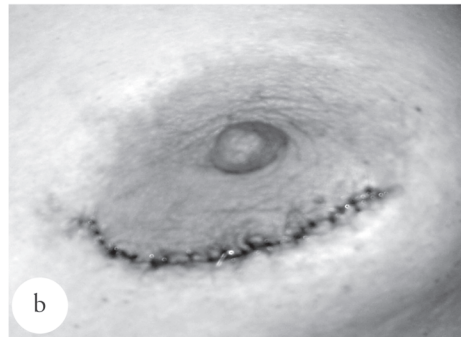
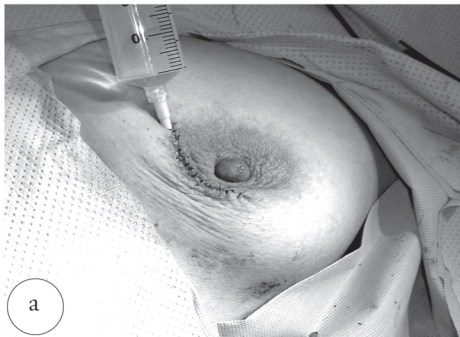**Results.** Twenty-four patients underwent extended quadrantectomy with intra-operative saline injections. All patients elected to undergo breast-conserving surgery if feasible. Age ranged between 28-43 years, tumor size ranged 3-5 cms. All margins were negative on frozen section. The contour of the breast was restored with saline (Figure 2b), which prevented the redundant skin from caving in and adhering to the chest wall (Figure 3). Follow up with MRI at immediate post operative period (Figures 4a & 4b) T2 images axial and sagittal views have demonstrated the saline filling the cavity restoring the breast contour. Further, at 4-6 months follow up have shown mild-moderate degrees of asymmetry yet, breast contour is preserved. Saline was completely absorbed and the cavity has been filled by lipo-fibrous tissue. (Figures 5a & 5b). All patients underwent further treatment with adjuvant chemo and radiotherapy, there were no reported complications or change of the radiation dosimetry. At 4-24 months follow up, all patients noticed some degree of asymmetry in the form of difference in size and mild to moderate deformities, yet all were satisfied with the end result and none requested or required further cosmetic surgery (Figure 6).



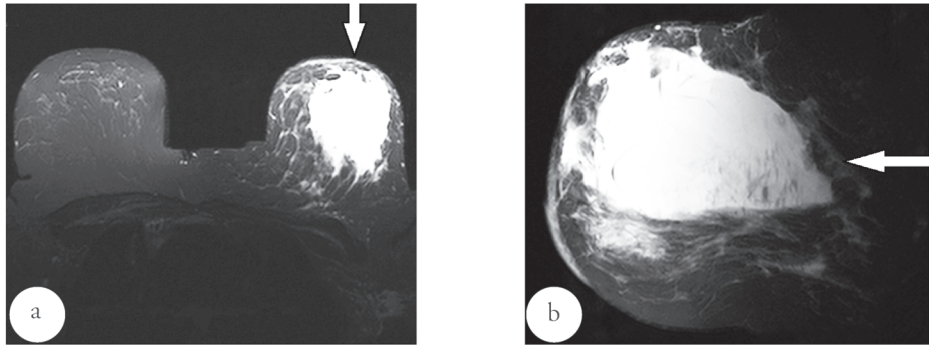
**Figure 1** - Breast cavity created after extended quadrantectomy.



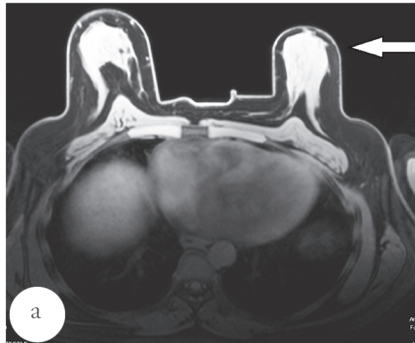
**Figure 3** - Filling the cavity with saline keeps the skin from caving in and adhering to the chest wall.



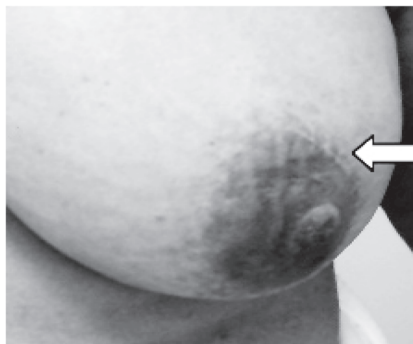
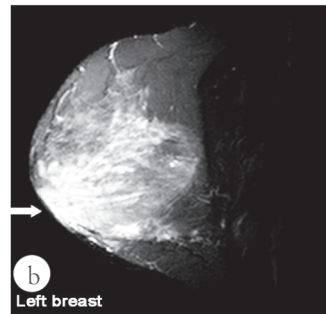
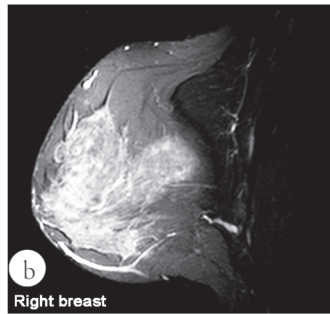
**Figure 2** - a) Saline injected to fill the collapsed cavity, and b). Breast contour retained as the cavity is filled with saline.



**Figure 4** - a) MRI in 42-year-old: T2 weighted images with fat suppression in the axial view demonstrating the cavity filled with saline in the left breast in the immediate post operative period. b) MRI (same patient) T2 weighted images with fat suppression demonstrating the same cavity filled with saline in the sagittal view.



**Figure 5** - a) MRI in a 33-year-old: T2 weighted images axial view demonstrating the complete absorption of the saline and cavity replacement by lipo-fibrotic tissue 4 months after surgery with noted asymmetry and the preserved breast contour. b) MRI (same patient) IR T2 weighted images sagittal views comparing the appearance between the right (normal) breast and the left (post surgery) breast showing the absence of the cavity and preserved breast contour.



**Figure 6** - One year post operative and adjuvant therapy images from a patient showing completely healed peri-areolar scar with mild breast asymmetry.

**Discussion.** With the rapidly evolving field of cosmetic surgery, the horrifying fear of breast cancer mutilating surgery outcome is slowly fading, thus rendered one of the main pillars in the multidisciplinary approach to breast cancer management. Breast conserving surgery has gained popularity over recent years with its reduced morbidity and cost, yet volume loss following BCS is the key reason for major local deformity and a poor cosmetic outcome. There are no or few reports in the literature on the use of free saline for breast contour preservation. This is presumably due to the scientific knowledge that saline will rapidly be absorbed leaving the cavity to collapse deforming the breast. Contrary to that fact, saline is gradually being absorbed by the raw surfaces, yet serum is also being concurrently secreted thereby retaining the cavity open for a longer period of time forming a therapeutic seroma preventing the redundant skin from caving in and adhering to the chest wall until natural tissue remodeling takes place. The rationale behind this technique is to offer a simple, quick and safe procedure with shortened hospital stay in centers where plastic specialty services are not available.

Many concerns have been raised in obtaining acceptable cosmesis without compromising the margin status. The 3-D ultrasound navigation system was developed in order to achieve a good cosmetic result without increasing the risk of ipsilateral breast cancer recurrence after BCS, thereby minimizing the resection volume of the breast without compromising the negativity of the surgical margins.<sup>2</sup> Pre-operative planning of the estimated tissue loss, placement of incisions, fish-tailing of quadrantectomy scars, utilization of reduction mammoplasty incisions and immediate replacement of defects after wide excision are useful in obtaining good aesthetic results.<sup>3</sup> Assessed points post BCS such as breast size, ptosis, nipple-areola position, shape, scar appearance, contour deformity, and skin changes were noted in some studies. It was also documented that 86% of patients were satisfied with the cancer treatment outcome, yet all patients noted asymmetry.<sup>4</sup> It is well documented that wide excision and axillary dissection followed by breast radiation could provide adequate local control, but frequently resulted in breast deformity. However, transposition of adipose tissue may be useful to correct the breast deformity; especially in women with small breasts.<sup>5</sup> Many procedures have been created to improve cosmetic outcomes. The double-team approach (plastic surgeons and oncologists) to BCS may improve the final cosmetic result following large tumor excisions. It can also extend the indications for breast preserving surgery. Moreover, it allows surgical and histological exploration of the contra lateral breast when a surgical procedure for symmetry is required. The BCS should

provide similar quality of local control as mastectomy and avoid psychological distress due to mutilation.<sup>6</sup>

Latissimus dorsi miniflaps can be used to reconstruct central and upper quadrant resection defects, replacing the volume excised with autogenous tissue. Partial mastectomy, axillary dissection, flap harvest and reconstruction of the resection defect are performed as a one-stage procedure through a single lateral incision. This oncoplastic approach allows extensive local excision during BCS without cosmetic penalties in a group of patients normally treated by mastectomy.<sup>7</sup> The BCS is widely accepted as an appropriate method of primary treatment of T1 and T2 breast cancers. For safe and cosmetically acceptable breast-conserving therapy in patients with larger breast cancers, the tumor volume has to be reduced preoperatively, and lost tissue volume should be replaced after wide local excision. However, BCS can be adopted in cases combining preoperative irradiation, and immediate myocutaneous (myosubcutaneous) latissimus dorsi flap reconstruction is an oncologically safe and cosmetically rewarding but logistically straining modality of treatment of relatively large T2 and T3 breast cancers.<sup>8</sup> With the geographic and ethnic variation, surgical and radiation oncologists face the potential dilemma of treating women with BCS who have large or extremely pendulous breasts. Several reported series have suggested that mammoreduction combined with breast conserving treatment yields better results.<sup>1</sup> The use of oncoplastic techniques and concomitant symmetrization of the contra lateral breast allows extensive resections for conservative treatment of breast carcinoma and results in favorable oncologic and esthetic outcomes. It adds to the oncological safety of breast-conserving treatment as a larger volume of breast tissue can be excised and a wider negative margin can be obtained.<sup>9</sup> Many reconstructive surgery techniques have been adopted in order to improve the outcome of the mastectomized patients. A recent study has shown for both immediate and delayed reconstruction the suspension technique using a nonabsorbable mesh to create a superior abdominal cutaneous flap. The advantage of this technique is the opportunity to use immediately a definitive prosthesis, also in cases requiring a mastectomy with the resection of a large amount of skin, consequently reducing the indications of tissue expanders or myocutaneous flaps. The integration of oncoplastic techniques with a concomitant contra lateral symmetrization procedure is a novel surgical approach that allows wide excisions and prevents breast deformities.<sup>10</sup> Cosmetic breast implants have become increasingly popular throughout the world. However, there is insufficient knowledge regarding the frequency and severity of local complications such as rupture and capsular contracture. The recent employment of MRI in

diagnosis of breast pathology is under extensive study. For breast implants, it suggested the use of a rigid image evaluation protocol with employment of well-defined rupture criteria.<sup>11</sup>

Another study has also concluded that MRI is highly accurate for identification of silicone breast implant rupture, with a high sensitivity and specificity when evaluation of images are based on presence of well-defined rupture criteria.<sup>12,13</sup> Whole breast irradiation following lumpectomy has become the standard treatment in women undergoing BCS. Cosmesis is also considered with administering high dose irradiation. Recent reports have suggested that in selected cases, accelerated partial breast irradiation may yield results equal to that of whole breast irradiation. More than 90% had a good or excellent overall cosmetic outcomes.<sup>14</sup> Despite this overwhelming success, a few setbacks started to surface. It has been reported that the post radiation sarcoma incidence has increased over recent years.<sup>15</sup> Other studies suggested that women more than 55 years derive less benefit from radiation in terms of reduced rates of local recurrence, while other reports have suggested that irradiation should be eliminated in elderly women above the age of 70 years.<sup>16,17</sup>

In conclusion, cosmesis plays an integral part in breast cancer surgery. Considering the young age at presentation in our set up, BCS is the first treatment option, followed by other cosmetic options adopted in mastectomized patients. Saline injections into the cavity are adopted temporarily to prevent the gross deformities resulting from the adherence of the redundant skin to the chest wall until the process of tissue remodeling takes place. It minimizes scarring in case further cosmetic surgery is planned. In addition, it has proven safe, effective, contour storing, with reduced hospital stay and cost. Moreover, satisfaction score is high among patients. It should be considered and adopted in centers where the onco-plastic team approach is not readily available.

**Acknowledgments.** *Special thanks to Miss Dina Lutfi a multi-media student at the American University of Sharjah for pencil illustration, to Prof. Fatma Al-Mulhim and Dr. Abdullah Y. Al-Hassan, Department of Radiology KFHU for MRI comments.*

## References

- Goffman TE, Schneider H, Hay K, Elkins D, Schnarrs R, Carman C. Cosmesis with bilateral mammoreduction for conservative breast cancer treatment. *Breast J* 2005; 11: 195-198.
- Inoue T, Tamaki Y, Sato Y, Nakamoto M, Tamura S, Tanji Y, et al. Three-dimensional ultrasound imaging of breast cancer by a real-time intraoperative navigation system. 2005; 12: 122-129.
- Shrotria S. Techniques for improving the cosmetic outcome of breast conservation surgery. *Eur J Surg Oncol* 2001; 27: 109-112.
- Bajaj AK, Kon PS, Oberg KC, Miles DA. Aesthetic outcomes in patients undergoing breast conservation therapy for the treatment of localized breast cancer. *Plast Reconstr Surg* 2004; 114: 1442-1449.
- Noguchi M, Minami M, Earashi M, Taniya T, Miyazaki I, Nishijima H, et al. Oncologic and cosmetic outcome in patients with breast cancer treated with wide excision, transposition of adipose tissue with latissimus dorsi muscle, and axillary dissection followed by radiotherapy. *Breast Cancer Res Treat* 1995; 35: 163-171.
- Petit JY, Garusi C, Greuse M, Rietjens M, Youssef O, Luini A, et al. The suspension technique to avoid the use of tissue expanders in breast reconstruction. *Ann Plast Surg* 2005; 54: 467-470.
- Rainsbury RM. Breast-sparing reconstruction with latissimus dorsi miniflaps. *Eur J Surg Oncol* 2002; 28: 891-895.
- Woerdeman LA, Hage JJ, Thio EA, Zoetmulder FA, Rutgers EJ. Breast-conserving therapy in patients with a relatively large (T2 or T3) breast cancer: long-term local control and cosmetic outcome of a feasibility study. *Plas Reconstr Surg* 2004; 113: 1607-1616.
- Kaur N, Petit JY, Rietjens M, Maffini F, Luini A, Gatti G, et al. Comparative study of surgical margins in oncoplastic surgery and quadrantectomy in breast cancer. *Ann Surg Oncol* 2005; 12: 539-545.
- Clough KB, Lewis JS, Couturaud B, Fitoussi A, Nos C, Falcou MC. Oncoplastic techniques allow extensive resections for breast-conserving therapy of breast carcinomas. *Ann Surg* 2003; 237: 26-34.
- Kulmala I, Boice JD Jr, McLaughlin JK, Holmich LR, Pakkanen M, Lassila K, et al. A feasibility study of magnetic resonance imaging of silicone breast implants in Finland. *J Long Term Eff Med Implants* 2005; 15: 9-14.
- Holmich LR, Vejborg I, Conrad C, Sletting S, McLaughlin JK. The diagnosis of breast implant rupture: MRI findings compared with findings at explantation. *Eur J Radiol* 2005; 53: 213-225.
- Caranelo AM, Marques AF, Smialowski EB, Lederman HM. Evaluation of the rupture of silicone breast implants by mammography, ultrasonography and magnetic resonance imaging in asymptomatic patients: correlation with surgical findings. *Sao Paulo Med J* 2004; 122: 41-47.
- Stolier AJ, Fuhrman GM, Scroggins TG, Boyer CI. Postlumpectomy insertion of the mammo site brachytherapy device using the scar entry technique: initial experience and technical considerations. *Breast J* 2005; 11: 199-203.
- West JG, Qureshi A, West JE, Chacon M, Sutherland L, Haghghi B, et al. Risk of angiosarcoma following breast conservation: a clinical alert. *Breast J* 2005; 11: 115-123.
- Veronesi U, Luini A, Del Vecchio M, Greco M, Galimberti V, Merson M, et al. Radiotherapy after breast-preserving surgery in women in localized cancer of the breast. *N Engl J Med* 1993; 328: 1587-1591.
- Hughes KS, Schnaper LA, Berry D. Lumpectomy plus tamoxifen with or without irradiation in women 70 years of age or older with early breast cancer. *N Engl J Med* 2004; 351: 971-977.