

Case Reports

Fatal congenital cytomegalovirus infection following recurrent maternal infection after a 7-year interval

U. Guney Ergun, MD, Sevgi Bakaris, MD, Hasan Ucmak, MD, Ayda Ozbek, MD.

ABSTRACT

It is generally accepted that the risk for fetal infection is greatest with maternal primary cytomegalovirus (CMV) infection and much less likely with recurrent infection. Here, we report a fatal case of congenital CMV infection following recurrent maternal infection after a 7-year interval. A 3-month-old female baby presented with fever, jaundice, vomiting and stopping breast-feeding. Physical examination revealed mild respiratory distress, hepatosplenomegaly, microcephaly and growth retardation. Laboratory examination included bilirubin concentrations (Total: 7.17 mg/dl; conjugated 6.67 mg/dl), aspartate transaminase (141 IU), and alanine transaminase (499 IU). Enzyme-linked immunosorbent assay test results revealed (+) CMV IgM and (+) CMV IgG. She died on the 10th day of admission with the diagnosis of CMV hepatitis, pneumonia, and multi-organ failure. Nuclear and cytoplasmic inclusions were demonstrated in the lung, liver and brain on postmortem biopsy. This case highlights that the outcome of babies born to mothers with recurrent maternal CMV infection may be more severe and fatal than previously thought.

Saudi Med J 2007; Vol. 28 (2): 264-267

From the Departments of Family Medicine (Ergun), Pathology (Bakaris), Infectious Disease (Ucmak), and Pediatrics (Ozbek), Medical Faculty, Kabramanmaras Sutcu Imam University, Kabramanmaras, Turkey.

Received 14th March 2006. Accepted 28th June 2006.

Address correspondence and reprint request to: Dr. U. Guney Ergun, Department of Family Medicine, Kabramanmaras Sutcu Imam University, Faculty of Medicine, 46100 Kabramanmaras, Turkey. Fax: +90 (344) 2212371. E-mail: guneyozzer@hotmail.com, guneyergun@yahoo.com

likelihood of fetal infection and the risk of associated damage is higher after a primary infection. The risk for fetal infection is greatest with maternal primary CMV infection (30%) and much less likely with recurrent infection (between 0.14-1%).^{1,2} Here, we describe a fatal case of congenital CMV infection following recurrent maternal infection even after a 7-year interval. By reporting this case, our objective was to draw attention to the outcome of babies born to mothers with recurrent maternal CMV infection, which may be more severe and fatal than previously thought.

Case Report. A 3-month-old female baby that presented with fever, jaundice, vomiting, and stopping of breast-feeding was hospitalized. Physical examination revealed mild respiratory distress, hepatomegaly, splenomegaly, microcephaly (head circumference <3rd percentile), and growth retardation (height <3rd percentile, weight 3-10 percentile). She was lethargic, and reflexes were loose. Laboratory examination included; hemoglobin of 10.4 g/dl, white blood cell of 12700/mm³, platelets of 385,000/mm³, and toxic granulation in blood smear. Total bilirubin concentration was 7.17 mg/dl (6.67 mg/dl conjugated), aspartate transaminase 141 IU, alanine transaminase 499 IU, gamma-glutamyl transpeptidase 358 IU, alkaline phosphatase 399 IU, blood urea nitrogen 9 mg/dl, and creatinine 0.7 mg/dl. Prothrombin time was prolonged. Urinalysis was insignificant. Blood-urine calcium was in the normal range. The evaluation of amino acids for metabolic disease in urine and blood was also normal. The abdominal ultrasonography demonstrated hepatosplenomegaly and dilatation of intrahepatic bile ducts. Ophthalmic examination was normal. Brain CT demonstrated microcephaly and periventricular calcifications. The enzyme-linked immunosorbent assay (ELISA) test results for toxoplasmosis, other, rubella, CMV and herpes (TORCH), HIV, and hepatitis A, B, C were determined as follows; CMV-specific IgM (+), CMV-specific IgG (+), rubella IgG (+), rubella IgM (-), toxoplasmosis IgG (+), toxoplasmosis IgM (-), hepatitis A virus (HAV) IgG (+), anti hepatitis B surface antigen

Cytomegalovirus (CMV) is one of the most common causes of congenital infections in developing countries with reported incidences varying between 0.15-2%. Congenital CMV infection can follow either a primary or recurrent maternal infection, but the

(HbsAg) (+), anti-hepatitis C virus (HCV) (-) and HIV (-). The symptomatic antimicrobial and antiviral (ganciclovir) treatment was started however, the condition of the baby worsened. She died on the 10th day of admission with the diagnosis of CMV hepatitis, pneumonia, and multi-organ failure. On postmortem biopsy, histological examination showed predominant damage in the liver, brain, and lung. Microscopically, a diagnosis of CMV infection was based on the presence of cytomegalic inclusion bodies (CIBs). The intranuclear amphophilic inclusion bodies surrounded by a clear halo, or basophilic granular cytoplasmic inclusion bodies were considered as CIB. The CIBs were noted in the brain, lung, and liver. The lesion in the liver was the presence of characteristic CIBs most typically seen in the bile duct epithelium. Other lesions included fatty degenerations, cholestasis, and interstitial and periportal fibrosis. Pulmonary interstitial infiltrate of mononuclear cells associated with the typical inclusions were observed in the lung. In the brain tissue, neurons were observed with cytomegaly and large nuclear inclusions (**Figure 1**).

She was born to a healthy 25-year-old mother of a consanguineous marriage. Her parents were second-degree cousins. They have an 8.5-year-old handicapped boy who has severe mental-motor retardation, epilepsy, sensorineural hearing loss and bilateral blindness. According to his medical records, his birth was uneventful

with a birth weight of approximately 3 kg. Subjectively, his development was reported by his parents as normal until 3 months of age. However, he was not evaluated in a health care center until the age of 3 months to confirm this report. When he was taken for immunization, his blindness was recognized by a primary care nurse. The ophthalmologic evaluation showed bilateral complicated cataract. His milestones were gradually delayed. During ongoing evaluations, it was found that he has bilateral sensorineural hearing loss. A brain CT demonstrated generalized cerebral atrophy, ventriculomegaly, and periventricular calcifications suggestive of an in-utero insult with infection. After clinical and laboratory evaluations, he was diagnosed with congenital CMV infection. At the age of 8 months, he presented with convulsions. His EEG demonstrated bilateral and generalized dysrhythmia with high voltage activity and epileptic deterioration in the centroparietal regions. The mother did not take any pre conceptional or prenatal care during her first pregnancy. With the diagnosis of their first offspring, both parents went through medical evaluation. Their ELISA test results for TORCH, HIV and hepatitis A, B, C demonstrated; CMV-specific IgG (+), CMV-specific IgM (-), rubella IgG (+), rubella IgM (-), toxoplasmosis IgG (+), toxoplasmosis IgM (-), HAV IgG (+), anti HbsAg (+), anti-HCV (-) and HIV (-). Being second-degree cousins, they went through

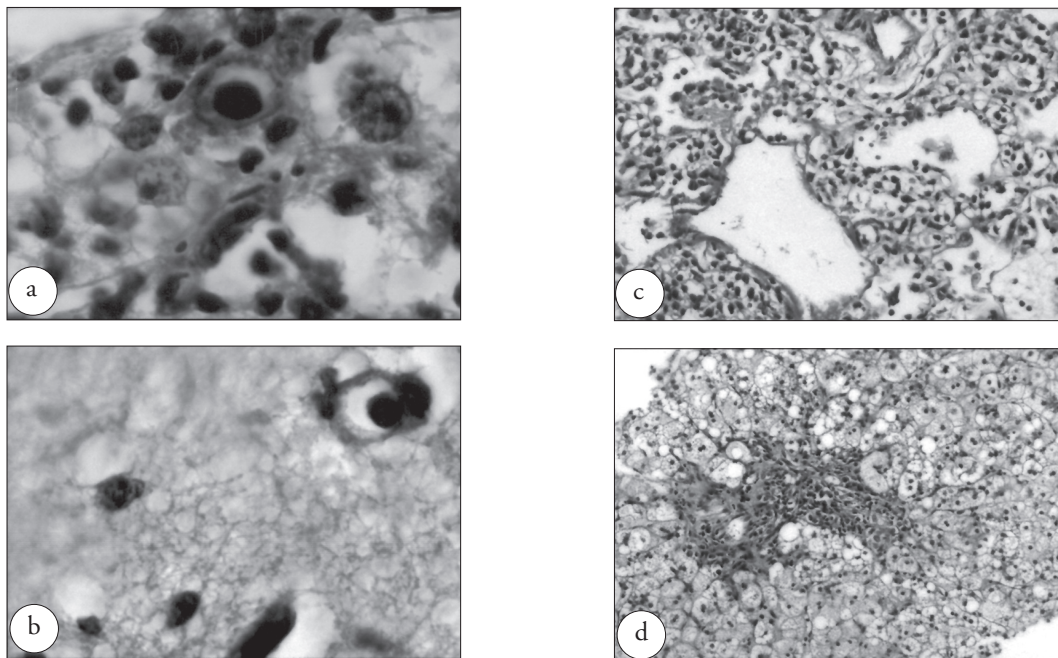


Figure 1 - Congenital cytomegalovirus infection. a & b) Bile duct and neuron with cytomegaly and large nuclear inclusions. c) Interstitial infiltrate in the lung associated with inclusions. d). Fatty metamorphosis, interstitial and periportal fibrosis.

genetic evaluation for certain genetic and metabolic diseases, which revealed normal results. They were informed regarding the situation of their son but there were not given any counseling for the next pregnancy. Although there was no suggestion, they waited 7 years before conception of another child, when she had a spontaneous abortion in the sixth week of her second pregnancy. She went to a health-care center after the abortion, but the reason was not properly evaluated. Approximately 2 months later, she became pregnant with her daughter, the present case. In the fifth week of her third pregnancy, she had complaints such as malaise, fatigue, and myalgia. She applied to a private office of a gynecologist and went through a medical evaluation. Being aware of the story of the first child, the doctor retested titers of IgG antibodies to CMV. It revealed relatively high (+) CMV IgG titers [102 AU/ml (positive ≥ 15)]. Although close prenatal care was suggested, she did not take any further care until the delivery. She continued her pregnancy uneventfully, and the baby was born asymptomatic after a term pregnancy. After the delivery, the baby was examined for routine metabolic screening. Due to being asymptomatic, she was not screened for CMV infection. She was discharged from the hospital with suggestions of follow-up. When she was taken for immunization at the age of 2 and half months, the primary care nurse realized that she had growth retardation and offered a medical evaluation. Two weeks later she presented with the symptoms discussed above.

Discussion. It is currently accepted that congenital CMV infection may be the consequence of either a primary or a recurrent maternal infection. Recurrent infections may consist of either reactivation of the virus strain causing primary infection or reinfection by a new virus strain. Recently, the incidence of symptomatic congenital CMV infections in immune mothers has been shown to be similar in primary and recurrent maternal infections.³ Maternal primary infection is defined by the presence of CMV-specific IgG and IgM antibodies in a patient who has been seronegative before the pregnancy, or with a significant rise in the IgG titer in the presence of IgM antibodies. Recurrent infection usually is defined as the presence of maternal antibody to CMV before conception and congenital CMV infection in the offspring. The presence for specific IgM antibodies in neonates is diagnostic of congenital infection.^{2,3} Unlike pre conceptional immunity against rubella or toxoplasmosis, pre conceptional immunity against CMV provides only partial protection from intrauterine transmission of the virus.⁴ The factors that are associated with intrauterine transmission of CMV in women with pre conceptional immunity have not

been defined. However, a recent study of mothers who were CMV seropositive before conception and transmitted the virus to their offspring revealed evidence that many of them had been infected with a new strain of CMV.⁵ Diagnosis of CMV in adults established by virus isolation, CMV antigen detection, CMV DNA detection, presence of CMV-specific IgM antibody, or a fourfold high rise in CMV-specific IgG antibody.⁶ In the present case, the mother was determined seropositive for CMV before the last 2 of 3 pregnancies. The first child of the family was diagnosed as congenital CMV infection according to the clinical findings and positive CMV-specific IgG antibodies. However, the mother did not take any pre conceptional care before the first pregnancy, thus, it would not possible to say whether the congenital infection was primary or recurrent for the first child. However, the mother was seropositive in the second pregnancy, in which the outcome was spontaneous abortion. Congenital CMV infection should be considered in cases of pregnancy loss.¹ The third pregnancy, the present case, occurred 2 months after the abortion and the CMV-specific IgG antibody titers were revealed six-fold high, where CMV-specific IgM was negative. Additionally, the presence of CMV-specific IgM antibodies and the periventricular calcifications were suggestive for recurrent congenital infection in the index patient. However, the distinction of re-infection or reactivation could not be determined due to economic concerns of the family.

The risk of transplacental transmission of CMV relative to the interval between primary maternal infection and conception has not been determined. The virus is excreted in urine and saliva for many months and may persist or be episodic for several years following primary infection.⁶ The association between a shorter interval between births and an increased rate of congenital CMV suggests that the risk of congenital CMV increases, even when primary maternal infection occurs months and years before conception.⁷ In the present case, the recurrence occurred approximately 7-8 years after the primary infection. Both the elevated serum titers of CMV-specific IgG antibody during the third pregnancy and the abortion of the second pregnancy were suggestive of recurrence. The transmission of CMV remained elevated for women with delivery intervals >48 months apart in a study,⁷ but there is no record that demonstrated 7-8 years of interval with fatal progression of recurrent congenital CMV infection. The effects of congenital CMV infection may vary from a congenital syndrome to an asymptomatic course. Ninety percent of infants with congenital infection have no signs or symptoms at birth. Approximately 10% of infected infants manifest significant clinical illness in the newborn period with a variety of manifestations,

including poor growth, microcephaly, jaundice, hepatosplenomegaly, anemia and thrombocytopenia, and almost all of these infants will go on to have later neurologic sequel. Even if asymptomatic at birth, approximately 5-17% will have neurodevelopmental abnormalities, including sensorineural hearing loss, which may only become apparent in infancy or later in childhood.⁸ It is generally accepted that symptoms of congenitally infected children are more severe after primary infection than after recurrent infection, but the outcomes of recurrent maternal CMV infection may be more severe than previously thought.^{3,9} Similarly, hepatosplenomegaly, microcephaly, growth retardation, CMV hepatitis, anemia, and pneumonia manifested in the infancy period in the present case although the baby was asymptomatic at birth. The presented symptoms were defined in the 3rd month, with a severe and fatal progression. The manifestation of primary and recurrent CMV infection was tragic for the particular family. The pre conceptional, antenatal, and postnatal care were not sufficient during all of the 3 pregnancies. Counseling of women with primary and recurrent CMV infection should be adjusted to offer prenatal diagnosis and high-level ultrasound controls due to the considerable risk for fetal infection and uncertainty of clinical outcome and disease.¹⁰ Unfortunately, prenatal detection of congenital disease by ultrasound examination is not sufficient, but prenatal diagnosis can be confirmed by amniocentesis. However, the number of mothers who underwent amniocentesis and the broad case definition used to define symptomatic disease is still not adequate.⁸

In summary, the present case reported a severe and fatal outcome of a recurrent maternal CMV infection after a 7-year interval. Until certain treatment¹¹ and vaccines¹² are developed, close pre conceptional and antenatal care should be promoted.

References

1. Brown HL, Abernathy MP. Cytomegalovirus infection. *Semin Perinatol* 1998; 22: 260-266.
2. Yamamoto AY, Mussi-Pinhata MM, Cristina P, Pinto G, Moraes Figueiredo LT, Jorge SM. Congenital cytomegalovirus infection in preterm and full-term newborn infants from a population with a high seroprevalence rate. *Pediatr Infect Dis J* 2001; 20: 188-192.
3. Boppana SB, Fowler KB, Britt WJ, Stagno S, Pass RF. Symptomatic congenital cytomegalovirus infection in infants born to mothers with preexisting immunity to cytomegalovirus. *Pediatrics* 1999; 104: 55-60.
4. Morris DJ, Sims D, Chiswick M, Das VK, Newton VE. Symptomatic congenital cytomegalovirus infection after maternal recurrent infection. *Pediatr Infect Dis J* 1994; 13: 61-64.
5. Boppana SB, Riviera LB, Fowler KB, Mach M, Britt WJ. Intrauterine transmission of cytomegalovirus to infants of women with pre conceptional immunity. *N Engl J Med* 2001; 344: 1366-1371.
6. Cytomegalovirus infection. Communicable Disease Management protocol. 2001. [cited 15 Dec 2005]. Available from: http://www.gov.mb.ca/cgi-bin/print_hit_bold.pl/health/publichealth/cdc/protocol/cyto.pdf.
7. Fowler KB, Stagno S, Pass RF. Interval between births and risk of congenital cytomegalovirus infection. *Clin Infect Dis* 2004; 38: 1035-1037.
8. Milewska-Bobula B. Congenital cytomegalovirus infection-clinical characteristics including prenatal diagnosis. *Med Wieku Rozwoj* 2003; 7: 123-127.
9. Gaytant MA, Steegers EA, Semmekrot BA, Merkus HM, Galama JM. Congenital cytomegalovirus infection: review of the epidemiology and outcome. *Obstet Gynecol Surv* 2002; 57: 245-256.
10. Daiminger A, Bader U, Enders G. Pre- and peri conceptional primary cytomegalovirus infection: risk of vertical transmission and congenital disease. *BJOG* 2005; 112: 166-172.
11. Kimberlin DW, Lin CY, Sanchez PJ, Demmler GJ, Dankner W, Shelton M, et al. National Institute of Allergy and Infectious Diseases Collaborative Antiviral Study Group. Effect of ganciclovir therapy on hearing in symptomatic congenital cytomegalovirus disease involving the central nervous system: a randomized, controlled trial. *J Pediatr* 2003; 143: 16-25.
12. Arvin AM, Fast P, Myers M, Plotkin S, Rabinovich R. Vaccine development to prevent cytomegalovirus disease: report from the National Vaccine Advisory Committee. *Clin Infect Dis* 2004; 39: 233-239.