

Mesenteric panniculitis

Imaging of a rare cause of chronic abdominal pain

Metab A. ALKubeyyer, MD, Turkey R. Alfuhaid, FRCR, FRCP(C).

ABSTRACT

We report a case of mesenteric panniculitis. This rare and poorly-known disease is characterized by a nonspecific inflammatory process involving the adipose tissue of the mesentery. This case illustrates its computerized tomographic and magnetic resonance imaging features and the value of imaging in differentiating it from other mesenteric diseases and thus, avoiding unnecessary surgery.

Saudi Med J 2007; Vol. 28 (2): 276-278

From the Department of Radiology, King Khalid University Hospital, Riyadh, Kingdom of Saudi Arabia.

Received 15th April 2006. Accepted 15th July 2006.

Address correspondence and reprint request to: Dr. Metab A. ALKubeyyer, Department of Radiology, King Khalid University Hospital, PO Box 86072, Riyadh 11622, Kingdom of Saudi Arabia. Tel. +966 (1) 4671155. Fax. +966 (1) 4671746. E-mail: dr.metab@gmail.com

Mesenteric panniculitis (sclerosing mesenteritis) is a rare inflammatory disorder of unknown etiology that involves the mesentery. Patients usually have vague and chronic symptoms. Hence, the diagnosis is usually first suggested by imaging techniques, particularly computerized tomography (CT) and magnetic resonance imaging (MRI) of the mesentery. Imaging also plays a key role in distinguishing the focal mass associated with mesenteric panniculitis from lymphoma and carcinoid. The objective of reporting this case is to stress the value of cross sectional imaging in making accurate diagnosis of this rare and poorly known disease.

Case Report. A 61-year-old Saudi gentleman presented with nausea and diffuse abdominal pain for 2 weeks. He had no history of fever or weight loss. Physical examination was remarkable for only a vague feeling mass in the left side of the abdomen.

Erythrocyte sedimentation rate (ESR) was elevated at 117 cm/hr. Ultrasound (US) of the abdomen was normal. Computerized tomography of the abdomen after intravenous and oral contrast administration revealed a 10 x 7 cm lobulated mass with subtle increased attenuation seated within the small bowel mesentery. The mesenteric vessels were only surrounded by this mass, namely; they were not kinked. While the small bowel was displaced due to this mass, its lumen was not dilated and its wall was not thickened, suggesting absence of secondary ischemia. There was no calcification within the mass. Lymphadenopathy was absent (Figure 1a & 1b). Magnetic resonance imaging of the mesentery confirmed the fatty and focal nature of the mesenteric mass with its nodular contour. The preservation of the fat around the patent mesenteric vessels within the mass was exquisite (Figure 2a, b & c). Based solely on the imaging features this mesenteric mass possessed, the diagnosis of mesenteric panniculitis was strongly suggested. The histopathology results of a specimen obtained utilizing CT guidance confirmed the diagnosis of mesenteric panniculitis. He was started on steroids. He followed a benign course with significant improvement of his complaints.

Discussion. Mesenteric panniculitis is an idiopathic inflammatory disorder that involves the mesentery.¹ It was first described by Jura in 1942 as sclerosing mesenteritis.² In the 1960s, the term mesenteric panniculitis was used by Ogden et al.^{3,4} The disease has a 3:1 male predilection in those above 50 years of age. Predisposing factors⁵ include, among others, abdominal surgery, cholelithiasis, cirrhosis, abdominal aortic aneurysm, peptic ulcer, gastric carcinoma, and retained suture material.⁶ Patients with this disease may present at any of the following 3 stages:^{7,8} 1) Mesenteric lipodystrophy. In this stage, the disease is usually asymptomatic. Nevertheless, patients may present with impairment of normal gastrointestinal function and chylous ascites. Prognosis is generally good with spontaneous recovery. 2) Mesenteric panniculitis. Patients often present with

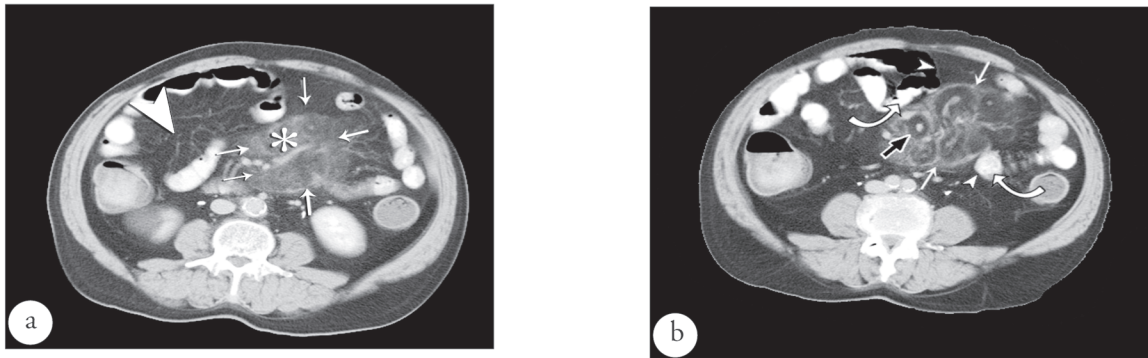


Figure 1 - Computerized tomographic findings. a) Axial CT scan of the mid abdomen with intravenous and oral contrast shows a mesenteric mass (arrows). The fatty component of the mass (*) is of a higher attenuation than the rest of the small bowel mesentery (arrow head). b) Another CT image of the mass (white arrows). The lobular contour of the mass is evident. Note the preservation of the fat around the patent mesenteric vessels, what is known as "Fat ring sign" (black arrow). Small bowel loops (curved arrows) are displaced due to the mass but with paper thin walls (arrow heads).

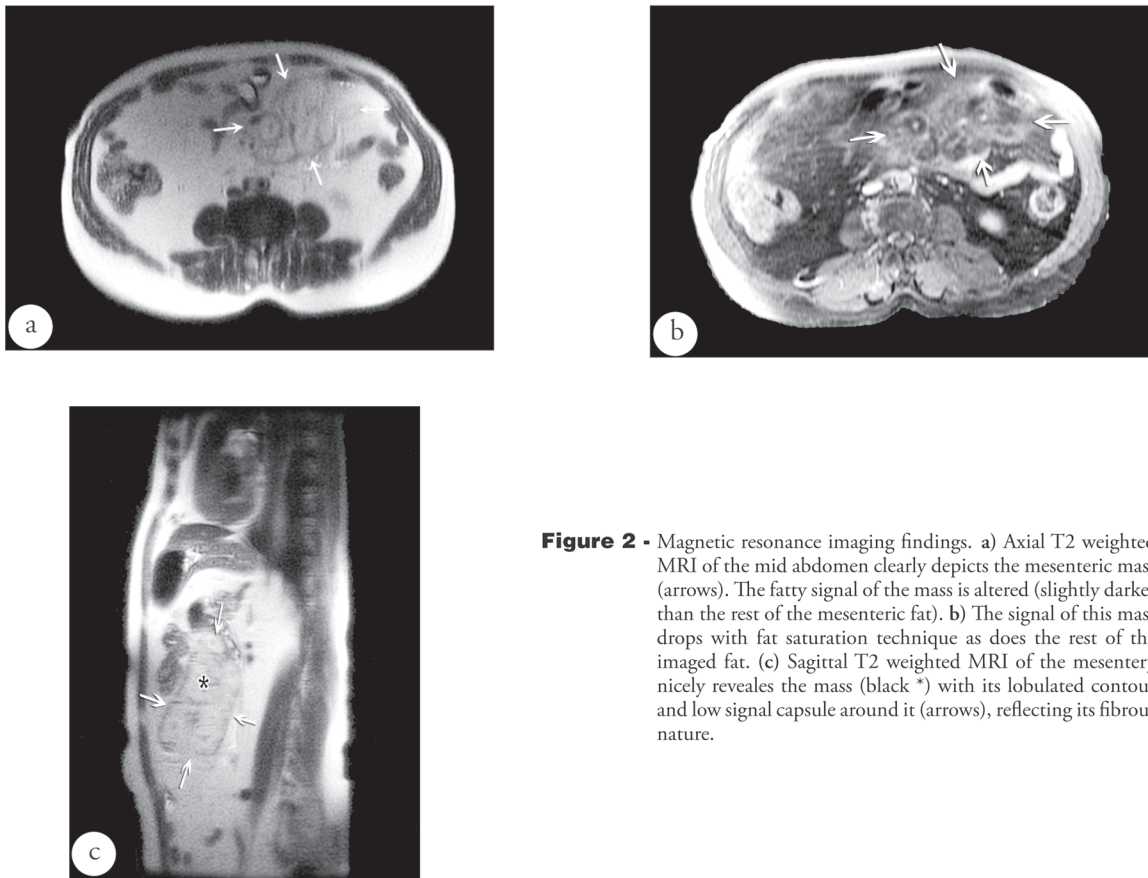


Figure 2 - Magnetic resonance imaging findings. a) Axial T2 weighted MRI of the mid abdomen clearly depicts the mesenteric mass (arrows). The fatty signal of the mass is altered (slightly darker than the rest of the mesenteric fat). b) The signal of this mass drops with fat saturation technique as does the rest of the imaged fat. (c) Sagittal T2 weighted MRI of the mesentery nicely reveals the mass (black *) with its lobulated contour and low signal capsule around it (arrows), reflecting its fibrous nature.

abdominal pain associated with nausea, malaise, low-grade fever, weight loss, and bowel disturbance. Some patients present with poorly defined mass. Small bowel mesentery is commonly involved. Laboratory chemical analysis may show elevated ESR. Steroid treatment is suggested by some authors to be beneficial. 3) The final stage is known as retractile mesenteritis. Patients often present with intestinal obstructive symptoms due to scarring and retraction of the mesentery resulting from mesenteric fibrosis

Chronic abdominal pain without a diagnosis is not uncommon and a challenging clinical scenario. These patients typically roam around with many visits to different clinics searching for a diagnosis. These patients should be imaged initially with US. If it fails to disclose the cause of the pain, we believe that these patients should undergo CT, which in many occasions answers the clinical question. The focal mass associated with mesenteric panniculitis should be distinguished from mesenteric masses associated with other diseases particularly lymphoma and carcinoid.⁹ Cross sectional imaging particularly CT and MRI of the mesentery are of paramount importance in noninvasively making this distinction. The density of the inflamed mesenteric fat is mildly increased on CT. The MRI, with its multiplanar capability and fat saturation technique, exquisitely reflects the fatty nature of the mass which is altered due to the inflammatory process. The high sensitivity of MRI to signal alteration helps in outlining the capsule surrounding the mass and depicting the preserved

fat surrounding the mesenteric vessels. The latter is known as the fat ring sign, which should point to the correct diagnosis of mesenteric panniculitis. Absence of mesenteric and paravascular lymphadenopathy helps in excluding lymphoma. If the diagnosis is still in doubt, US or CT are utilized to guide the biopsy procedure. By reporting this case, we emphasize the value of imaging in making an accurate diagnosis of this rare and poorly known disease.

References

1. Emory TS, Monihan JM, Carr NJ, Sobin LH. Sclerosing mesenteritis, mesenteric panniculitis and mesenteric lipodystrophy: a single entity? *Am J Surg Pathol* 1997; 21: 392-398.
2. Jura SV. Mesenterile retrattile e sclerosante. *Policlinica (Sez Prat)* 1924; 31: 575.
3. Ogden W, Bradburn DM, Rives JD. Mesenteric panniculitis. *Arch Surg* 1965; 161: 864-875.
4. Ogden WW 2nd, Bradburn DM, Rives JD. Panniculitis of the mesentery. *Ann Surg* 1960; 151: 659-668.
5. Durst AL, Freund H, Rosenmann E, Birnbaum D. Mesenteric panniculitis: review of the literature and presentation of cases. *Surgery* 1977; 81: 203-211.
6. Kipfer RE, Moertel CG, Dahlin DC. Mesenteric lipodystrophy. *Ann Intern Med* 1974; 80: 582-588.
7. Wexner SD, Attiyeh FF. Mesenteric panniculitis of the sigmoid colon: report of two cases. *Dis Colon Rectum* 1987; 30: 812-815.
8. Weiser J, Salky B, Dileman S. Laparoscopic diagnosis of retractile mesenteries. *Gastrointest Endosc* 1992; 38: 615-617.
9. Grossman LA, Kaplan HJ, Preuss HJ, Herrington JL Jr. Mesenteric panniculitis. *JAMA* 1963; 183: 318-323.

[Access www.smj.org.sa](http://www.smj.org.sa)

Saudi Med J Online features

- ✦ Instructions to Authors
- ✦ Uniform Requirements
- ✦ STARD
- ✦ Free access to the Journal's Current issue
- ✦ Future Contents
- ✦ Advertising and Subscription Information

All Subscribers have access to full text articles in HTML and PDF format. Abstracts and Editorials are available to all Online Guests free of charge.