

Coexisting malignant lymphoma of the duodenum and adenocarcinoma of the colon

Ali M. Al-Amri, MD, Abdulaziz A. Al-Quorain, MD.

ABSTRACT

Synchronous malignant mucosa associated lymphoid tissue (MALT)-lymphoma of the small bowel and adenocarcinoma of the colon in the same patient is a scarce rarity. Only few cases have been reported so far. Thus, it might be of interest to report such a case of coexisting malignant MALT-lymphoma of the duodenum and adenocarcinoma of the large bowel.

Saudi Med J 2007; Vol. 28 (3): 463-464

From the Department of Internal Medicine, King Fahd Hospital of the University, Al-Khobar, Kingdom of Saudi Arabia.

Received 30th April 2006. Accepted for publication in final form 29th July 2006.

Address correspondence and reprint request to: Dr. Ali Al-Amri, Consultant Internist/Oncologist, Department of Internal Medicine, King Fahd Hospital of the University, PO Box 40182, Al-Khobar 31952. Tel/Fax. +966 (3) 8966741. E-mail: aliamri49@hotmail.com

Collision tumors of the gastrointestinal tract are very rare. The coexistence of 2 malignant tumors (collision tumors) in one organ or system presents an interesting clinical and histological entity. Only few cases of such collision tumors are present in the world literature.¹⁻⁵ In this communication, we present a rare case of synchronous malignant lymphoma of the duodenum and adenocarcinoma of the large bowel.

Case Report. A 48-year-old Jordanian lady presented to our hospital complaining of fatigue, abdominal pain, constipation and bleeding per rectum for 5 months duration. She was also dyspeptic and anorexic. The physical examination revealed only pallor otherwise no abnormalities were detected, in particular, there were no palpable abdominal masses, hepatosplenomegaly; or lymphadenopathy. Rectal examination was normal. Routine laboratory investigations, including the tumor markers were all normal. Patient was subjected to upper gastrointestinal (GI) endoscopy, which showed chronic moderate active gastritis and a huge polypoid duodenal ulcer, located in the second part of the duodenum

(**Figure 1**). The gastric biopsy showed *Helicobacter pylori* (*H. pylori*) associated chronic moderate active gastritis, while the duodenal biopsy was consistent with low-grade lymphoma (B-cell type). CD20 and BCL2 were positive, while CD5, CD10, CD23 and cyclin D1 were negative. Virtual colonoscopy showed a growth located at 25-30 cm from the anal verge, leading to incomplete stenosis; the subsequent sigmoidoscopy revealed polypoid and ulcerative tumor causing significant narrowing, preventing further advancement of the scope (**Figure 2**). The histopathological evaluation of the biopsies obtained was consistent with moderately differentiated adenocarcinoma. The abdominal sonography and CT scan of abdomen and pelvis did not reveal any lymph node enlargement or metastatic lesions. The patient underwent surgical resection in the form of left sided hemicolectomy and primary anastomosis. Her postoperative course was unremarkable. The histopathological examination of the resected specimen revealed moderately differentiated adenocarcinoma of the colon, grade II, infiltrating through its wall with free surgical margins. Lymphatic invasions were confirmed in 9 out of the 13 removed pericolic lymphnodes. Finally, our patient was diagnosed with duodenal MALT-lymphoma stage I and adenocarcinoma of the colon stage III, T3N2MO.

Discussion. Synchronous primary gastric lymphoma and colonic adenocarcinoma in the same patient is a rare event and even rarer with MALT lymphoma of the duodenum. According to our knowledge there was no duodenal MALT lymphoma concomitant with colonic adenocarcinoma reported so far. The coexistence of multiple malignancies in one patient was first described by T. Billroth in 1860.⁴ The estimated rate of occurrence of these malignant diseases varies but its ranging from 2-7%.³⁻⁶ It is now accepted that *H. pylori* associated chronic active gastritis can

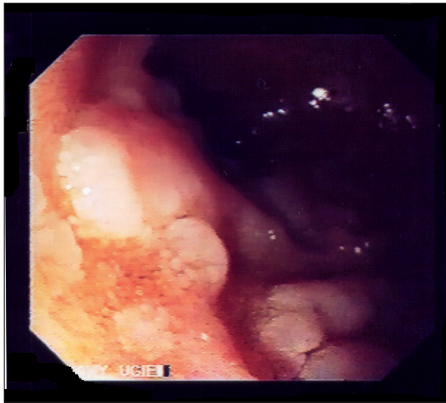


Figure 1 - Duodenal polypoid ulcerative lesions.

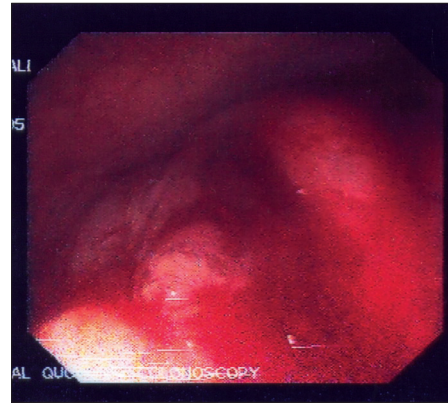


Figure 2 - Large and ulcerative tumor of the colon with partial obstruction.

predispose patients for development of gastric MALT lymphoma or gastric carcinoma.^{7,8} According to some reports, patients with *H. pylori* associated gastric cancer or duodenal maltoma are at high risk of developing other cancers, however, other reports did not show any increase of the incidence of other malignant disorders.⁸⁻¹⁰ The development of the duodenal MALT lymphoma in our patient might be due to metaplastic gastric mucosa in the duodenum which has been subsequently infected with *H. pylori*. After the surgical resection of the colonic tumor and her recovery, patient was treated with triple therapy aiming to eradicate the *H. pylori* infection. She was also advised to be treated according to the recommendation of the MOSAIC study which include the combination of 5-fluorouracil, leucovorin and oxaliplatin, aiming to target colon cancer stage III and the duodenal lymphoma.^{11,12} However, the patient refused to be treated and left the country seeking for a second opinion.

In conclusion, synchronous gastrointestinal tumors in the same patient are rare, in particular duodenal lymphoma and colonic adenocarcinoma. Patients with serious gastrointestinal symptoms should be subjected to extensive investigations including upper and lower GI-endoscopy in order to exclude coexisting malignancies.

References

- Mir-Madjlessi SH, Vafai M, Khademi J. Coexisting primary malignant lymphoma and adenocarcinoma of the large intestine in an IgA deficient boy. *Dis Colon Rectum* 1984; 27: 822-824.
- Cattel RB, Bohcme EJ. Importance of malignant degeneration as complication of chronic ulcerative colitis. *Gastroenterology* 1947; 8: 695-710.
- Cornes JS. Multiple primary cancers: primary malignant lymphomas and carcinoma of intestinal tract in the same patients. *J Clin Pathol* 1960; 13: 483-489.
- Ghose A, Dasgupta J, Konar A, Raha K, Basu PK, Mazumder DN. Collision tumor of gastrointestinal tract. *Indian J Gastroenterol* 1994; 13: 29-30.
- Barron BA, Localio SA. A statistical note on the association of colorectal cancer and lymphoma. *Am J Epidemiol* 1976; 104: 517-522.
- Quilon JM, Day S, Laskar JC. Synchronous tumor: Hodgkin disease presenting in mesenteric lymph nodes from right hemicolectomy for colon carcinoma. *Saudi Med J* 2004; 97: 1133-1135.
- Hussell T, Isaacson PG, Grabtree JE, Spencer J. The response of cells from low-grade B-cell gastric lymphoma of mucosa-associated lymphoid tissue to helicobacter pylori. *Lancet* 1993; 342: 571-574.
- Au WY, Gascoyne RD, Le N, Viswanatha DS, Klasa RJ, Gallagher R, et al. Incidence of second neoplasm in patients with MALT lymphoma: No increase in risk above the background population. *Annals of Oncology* 1999; 10: 317-321.
- Moertel CG, Dockerty MB, Baggenstoss AH. Multiple primary malignant neoplasms: Tumors of different tissues or organs. *Cancer* 1961; 14: 231-237.
- Moertel CG, Dockerty MB, Baggenstoss AH. Multiple primary malignant neoplasms: I. Introduction and presentation of data. *Cancer* 1961; 14: 221-230.
- Andre T, Boni C, Mounedji-Boudiaf L, Navarro M, Tabernero J, Hickish T, et al. Oxaliplatin, Fluorouracil, and Leucovorin as adjuvant treatment for colon cancer. *N Engl J Med* 2004; 350: 2343-2351.
- Raderer M, Wohrer M, Bartsch R, Prager G, Drach J, Hejna M, et al. Phase II study of oxaliplatin for treatment of patients with mucosa-associated lymphoid tissue lymphoma. *J Clin Oncol* 2005; 23: 8442-8446.