

Clinical Notes

Fracture and aspiration of metallic tracheostomy tube

Asghar Hajipour, MD, Zabid H. Khan, MD.

A 30-year-old male underwent craniotomy for a colloid cyst of the brain. In the intensive care unit, a tracheostomy was performed, and a metallic tube inserted at the end of the 3rd week. Inadvertently, the metallic piece of the tube got aspirated during routine suctioning (Figure 1). A semi urgent rigid bronchoscopy was planned. A number 7.5 cuffed armored endotracheal tube was inserted through the stoma after administering sufentanil 10 µg, midazolam 2 mg and lidocaine 100 mg intravenously. After verifying its proper position, induction of anesthesia was initiated with increasing concentration of halothane. Once the surgical anesthesia was achieved, oral rigid bronchoscopy was allowed. On reaching the trachea, the armored tube was withdrawn to allow the passage of the bronchoscope distally. From then onwards, oxygenation was maintained via the bronchoscope's proximal port. The metallic tube was successfully recovered and a plastic tracheostomy tube was inserted via the stoma. The patient had an uneventful postoperative course and discharged on the 10th postoperative day. Foreign bodies in the airway, pharynx and esophagus, continue to be a diagnostic and therapeutic challenge.¹⁻³ Despite improvement in emergency care and public awareness, foreign bodies result in numerous deaths per year from asphyxiation.⁴ The present report illustrates an unusual foreign body aspiration that, did not illicit much of symptoms, but was quickly recognized. Amongst the numerous complications associated with tracheostomy, fracture and aspiration of metallic tracheostomy tube segment is rare.⁵ This unusual case is important because it demonstrates the potential for aspiration of any broken part of tracheostomy tube, even at home care setting, particularly in patients needing long-term metallic tracheostomy tube in situ. Presentation could be delayed due to paucity of symptoms. A fractured tube segment may not interfere with air passage and thus remain quiescent for long periods, although it may cause a segmental/lobar consolidation, collapse or an abscess, due to mucus plugs in the lumen of the tube,⁵ if remains undiagnosed and not removed. Early breakages are actually detachment at the shield-tube junction due to manufacturing defects. Fractures after prolonged use are due to mechanical stress (repeated removal and insertion, cleansing, boiling) or chemical reactions with corrosive disinfectants and alkaline bronchial secretions. Atmospheric moisture and alkaline bronchial secretions react with copper on the zinc-copper alloy tube to form basic bicarbonate.⁶ The continued corrosion splits the metal, most frequently at the shield-tube/shield flange junction. In this case report,

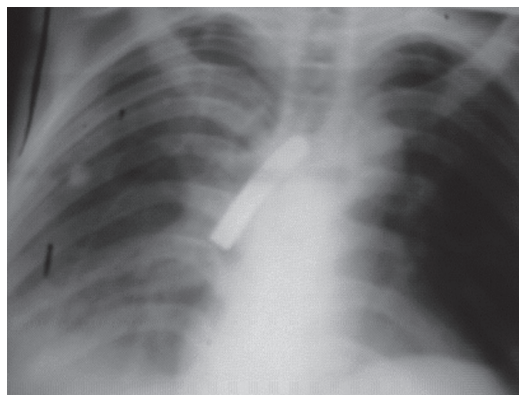


Figure 1 - A portable chest x-ray revealing a segment of the metallic tracheostomy tube in the right main bronchus stem.

the breakage was most probably due to manufacturer's defects of the device since it occurred within few days of purchase, although another cause, such as use of second hand tube could not be ruled out, a practice, which we have observed, during our practice in the intensive care unit. It appears that breakage of tube is less likely to occur in stainless steel or silver tubes, due to their superior and remarkable resistance to corrosion. We suggest that metal tubes are supplied as a set, and the assembly of all parts as a single package be purchased in toto, and a purchase of separate or individual parts be preferably avoided. These precautionary measures may reduce the chances of occurrence of this rare, but potentially disabling or perhaps fatal complication. Finally, we may add that such mishaps may not only occur in the hospital setting where they can be recognized early, but may occur in the home setting which may end up in catastrophic outcomes.

Received 1st March 2006. Accepted 15th August 2006.

From the Department Anesthesiology, Imam Khomeini Hospital, Tehran University of Medical Sciences, Tehran, Iran. Address correspondence and reprint requests to: Dr. Zabid H. Khan, Professor of Anesthesiology, Department Anesthesiology, Imam Khomeini Medical Center, Tehran University of Medical Sciences, Tehran 14197, Iran. Tel/Fax: +98 (21) 66438634. E-mail: kbanzh51@yahoo.com

References

1. National Safety Council. Injury facts (formerly Accident facts). Itasca, IL: National Safety Council; 1999.
2. MCGuirt WF, Holmes KD, Feeks R. Tracheobronchial foreign bodies. *Laryngoscope* 1988; 98: 615-618.
3. Baharloo F, Veyckemans F, Francis C, Bietlot MP, Rodenstein DO. Tracheobronchial foreign bodies: presentation and management in children and adults. *Chest* 1999; 115: 1357-1362.
4. Barretto RL, Hollinger LD. Foreign bodies of the airway and esophagus. In: Cummings CW, editor. Otolaryngology head and neck surgery. USA; Elsevier Mosby; 2005. p. 4343.
5. Kumar KS, Das K, D'Cruz AJ. Aspiration of a tracheostomy tube flange. *Indian J Pediatr* 2004; 71: e80-e82.
6. Kakar PP, Saharia PS. An unusual foreign body in the tracheobronchial tree. *J Laryngol Otol* 1972; 86: 1155-1157.