

Diagnosis and management of pediatric cardiac hydatid cyst

Nuha AG. Nimeri, MD, Sulafa KM. Ali, FRCPCH.

Echinococcosis is a serious health issue occurring in some geographical regions of the world. Cardiac hydatid cysts are rare and represent 0.5% of all hydatid cysts in humans.¹ We are reporting a 9-year-old Sudanese boy referred to the Cardiology Clinic because of history of chronic cough for 4 years and a heart murmur. All causes of chronic cough were ruled out and there was no history of contact with animals. Examination revealed a thin child with weight below third percentile for age and normal height. Chest examination showed coarse crepitations heard bilaterally. He had normal pulses and blood pressure, normal first and second heart sounds. A soft ejection systolic murmur was heard at the pulmonary area. Other systems were normal. His complete blood count showed eosinophilia and Erythrocyte sedimentation rate (ESR) of 65 mm/hour. Chest x-ray, electrocardiogram (ECG) were normal. Echocardiogram revealed a well demarcated, well defined, rounded, echolucent cyst measuring 30 x 30 mm in size at the superior edge of the interventricular septum on the right ventricular side. The cyst contains echogenic small structures and clear fluid (Figure 1). The flow acceleration of the right ventricle outflow tract with a Doppler gradient of 25 mm Hg was noted. Chest CT revealed similar findings in the heart but no lung cysts. Brain CT scan was normal. Abdominal ultrasound did not show cysts in the abdominal organs. The child was started on albendazole 200 mg per oral twice a day for 28 days with 2 weeks break in between for 9 months. Surgery was planned to be carried out after starting treatment. Three months later there was a significant clinical improvement with resolution of cough, disappearance of chest findings and weight gain. Erythrocyte sedimentation rate came down to normal level. The subsequent 4 echocardiogram revealed progressively decreasing size of the cyst from 30 x 30 to 19 x 16 mm and augmented density of the cyst fluid. The cyst became more echogenic and solid. Surgery was withheld and the patient continued on medical treatment. Cardiac hydatid disease is rare in adults and even rarer in children.² Right sided cardiac *Echinococcosis* are rare and shows special clinical features that leads to serious and life threatening complications such as pulmonary embolism. Patients are often asymptomatic and may present with a precordial pain, dyspnea, and a systolic murmur of false pulmonic stenosis or symptoms of extra cardiac disease; hence, cardiac involvement, as in our patient, is often discovered incidentally. Diagnosis of cardiac hydatid cyst is often delayed because of the absence of specific clinical symptoms and signs. Serological confirmation (indirect hemoagglutination (IHA) and enzyme linked immunosorbant assay [ELISA] tests), which was not carried out to our patient, is usually difficult because of a long

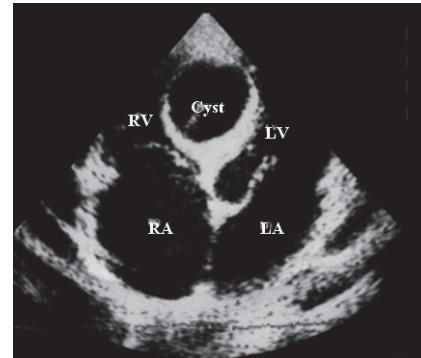


Figure 1 - Apical 4 chamber view showing the hydatid cyst at the interventricular septum measuring 30 x 30 mm before treatment, RV - right ventricle, LV - left ventricle, RA - right atrium, LA - left atrium

period between parasitic infection and the manifestation of disease.³ Transthoracic echocardiography and transoesophageal echocardiography constitute the imaging procedure of choice for the diagnosis of cardiac hydatid cyst with a high sensitivity, specificity.⁴ Chemotherapy of cystic *Echinococcosis* with cyclic treatment of 28 days with 2 weeks break in between for 9 months using low doses of albendazole (6 mg/kg) has been reported by many authors and as in our patient led to clinical and echocardiographic improvement.⁵ This approach can be more attractive where resources for surgical treatment are limited as in our area. The progressive clinical and echocardiographic improvement on medical treatment would make the surgical option much less desired but close follow up is recommended.

Received 26th March 2006. Accepted 13th September 2006.

From the Department of Pediatric Cardiology, Sudan Heart Center, Khartoum Erkaweit, Sudan. Address correspondence and reprint requests to: Dr. Nuha A. Nimeri, Department of Pediatric Cardiology, Sudan Heart Center, PO Box 11917, Khartoum Erkaweit, Sudan. Tel. +24 (918) 3232133/3232137. Fax. +24 (918) 3232135. E-mail: nahoia73@yahoo.com

References

1. Bouraoui H, Trimeche B, Mahdhaoui A, Majdoub A, Zaaraoui J, Hajri Ernez S, et al. Echinococcosis of the heart: clinical and echocardiographic features in 12 patients. *Acta Cardiol* 2005; 60 : 3941.
2. Jouhadi Z, Ailal F, Dreoua N, Eddine AZ, Abid A, Skalli A, et al. Cardiac hydatid cyst. Two cases in children. *Press Med* 2004; 18: 12603.
3. BenHamada K, Maatouk F, BenFarhat M, Betbout F, Gamra H, Addad F, et al. Eighteen year experience with Echinococcosis of the heart .Clinical and echocardiographic features in 14 patients. *Int J Cardiol* 2003; 23: 14551.
4. Gurbuz A, Tetik O, Yilik L, Emrehan B, Ozsoyler I, Ozbek C. Cardiac involvement of hydatid disease. *Jpn J throrac cardiovasc Surg* 2003; 51: 5948.
5. Barbetseas J, Lambrou S, Aggeli C, Vyssoulis G, Frogoudaki A, Tsiamis E, et al. Cardiac hydatid cysts: echocardiographic findings. *J Clin Ultrasound* 2005; 33: 2015.