An incidence study on thyroglossal duct cysts in adults

Atilla Kurt, MD, Cahide Ortug, MD, Yuksel Aydar, PhD, Gursel Ortug, DMD, PhD.

ABSTRACT

Objectives: To investigate the incidence of the asymptomatic thyroglossal duct anomalies and to review the literature and make comments on the significance of this condition.

Methods: A total of 80 cadavers were dissected in the present study. This study was carried out during 2005, where the cadavers were randomly included from the criminal laboratories of the Ministry of Justice, Republic of Turkey in Istanbul. None of the cadavers had laryngeal and cervical injuries resulting from a trauma or the cause of their death. The examined cadavers included 59 men and 21 females, and their age were ranged from 35-80 years old. The larynges were removed and fixed in 10% formalin and then dissected. The sections were examined using surgical SMZ 10 Nikon stereomicroscope. We evaluated the presence, localization, and diameter of the cysts with regard to age and sex of the cadavers.

Results: We observed a total of 12 different localization of thyroglossal ducts and cysts among the dissected 80 cadavers. Ten of these ducts cysts were found in males with an age range of 35-68 years and 2 in female cadavers aged 46-65 years. In 6 cases, the thyroglossal ducts and cysts were located in the left of the midline of the neck, while 3 cases were from the right of the midline, and the remaining was located on the midline of the neck. In all cases, thyroglossal ducts and cysts were complete and restricted to the infrahyoid region; all of them had connection with the hyoid bone, but not with the perichondrium of the cartilage. In addition, the thyroglossal ducts had connection with the left lobe of the thyroid glands in 3 cases, one case in the right lobe, and 2 cases with the isthmus of the thyroid gland. Finally, in 5 cases thyroglossal ducts were complete and had well-developed cysts.

Conclusion: Thyroglossal duct remnants are one of the most often seen congenital asymptomatic masses of the neck region (7%). The presence of these duct remnants may lead to abnormal phonation and epithelial carcinomas. Therefore, correlation of the rate of thyroglossal duct remnants in a population together with the related clinical symptoms can lead to an early diagnosis and better treatment chances for these problems.

Saudi Med J 2007; Vol. 28 (4): 593-597

From the Department of General Surgery (Kurt), Yeni Isviçre Hospital, Kozyatagı, Istanbul, Department of Otorhinolaryngology (Ortug C), State Hospital, and the Department of Anatomy (Aydar, Ortug G), Faculty of Medicine, Eskisehir, Turkey.

Received 21st August 2006. Accepted 25th November 2006.

Address correspondence and reprint request to: Dr. Cahide Ortug, Department of Otorhinolaryngology, PK 60 Merkez PTT (Box.), TR-26010 Eskisehir, Turkey. Fax. +90 (222) 2399088. E-mail: cahideortug@yahoo.com

The thyroglossal duct cysts are the most common congenital neck mass resulting from remnants of the thyroglossal duct.[1,3,4,9] An incidence of approximately 7% of the population has been reported for the occurrence of thyroglossal duct cysts and remnants.[1,3,10-12] It has been reported that one of the underlying reasons for the formation of duct remnants is hereditary.[5,6] In general, the signs related to the presence of thyroglossal duct remnants that appear during childhood can be treated surgically.[1,7-9] However, in some cases, the existing thyroglossal duct remnants may present with atypical symptoms or can stay asymptomatic throughout the life.[8,10,13] Although thyroglossal duct cysts are one of the most common pediatric midline neck lesions, they have been known to be present in adults as well with varying frequency.[13] The metaplastic changes of the thyroglossal cyst epithelium have been reported earlier (approximately 4%). Malignant lesions are often diagnosed incidentally after surgical excision approximately 1%.[14-16]

The tendency for malignant degeneration makes asymptomatic thyroglossal duct remnants an important clinical matter; therefore, in this study, we aimed to document the incidence of asymptomatic thyroglossal duct remnants in adult Turkish population based on cadaver study.

Methods. In the present study, 80 cadavers were dissected. They were supplied as part of the criminal investigations due to suspicious conditions around the time of their death. This study consists of randomly included cadavers from the Ministry of Justice criminal lab of the Republic of Turkey in Istanbul. The sections were carried out at the Department of Anatomy, Medical School of Eskisehir Osmangazi University during 2005.

The larynges of the 80 cadavers (59 men and 21 female; age range: 35-80 years old) were studied. None of them had laryngeal and

16AnIncidence20060968.indd 593 3/21/07 9:48:10 AM

cervical injuries as a result of a trauma or due to cause of their death. The larynges were fixed in 10% formalin and their dissections were examined using a surgical SMZ 10 Nikon stereomicroscope. We assessed the presence of cyst, localization, and its sex; age features were determinate.

Results. Among the 80 larynges examined in this study, 12 different localizations of thyroglossal duct and their cysts were observed, 10 in males with an age range of 35-68 years and 2 in females aged 46 and 65 years **(Table 1).** In 3 cases, thyroglossal ducts were located at the right to the midline of the neck **(Figures 1a to 1c),** and in 6 cases they were found in the left of the midline of the neck **(Figures 2a to 3c).** In 3 cases, thyroglossal ducts were in the middle line **(Figures 4a to 4c).** All cases were located in the infrahyoid region and all thyroglossal ducts were complete and had connection with hyoid bone, but not with the perichondrium of the cartilage.

In addition, 3 cases had connection with the left lobe of thyroid glands **(Figures 2a to 2c),** one with the right lobe **(Figure 1a),** and 2 with the isthmus of thyroid gland **(Figures 3c and 4b).** Five cases showed both complete thyroglossal ducts and well-developed cysts **(Figures 1a, 1b, 3a, 4a, and 4b).**

Discussion. Thyroglossal duct cysts are common primary neck masses, resulting from remnants of the thyroglossal duct. They can occur at any point along the migratory path of the thyroid gland until the second or third decade of life. The usual symptoms leading to the diagnosis are painless midline neck masses or fistulas.[4] Despite their close proximity, the cysts may rarely affect the larynx causing voice changes and respiratory symptoms.[4,11,12] But unfortunately, these congenital masses uncommonly stay asymptomatic for a long time and might undergo metaplastic changes, which are often diagnosed incidentally after surgical excision.[1,15-18]

It has been reported, that the incidence of thyroglossal duct cyst and remnants is 7%.[1,3] However, real incidence is higher due to unidentified asymptomatic cases. As reported in the literature, Sprinzpl et al[8] studied the larynges of 58 infants and children for the analysis of the growth patterns of thyroglossal tract remnant using histologic whole organ serial section. They found remnants of the thyroglossal tract or ectopic thyroid tissue in 24 cases (41.3%), while they observed a complete thyroglossal tract in 4 specimens (16.6%). The age incidence for the clinical occurrence of thyroglossal anomalies ranges from 6-81 years. Although, the thyroglossal tract cyst is a congenital anomaly that most commonly presents in a pediatric age,[1,9,12,13,15,19] it is important to realize that it can appear in adults as well and to be associated with a malignant change.[1-3,14-18,20] In our present series of thyroglossal duct cysts cases, the age incidence was 35 years or older with an average of 50.75 years. Ewing et al[1] reviewed the clinical anatomic pathologic and computer database in a group of 47 patients with a tissue diagnosis of thyroglossal duct cyst. Twenty-seven of these patients were males and 20 were females, 36 were under 20, while the remaining 11 patients were 20 years or older, 2 patients showed malignant degenerations (2/47). Katz et al[13] also reported a study of 79 patients (39 females and 40 males) who underwent a Sistrunk procedure for thyroglossal duct cysts. Two of them showed papillary carcinoma in thyroid tissue of the cysts wall.

Among the dissected 80 cadavers in our study, thyroglossal duct cysts were discovered in 12 cadavers, all cysts were in infrahyoid localizations, an incidence of 15% (12/80). The 12 cadavers were 10 males and 2 females with an age range of 35-68 years. The

Table 1 - Localization of thyroglossal duct and cysts with regard to age and sex of the cadavers (n=80 cadavers).

Age	Sex	Localization			Feature
		Right	Middle	Left	
68	Male	+			Complete thyroglossal duct, contained well developed cyst, connection with right lobe of thyroid gland
49	Male	+			Complete thyroglossal duct, contained well developed cyst
56	Male		+		Complete thyroglossal duct
43	Male		+		Complete thyroglossal duct, contained well developed cyst, connection with isthmus of thyroid gland
60	Male		+		Complete thyroglossal duct
40	Male			+	Complete thyroglossal duct, connection with left lobe of thyroid gland
42	Male			+	Complete thyroglossal duct, connection with left lobe of thyroid gland
52	Male			+	Complete thyroglossal duct, contained well developed cyst
53	Male			+	Complete thyroglossal duct, contained well developed cyst
35	Male			+	Complete thyroglossal duct, connection with left lobe of thyroid gland
46	Female	+			Complete thyroglossal duct
65	Female			+	Complete thyroglossal duct, connection with isthmus of thyroid gland

16AnIncidence20060968.indd 594 3/21/07 9:48:10 AM

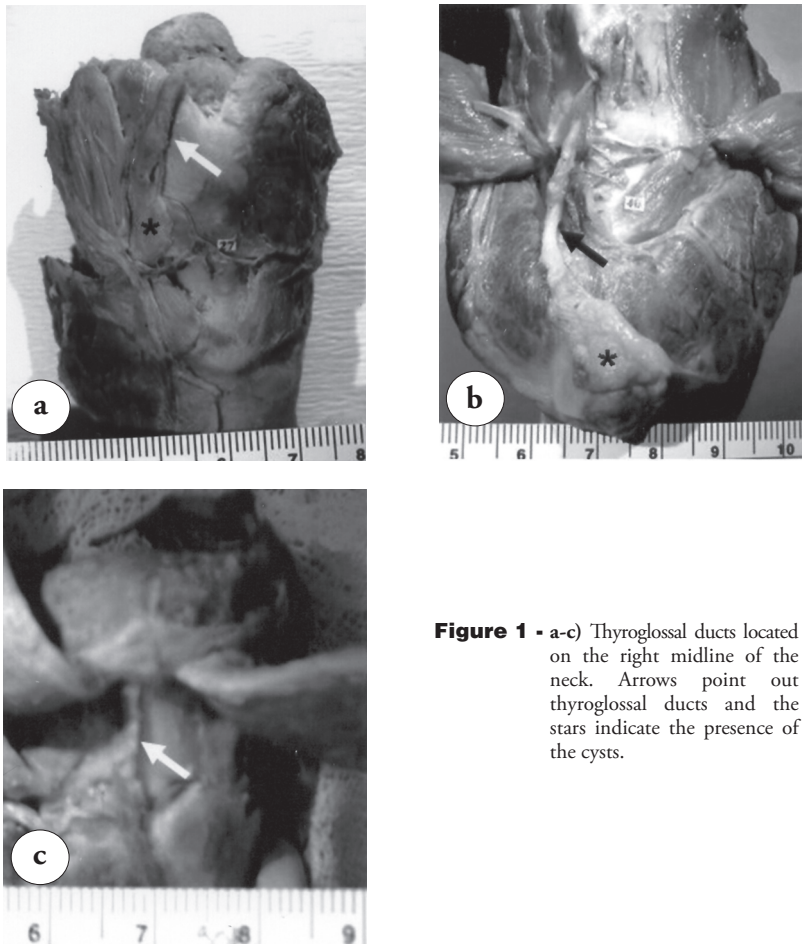

Figure 1 - a-c) Thyroglossal ducts located on the right midline of the neck. Arrows point out thyroglossal ducts and the stars indicate the presence of the cysts.

Figure 2 - a-c) Thyroglossal ducts located on the left midline of the neck. Arrows point out thyroglossal ducts.

16AnIncidence20060968.indd 595 3/21/07 9:48:12 AM

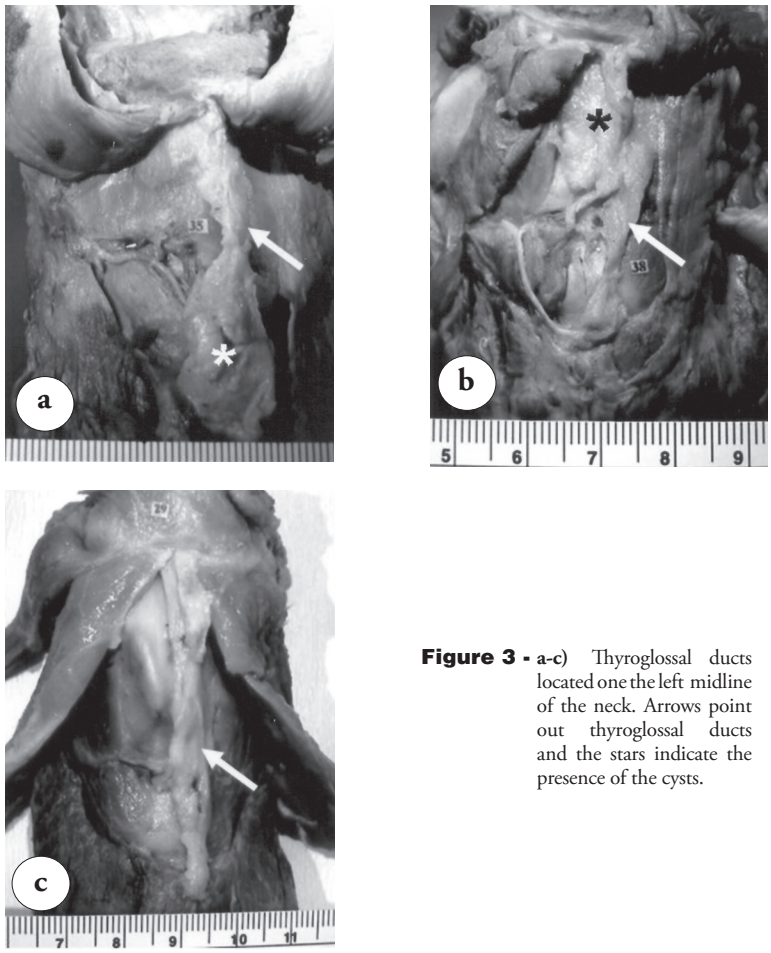

Figure 3 - a-c) Thyroglossal ducts located one the left midline of the neck. Arrows point out thyroglossal ducts and the stars indicate the presence of the cysts.

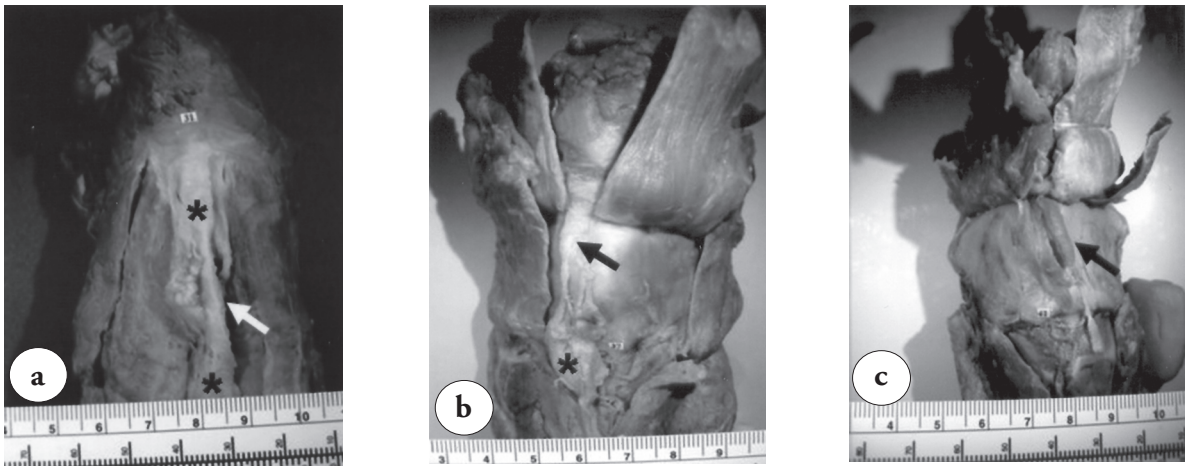

Figure 4 - a-c) Thyroglossal ducts located on the midline of the neck. Arrows point out thyroglossal ducts and the stars indicate the presence of the cysts.

16AnIncidence20060968.indd 596 3/21/07 9:48:13 AM

thyroglossal ducts and their cysts in our series presented a ventral path in relation to the hyoid bone with no connection with the perichondrium. Our findings conform in this regard with those of Sprinzl et al.[8]

As the thyroglossal duct and remnants usually presents as an asymptomatic anterior neck mass that may undergo malignant degeneration, this emphasizes the importance of the precise neck examinations. Therefore, careful ultrasound and computed tomography examinations would be necessary to identify the features of these asymptomatic ductal cysts and detect any possible metaplastic changes within them.[3,8,12] In addition, knowing the incidence and localization possibilities of asymptomatic thyroglossal duct cysts in a population is clinically significant.

References

1. Ewing CA, Kornblut A, Greeley C, Manz H. Presentations of thyroglossal duct cysts in adults. ***Eur Arch Otorhinolaryngol*** 1999; 256:136-138.
2. Hilger AW, Thompson SD, Smallman LA, Watkinson JC. Papillary carcinoma arising in a thyroglossal duct cyst: a case report and literature review. ***J Laryngol Otol*** 1995: 109; 1124-1127.
3. Kamal K, Girish R. Papillary carcinoma arising in a thyroglossal duct remnant. ***Indian J Surg*** 2003; 65: 282-284.
4. Lubben B, Alberty J, Lang-Roth R, Stoli W, Seifert E. Stimmveränderung und laryngeale obstruction durch eine mediane Halszyste. ***HNO*** 2001; 49: 48-53.
5. Greinwald JH Jr, Lcichtman LG, Simko EJ. Hereditary thyroglossal duct cysts. ***Arch Otolaryngol Head Neck Surg*** 1996; 122: 1094-1096.
6. Léger J, Marinoviç D, Garel C, Bonaïti-Peilié C, Polak M, Czernichow P. Thyroid developmental anomalies in first degree relatives of children with congenital hypothyridism. ***J Clin Endocrinol Metab*** 2002; 87: 575-580.
7. Mohan PS, Chokshi RA, Moser RL, Razvi SA. Thyroglossal duct cysts: a consideration in adults. ***Am Surg*** 2005; 71: 508-511.
8. Sprinzl GM, Koebke J, Wimmers-Klick J, Eckel HE, Thumfart WF. Morphology of the human thyroglossal tract: a histologic and macroscopic study in infants and children. ***Ann Otol Rhinol Laryngol*** 2000; 109: 1135-1139.
9. Sturgis EM, Miller RH. Thyroglossal duct cysts. ***J La State Med Soc*** 1993; 145: 459-461.
10. Baatenburg de Jong RJ, Rongen RJ, Lameris JS, Knegt P, Venwoerd CD. Ultrasound characteristics of thyroglossal duct anomalies. ***ORL J Otorhinolaryngol Relat Spec*** 1993; 55: 299-302.
11. Brown EG, Albernaz MS, Emery MT. Thyroglossal duct cyst causing airway obstruction in an adult. ***Ear Nose Throat J*** 1996; 75: 530-532, 534.
12. Cumberworth VL, Bradley PJ. Atypical thyroglossal duct cyst. ***J Laryngol Otol*** 1989; 103; 700-703.
13. Katz AD, Hachigian M. Thyroglossal duct cysts. A thirty-year experience with emphasis on occurrence in older patients. ***Am J Surg*** 1988; 155: 741-744.
14. Branstetter BF, Weissman JL, Kennedy TL, Whitaker M. The CT Appearance of thyroglossal duct carcinoma. ***AJNR Am J Neuroradiol*** 2000; 21:1547-1550.
15. Martins AS, Melo GM, Tincani AJ, Lage HT, Matos PS. Papillary carcinoma in a thyroglossal duct: case report. ***Sao Paulo Med J*** 1999; 117: 248-250.
16. Motamed M, McGlashen JA. Thyroglossal duct carcinoma. ***Curr Opin Otolaryngol Head Neck Surg*** 2004; 12: 106-109.
17. Vijay R, Rajan KK, Feroze M. Inapparent twin malignancy in thyroglossal cyst: case report. ***World J Surg Oncol*** 2003; l: 1-15.
18. Liu TP, Jeng KS, Yang TL, Wang TC, Hwang KF. Thyroglossal duct cysts: an analysis of 92 cases. ***Zhonghua Yi Xue Za Zhi (Taipei)*** 1992; 49: 72-75.
19. Dedivitis RA, Camargo DL, Peixoto GL, Weissman L, Guimaraes AV. Thyroglossal duct: a review of 55 cases. ***J Am Coll Surg*** 2002: 194: 274-247.
20. Asakage T, Nara S, Takashi Y, Ebihara S. Thyroglossal duct carcinoma: a case report. ***Jpn J Clin Oncol*** 1997; 27: 340-342.

16AnIncidence20060968.indd 597 3/21/07 9:48:13 AM