

Unusual mechanism of isolated torsion of fallopian tube following minor trauma

Herniation through a broad ligament tear

Deniz Karcaaltincaba, MD, Filiz Avsar, MD, Cantekin Iskender, MD, Birol Korukluoglu, MD.

ABSTRACT

Isolated torsion of the fallopian tube without ovarian involvement and associated pathology is a rare event. We report an 18-year-old single female who presented with acute lower abdominal pain during menstruation after a minor trauma of the pelvis. It was diagnosed as isolated torsion of normal right tube during laparotomy due to herniation of the tube through a tear in the broad ligament.

Saudi Med J 2007; Vol. 28 (4): 637-638

From the Department of Obstetrics and Gynecology, Ataturk Research Hospital, Bilkent Ankara, Turkey.

Received 29th May 2006. Accepted 30th August 2006.

Address correspondence and reprint request to: Dr. Deniz Karcaaltincaba, Department of Obstetrics and Gynecology, Ataturk Research Hospital, Bilkent Ankara, Turkey. Fax: +90 (312) 3112145. E-mail: denizaltincaba@yahoo.com

Isolated torsion of fallopian tube was first described by Bland-Sutton in 1890.¹ There are usually predisposing factors such as previous tubal ligation, hydrosalpinx, tubal carcinoma, pelvic inflammatory disease (PID), ovarian and paraovarian masses, and pregnancy.^{2,3} A correct preoperative diagnosis is rarely made due to nonspecific signs and symptoms.³ Early diagnosis is important to save the tube especially in young patients otherwise, salphengectomy is necessary. We describe an unusual cause of isolated fallopian tube without an associated pathology resulting from a tear in the broad ligament and subsequent herniation. Our objective is to describe an unusual mechanism of isolated fallopian tube torsion.

Case Report. An 18-year-old girl presented to the emergency room with acute lower right guardant pain. She was single and denied any sexual intercourse. Her menstrual bleedings were regular and her last period started 2 days

before admission. Her pain persisted with periodic aggravations. She had no history of gynecologic disease and prior abdominal surgery. She was working at a daycare and she recalled one of the kids jumped on her lap a day before menstruation. She had no abnormal vaginal discharge. On physical examination temperature was 37.80, heart beat 92/min. Abdominal examination revealed tenderness and rebound tenderness in the right lower quadrant with no palpable mass. Since the hymen was intact on inspection, rectal examination was carried out. The uterus was normal and there was tenderness with cervical motion and on right adnexa. Abdominal x-ray was normal and ultrasonography showed a cystic lesion in the right adnexal region measuring 3.9 x 2.9 cm (**Figure 1**). Both ovaries appeared normal on ultrasonography. Pregnancy test was negative. Hemoglobin was 12.8 g/dl (normal 11-14.2 g/dl) and white blood cells was 12400/cm³ (normal 4300-10800/cm³). She was admitted to the hospital for a suspected PID and intravenous antibiotics were administered. The patient's condition did not improve with the intravenous antibiotics and due to the absence of associated risk factors for PID, exploratory laparotomy was performed with a suspected diagnosis of acute appendicitis. At laparotomy, the right fallopian tube was considerably distended (4 x 7 cm), black and necrotic, twisted twice around itself at the isthmic region and 1800 at the mid ampullary region (**Figure 2**). There was a tear in the mesentery of the tube within the broad ligament and herniation of the tube through this defect resulted in fixation and torsion. No cyst was noted in the right adnexal region. Both ovaries and left tube were normal. There was no endometriosis, adhesions and bleeding. Histologic examination showed hemorrhagic infarction and necrosis of the fallopian tube. No associated pathology was found.

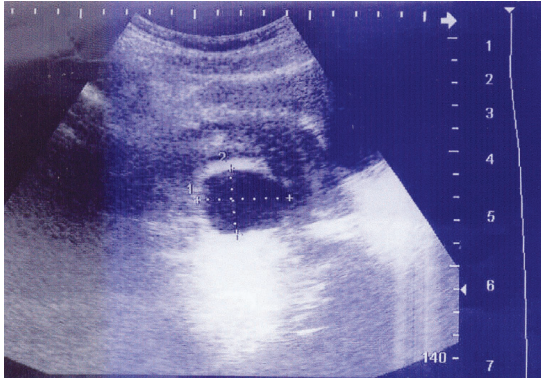


Figure 1 - Sagittal ultrasound image shows a cystic lesion adjacent to normal appearing ovary.

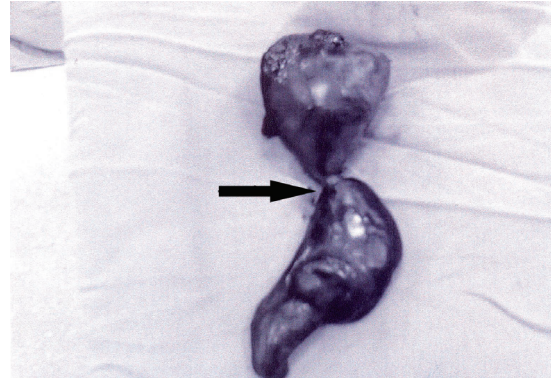


Figure 2 - Surgical specimen demonstrates necrosis and torsion (arrow) of fallopian tube.

Discussion. Isolated tubal torsion can be related to the abnormalities of the tube itself and the adjacent organs, which rarely occur without an obvious underlying pathology as in our patient. In 1962, Blair reviewed 300 cases of isolated tubal torsion and offered several theoretical explanations for the torsion of normal appearing tubes including spasm or myosalphingeal dyskinesia, venous congestion, sudden body position changes or decelerations leading to abnormal motion of the internal organs and trauma (accidents, surgery).⁴ In our case, tubal torsion occurred during menstruation. The patient also described a minor abdominal trauma a day before menstruation. She felt some pain in the right lower quadrant at the time of incident. Minor trauma might have led to a broad ligament tear at the mesosalphinx of the tube and superimposition of menstruation related congestion may be the cause of isolated tubal torsion.

Symptomatology of tubal torsion although is not pathognomonic, and seems to follow a suggestive pattern² of sudden onset, intermittent colicky pain in either lower quadrants. Ultrasonographic findings of isolated fallopian tube torsion resembles a dilated fallopian tube consisting of a hyperechogenic wall, folded configuration and foci of echogenicity protruding into the lumen possibly related to wrinkled fallopian tube epithelium.⁵ Color Doppler examination may demonstrate high impedance flow with reversed or absence of diastolic flow on the affected side.⁵ Demonstration of ipsilateral normal ovary should strongly suggest isolated tubal torsion. Color Doppler

can be useful in the early diagnosis especially in young patients to preserve fertility.

The surgical approach to the torsion of the fallopian tube depends on the condition of the tube during operation and the patients' age and fertility desire. If the torsion is incomplete or recent and tubal tissues are still viable during operation, untwisting of the tube can be chosen primarily in younger women, otherwise salpingectomy is carried out. The contralateral fallopian tube should always be carefully examined.

Isolated tubal torsion can occur secondary to a broad ligament tear. In young women with right or left sided lower abdominal pain and with normal ovaries and appendix on ultrasonography, isolated fallopian torsion should be considered in the differential diagnosis especially in patients with a history of minor pelvic trauma to avoid necrosis of the tube.

References

1. Bland-Sutton T. Salpingitis and some of its effects. *Lancet* 1890; 2: 1146
2. Youssef AF, Fayad MM, Shafeek MA. Torsion of the fallopian tube: A clinico-pathologic study. *Acta Obstet Gynecol Scand* 1962; 114: 727.
3. Krissi H, Orvieto R, Dicker D, Dekel A, Ben Rafeal Z. Torsion of a fallopian tube following Pomeroy tubal ligation: a rare case report and review of the literature. *Eur J Obstet Gynecol Reprod Biol* 1997; 72: 107-109.
4. Blair CR. Torsion of the fallopian tube. *Surg Gynecol Obstet* 1962; 114: 727-730.
5. Baumgartel PB, Fleischer AC, Cullinan JA, Bluth RF. Color Doppler sonography of tubal torsion. *Ultrasound Obstet Gynecol* 1996; 7: 367-370.