Primary pulmonary Hodgkin's lymphoma

A report of 2 cases and review of the literature

Ibrahim S. Tillawi, *FCAP, FASCP.*

ABSTRACT

Two cases of primary pulmonary Hodgkin's lymphoma (PPHL) are presented, a male aged 21, and a female aged 32 years. Symptoms included non-productive cough, shortness of breath, low-grade fever, wheezing, and weight loss. Duration of illness varied between 6 weeks in the male patient to 7 months in the female patient. Both patients were given an empirical trial of antibiotics and anti-cough measures with no response. Radiological studies carried out after failure to respond to medical treatment, revealed the presence of pulmonary parenchymal masses in both patients. Cytology, bronchoscopic and transbronchial biopsies were not diagnostic, which led to opened wedge resections. Finally, the diagnosis of primary pulmonary Hodgkin's disease was reached after supportive immunohistochemical staining (CD30 and CD15 both positive in RS cells). Both patients were regarded as stage I extranodal (IE) after exhaustive measures failed to demonstrate involvement of other body sites.

Saudi Med J 2007; Vol. 28 (6): 943-948

From the Department of Pathology, Division of Hemapathology, Riyadh Military Hospital, Riyadh 11154, Kingdom of Saudi Arabia.

Received 5th June 2006. Accepted 9th September 2006.

Address correspondence and reprint request to: Dr. Ibrahim S. Tillawi, Department of Pathology, Division of Hemapathology, Riyadh Military Hospital, Riyadh, 11154, Kingdom of Saudi Arabia. E-mail address: ibrahimtellawi@hotmail.com

Unlike non-Hodgkin's lymphoma (HL) where extranodal involvement far exceeds that of nodal disease (especially in the Middle East region for example), extranodal HL is universally uncommon. Secondary involvement of the lung "parenchyma" by HL is seen in as many as 15-40% of the cases of HL, mostly as stages III and IV as the disease becomes disseminated or as direct spread from the mediastinum. Primary pulmonary Hodgkin's lymphoma (PPHL) on the other hand is not associated with extrapulmonary lymph nodal disease, and is an unusual finding with less than 100 cases reported worldwide based on individual case reports. Criteria that are used to select this latter group of patients are very rigid,[1,2] which explains in part such low incidence of occurrence. Duration of symptoms can vary from a few weeks to several months, and none of the symptoms are specific such as non-productive cough, shortness of breath, low-grade fever, wheezing, and weight loss. The disease can radiologically mimic many other lesions; tumor masses are either multiple or solitary, with or without cavitation, whereas in other situations, the disease mimics pneumonic interstitial infiltrates. Based on data from the literature, the histopathological diagnosis in around half of the reported cases was initially missed.[1,2] This may be due to small non-diagnostic bronchoscopic biopsy samples (which accounted for the majority of missed diagnosis), as the non-neoplastic mostly associated pneumonic region is what is usually biopsied, or the biopsy sample itself may not show the adequate diagnostic material, as this is what is usually needed to substantiate such rare diagnosis, eventually ending with a long list of differential diagnostic considerations. Commonly, it is not until the mass is totally resected, which will then allow abundant pathologic material for examination and accurate final histopathological diagnosis. Rarely, the presentation may take the form of cough, hemoptysis or atelectasis, in which case bronchoscopy will uncover the presence of an endobronchial form of the disease, which in some reports has a higher diagnostic yield.[1,2] Once the diagnosis is finally made, problems in appropriate staging arise as to whether the lesions is stage 1 extranodal (IE) or stage IVE. Patients usually receive chemotherapy with or without radiotherapy. Survival depends on several prognostic factors. Factors which correlate with poor prognosis include: "B" symptoms, older age group, (>60 years), bilateral disease, multiple (multilobe) disease, cavitary lesions, pneumonic disease, and "penetration" of the pleura

01Primary20060642 943 5/15/07 10:22:59 AM

with or without associated pleural effusion.[1,2] In this report, the clinicopathological features of 2 additional cases of PPHL are reported, emphasizing difficulties met in clinical, radiological, and pathological diagnosis.

Case Report. *Patient One.* A 19-year-old, "asthmatic" non-smoker male who works as a plumber, for the past 2 months prior to the final hospital admission, had been complaining of non-productive cough of increasing severity, shortness of breath, low grade fever, wheezing and 6-pound-weight loss. His respiratory symptoms failed to respond to antibiotics and anti-cough measures initially prescribed, for which he underwent a plain chest x-ray and that showed 2 distinct widely separated opacities in the mid-left lung field zone, confirmed by computerized tomography (CT) (**Figures 1 & 2**). Physical examination was within normal limits, no peripheral lymphadenopathy or organomegaly were observed. Pertinent laboratory data revealed a hemoglobin of 14.7 gm%, hematocrit of 43.6%, white blood count (WBC) 12,500/ul, with a differential of neutrophils 58%; lymphocytes 21%; eosinophils 15%; and monocytes of 6%; platelets were 259,000/ul. Blood film was interpreted as normochromic normocytic with eosinophilia; erythrocyte sedimentation rate (ESR) was 54 mm/first hour; coagulation tests were normal. Liver and kidney function tests were normal. Bronchial wash was non-diagnostic revealing only benign respiratory epithelial cells, histiocytes and occasional eosinophils. Transbronchial biopsy revealed slight eosinophilic infiltration, and a list of differential diagnosis was given including "histiocytosis X" and Wegener's granulomatosis. An open lung biopsy was carried out, and a frozen section revealed the presence of HL. A segmentectomy with lymph node sampling was performed. Postoperative bone marrow biopsy and aspiration were free of disease. Family history revealed the presence of allergy in the family. Barium contrasts studies of the both the upper and lower gastrointestinal tracts were all negative. Radionuclide bone scans and gallium scans were both negative. Abdominal and pelvic CT scans were also negative (Stage IE). The patient underwent radiotherapy and finished 8 courses of chemotherapy. Eosinophilia subsided after therapy was completed.

Patient 2. A 32-year-old non-smoker, female teacher, started complaining of relentless and progressive in severity non-productive cough for 7 months, not responding to cough medications and antibiotics. Her condition worsened as she developed chest pain of variable severity, weight loss, and fever. Subsequently, chest x-ray revealed the presence of an anterior superior mediastinal mass on antero-posterior views, which on lateral views showed that the lesion was definitely of pulmonary parenchymal location; a mediastinal component was also identified. A CT scan showed the presence of an anterior superior mediastinal mass, lateral to the superior vena cava. Slight mediastinal lymphadenopathy was also noted. The mass was 3 cm in size and was solitary. Physical examination revealed a healthy female with no peripheral lymphadenopathy or organomegaly. Pertinent laboratory data revealed hemoglobin of 13.4 gm/dl, hematocrit 40.4%; WBC 6700/ml, with a differential of neutrophils 55%, lymphocytes 40%, monocytes 5%; platelets 431,000/ml. Normal blood film; ESR 67 mm/first hour. Coagulation tests were normal. Liver function tests were normal; kidney functions tests were normal. Bronchial wash revealed the presence of respiratory epithelial cells, metaplastic cells, histiocytes, and rare inflammatory cells. Transbronchial biopsies revealed the presence of respiratory epithelial cells, and mucous. A CT guided fine needle aspiration biopsy (FNAB) revealed the presence of cells suggestive of HL. Frozen section diagnosis of the open biopsy was interpreted as suggestive of HL. A segmentectomy and excision of mediastinal as well as carinal lymph nodes was carried out. Postoperative bone marrow biopsy and aspiration were found to be free of disease. Barium contrast studies for the upper as well as the lower gastrointestinal tracts were found to be disease free. Abdomen and pelvis CT scans revealed no evidence of disease. Gallium scans and radionuclide bone scans were all negative (Stage IE).

Pathologic examination. On gross examination, patient one's specimen consisted of 2 wedge triangular shaped segments of lung with a well defined mass in each featuring central necrosis, but without concomitant cavitation. The masses measure 5 x 3 x 2 cms and 2.5 x 1.5 x 1.5 cms. Both masses show nodular irregularity and are bright yellow in the periphery, with characteristic central scarring and necrosis. Bronchovascular structures can be discerned in between the nodules. The adjacent pulmonary parenchyma is consolidated especially around the masses, with irregularity of the overlying pleural surface. The distance between the masses and the overlying pleural surface is the reflection of the true location of the masses in the central lung fields. Patient 2 specimen consists of an elongated segment of lung and multiple lymph nodes sampled from both the mediastinum and the carina. Sections carried out through the lung segment revealed the presence of a mass measuring 3.5 x 2.5 x 1.5 cms tan mass with irregular borders, and peripheral rimming by consolidated pulmonary parenchyma. The mediastinal lymph nodes were anthracotic. The pleural surface overlying is puckered, and thickened. Microscopic examination shows central masses radiating to peripherally located nodules that become confluent. The centrally located

01Primary20060642 944 5/15/07 10:22:59 AM

masses show peripherally radiating nodules composed of lymphocytes, eosinophils, histiocytes, and plasma cells interspersed with mononuclear, lacunar, and multilobated Reed–Sternberg (RS) cells (**Figure 3**); numerous mummified bodies were also seen. The RS cells showed strong immunostaining with CD30 and CD15 in both cell membraneous and Golgi zone location; CD45, CD20 and CD3 were uniformly negative in the RS cells. Foci of geographic staghorn as well as infarct-like types of necrosis were seen in patient one, being mostly centrally located (**Figure 4**). Patient 2 showed a scattered few punctate foci of necrosis only. The nodules were separated from each other by connective tissues bands that showed typical birefractive green color with polarizable microscopy (**Figures 5a & 5b**). This overall histology was diagnostic of nodular sclerosing classical variant of HL. Peripherally, the neoplastic satellite nodules are distributed along the lymphatic channels, especially within the septa and around the vascular bundles. Several small sized subpleurally located lymph nodes were observed, but none was involved body disease. The bronchial walls were densely infiltrated by the neoplastic process, destroying all the layers forming the bronchi, and projecting out of the wall forming at times polypoid masses of tumor within the bronchiolar lumina (**Figure 6**). Microscopic foci of granulomatous reaction were also observed, especially in the vicinity of necrosis. Vascular permeation was not seen in either patient. The adjacent pulmonary parenchyma showed pneumonic consolidation with septal thickening and infiltration by eosinophils and lymphocytes. Additionally, focal areas of lipid and obstructive pneumonia, foamy macrophages, cholesterol clefts, focal bronchiolitis and atelectasis were also observed in patient one. Patient 2 had associated pneumonic changes around the main tumor. The pleural surfaces showed mesothelial cell hyperplasia and subpleural fibrosis, with focal fibrinous exudation, especially noted close to the tumor. Hilar, mediastinal, and carinal lymph nodes showed no involvement by HL in both patients. Sections of the marrow biopsy were normocellular with adequate iron stores.

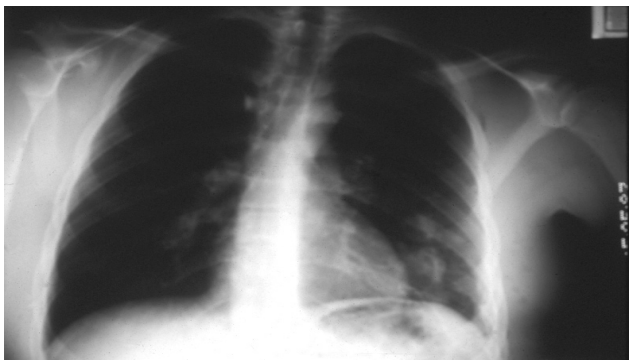

Figure 1 - Chest x-ray of patient one. Plain AP view showing 2 distinct widely separated left mid-lower 1t. Lung Field nodules (5 and 3 cms respectively).

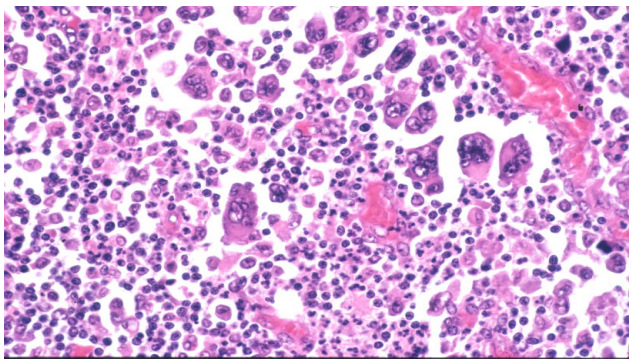

Figure 3 - High power view of one of the lymphoid nodules with variable density of Reed-Sternberg multinucleated giant cells; (Hematoxylin and Eosin; 40x magnification).

Figure 2 - Chest CT scan of patient one showing the largest nodule and its close approximation to the pleural surface.

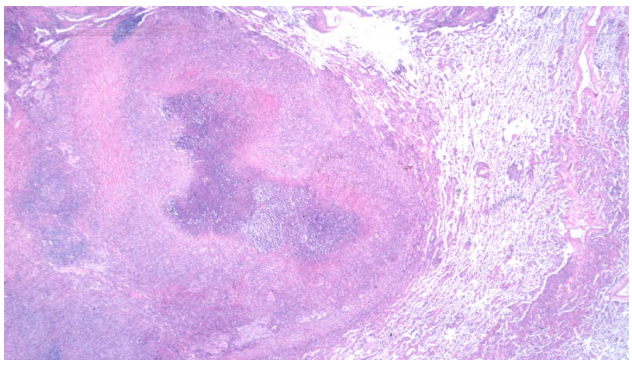

Figure 4 - Patient one. Section showing the edge of the large mass (left) and adjacent pulmonary parenchyma (right). Geographic staghorn central necrosis is clearly observed in the mid-portion of the mass (Hematoxylin and Eosin stain; 10x magnification).

01Primary20060642 945 5/15/07 10:23:00 AM

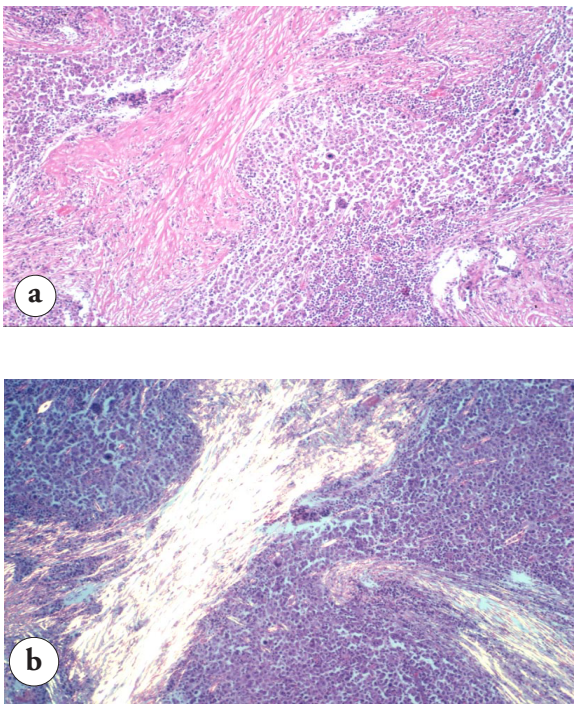

Figure 5 - Photogarph of **a)** low power view of a section from the tumor showing fibrous tissue bands that dissect the tumor into smaller nodules (left). **b)** These fibrous tissue bands polarize (right). Hematoxylin and Eosin stain 10x magnification).

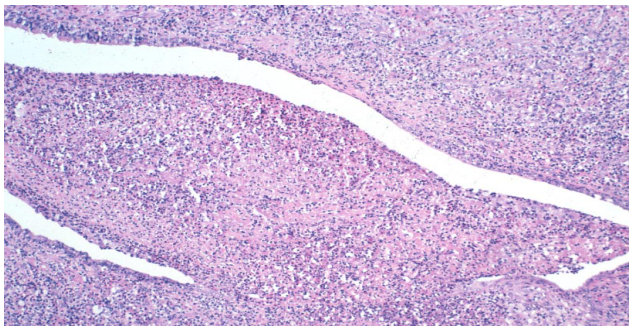

Figure 6 - Low power view of one of the terminal bronchi, showing the tumor penetrating through the wall with a polypoid-shaped tumor projecting into the lumen of the bronchus (Hematoxylin and Eosin; 10x magnification).

Discussion. Mediastinal and tracheobronchial lymph node involvement by HL in patients dying from uncontrolled disease is estimated at 25-50%. Pulmonary parenchymal involvement as extranodal lymphatic spread by permeation by HL has been observed to be the result of an accompanying hilar nodal involvement, namely, as stage IVE. The PPHL (stage IE), on the other hand, has been only rarely reported, and mostly as single case reports, except for a few small series,[1-4] and the largest series is that published by Youssem et al,[1] in which 15 cases were presented. The low incidence of PPHL is not only actual, but is in part due to the rigid criteria used to classify cases as PPHL.[1,2] These include: 1. Documentation of typical histological features of HL; 2. Restriction of the disease to the lung parenchyma with no or minimal involvement of the hilar lymph nodes. 3. Adequate clinical and/or pathologic exclusion of disease at distant sites. The origin of de novo PPHL is not believe to arise from the mediastinum.[1,2,5,6] Staging of extranodal HL is difficult due to its extreme rarity, therefore controversies exist whether diseased patients should be staged as IE or IVE.[7,8] All HL histologic types can primarily involve the lungs, and the nodular sclerosing (NS) type is by far the most common; where 60-70% of cases had NS histology.[1,2] Although vascular invasion was not seen, in either the 2 cases, it is regarded by some as a poor prognostic feature in HL.[1,2,9] Necrosis is frequently described in HL, especially in classical types; with the exception of lymphocyte predominant type.[1,2] The incidence of necrosis of various types was observed in as many as two thirds of the cases, especially if lesions become large; central necrosis accounts for the cavitary variety of PPHL.[1,2] Conceivably, necrotic lesions do worst if they become secondarily infected,[2] and this may delay diagnosis, due to resultant liquefaction and secondary abscess formation. Fever is still seen in patients with and without cavitations.

Bronchial wall involvement, usually results in endobronchial obstruction, respiratory symptoms (productive cough and hemoptysis and wheezing), and atelectasis; this is synonymous with what has been described as endobronchial HL, in which the gross polypoid masses invade by erosion and totally occlude the major bronchial lumina, as well as terminal bronchi, regardless of the size and the caliber of the bronchus.[1-4] Although one third of all PPHL patients reported in a large series present with accompanying hilar and mediastinal lymph node (as shown by their chest CT scans), histopathologic examination of these lymp nodes reveal that less than half of these are actually involved HL.[1-3] Clinicians therefore may over stage some patients; as was observed in patient 2, where sampling of the radiologically enlarged hilar and mediastinal lymph nodes disclosed sinus histiocytosis only, therefore, placing the patient as PPHL-stage IE. Awareness of the spectrum of clinical and radiological PPHL disease patterns with which patients present is as important. Two of these disease patterns and forms are common, such as the nodular and the subpleural forms,

01Primary20060642 946 5/15/07 10:23:01 AM

whereas the other patterns and forms are rare, such as the bilateral diffuse pneumonic and reticulonodular and endobronchial patterns.[1-4] With such varied and pleomorphic presentation forms of PPHL reported in the literature, an invariably long list of differential diagnostic considerations will unquestionable therefore exist. On the one end of the spectrum (I) benign and inflammatory lesions, such as non-infectious granulomas (Wegener's granulomatosis, which was the diagnostic consideration in patient one), infectious granulomas with caseation or without caseation, interstitial inflammatory pneumonitis, organizing pneumonia, allergic reactions with prominent type II pneumocyte with prominent eosinophilic component. On the one end of the spectrum, (II) malignant diseases that fall in the differential diagnosis of PPHL, include non-Hodgkin's lymphoma (NHL), which includes lymphomatoid granulomatosis; special emphasis have been given to the diffuse polymorphous T-cell NHL, as this may show identical low power pattern of diffuse infiltration or nodular formation and is usually bilateral; similarly, the mixed cell type of CD30-positive anaplastic large cell lymphoma (ALCL) can be included in the differential diagnosis;[11] in fact the resemblance between patient 2 and ALCL is so marked that CD15 staining and lack of CD3 or CD45 staining were instrumental in ruling out this possibility.[11] Metastatic carcinomas with prominent lymphoid stroma (for example, nasopharyngeal-type carcinoma) as well as the rare types of primary pulmonary neoplasms with a histology that is similar to undifferentiated nasopharyngeal carcinoma (UNPC) are included in the differential diagnostic list.[1] The later possibility can be a pitfall if a limited panel of immunohistochemical markers is used. The majority of cases of UNPC are immunohistochemically negative for CD30; however, a small subset of cases expresses CD30 antigen.[12] These findings provide additional evidence that CD30 expression is not restricted to neoplasms of lymphoid origin only. This should be taken into consideration when interpreting a CD30 positive immunohistology and the possibility of UNPC should be therefore be considered in the differential diagnosis.[12] Difficulties in differential diagnosis are met at the time of frozen section, and a delayed diagnosis is usually the case especially after all immunohistochemical stains are concluded. The occurrence of PPHL exclusive of involvement of the hilar lymph nodes can be explained anatomically by the fact that unencapsulated lymphoid tissues are distributed throughout the lung parenchyma, and are located centrally within the bronchial walls and peripherally at the bifurcation points of distal bronchi; additionally, lymphoid aggregates spread peripherally within the loose connective tissues in the interlobular septae. Subpleural and intra-parenchymal lymph nodes maybe primarily involved by HL.[1,2,5,6] Therefore, the involvement in all instances starts initially in the parenchyma where the bronchial mucosal involvement is seen only late in the disease. As a result, cytology and bronchial brushes are expected to be noncontributory in the initial phases, but again patients may have milder symptoms which will not validate bronchoscopy in the first place, later on in the course of the disease when faced with a false negative sample procedural errors such as the procedure of obtaining the cytology may not be thorough enough or optimal or if viscid mucous plugs cover the endobronchial occluding mass creating a barrier between the mass and the circulating lavage.[1,2-10] This in part explains why in patient one cytology was negative in more than one instance, although frank endobronchial involvement by tumor polypoid masses were evident by histopathological examination. If mucosal lesions are visible through the bronchoscope, then one may consider either endobronchial PPHL, or advanced stage IVE-HL with secondary involvement of the lungs;[1,2-10] in the latter situation the patient is known to have HL, and demonstration of the RS cells of a lesion in the lungs that has radiological evidence of involvement is expected. As the presentation of the disease is nonspecific, and symptoms can be so varied, it becomes evident, therefore that noninvasive tests are rarely revealing (bronchial lavage, or bronchial brushes or transbronchial biopsies). It has been shown with our 2 patients as well as with other larger studies, that diagnosis requires an open thoracotomy and lung biopsies.[1-4] If the endoscopy fails, then the diagnosis should depend on combining the histology with the immunohistochemical findings. Symptoms have been noted to be of long duration as was noted in patient 2; similar long durations have been described by others[2,3] as the disease remains localized in the lungs for long periods of time, prior to the actual pathologic diagnosis. This later finding perhaps has not been emphasized by others, but explains in part why patients with PPHL (nodular variety, which may later on develop cavitary changes secondary to necrosis) have a fair prognosis.

Factors which correlate with poor prognosis include: "B" symptoms, older age group (>60 years), bilateral disease, multiple (multilobe) disease, cavitary lesions (refractory to chemotherapy), pneumonic disease, and "penetration" of the pleura with or without associated pleural effusion.[1-4] There is an agreement[1,2] that women are affected more frequently by PPHL than men, and it is thought that their survival is better than those of men. Treatment plans have varied in the literature, but generally speaking, it is agreed nearly by all, that combination of multiple agent chemotherapy (MOPP and/or ABVD)[1,2] and radiotherapy (radiation dose of

01Primary20060642 947 5/15/07 10:23:02 AM

4400 rad to the mantle and volume of the extralymphatic lesion, in addition to 1650 rad to the entire ipsilateral lung)[2] are both needed as lines of treatment. This has been shown in several studies, with patients who receive this treatment regimen showing longer disease free survival.[1,2]

References

1. Youssem S, Weiss LM, Colby TV. Primary pulmonary Hodgkin's disease. A clinicopathologic study of 15 cases. ***Cancer*** 1986; 57: 1217-1224.
2. Radin A. Primary pulmonary Hodgkin's disease. ***Cancer*** 1990; 65: 550-563.
3. Rodriguez J, Tirabosco R, Pizzolitto S, Rocco M, Falconieri G. Hodgkin Lymphoma presenting with exclusive or preponderant pulmonary involvement: a clinicopathologic study of 5 new Cases. ***Ann Diag Pathol*** 2006; 10: 83-88.
4. Kiani B, Magro CM, Ross P. Endobronchial presentation of Hodgkin's lymphoma: A Review of the literature. ***Ann Thorac Surg*** 2003; 76: 967-972.
5. Roth SL, Sack H, Havemann K, Willers R, Kocsis B, Schumacher V. Contiguous pattern of spreading in patients with Hodgkin's disease. ***Radiother Oncol*** 1998; 47: 7-16.
6. Colby T, Carrington CB. Lymphoreticular tumors and infiltrates of the lung. ***Pathology Annual*** 1983; 18: 27-70.
7. Connors J, Klimo P. Is it an I E lesion or stage IV? An issue unsettled on Hodgkin's disease staging. ***J Clin Oncol*** 1984; 2: 1241-1243.
8. Zulian G, Jacot-des-Combes E, Aapro MS. Primary Pulmonary Hodgkin's disease and the dilemma of E stage. ***Eur J Surg Oncol*** 1986; 12: 307-310.
9. Strum S, Allen LW, Rappaport H. Vascular invasion in Hodgkin's disease: its relationship to involvement of the spleen and other extranodal sites. ***Cancer*** 1971: 28; 1329-1334.
10. Variakojis D, Fennessy JJ, Gross NJ. Diagnosis of Hodgkin's disease by bronchial brush. Chest 1972: 61: 326-330.
11. Rush SL, Andriko JA, Taubenberger JK, Nelson AM, Abbondanzo SL, Travis WD, et al. Primary anaplastic large cell lymphoma of the lung: a clinicopathologic study of five cases. ***Mod Pathol*** 2000; 3: 1285-1293.
12. Kneile JR, Tan G, Suster S, Wakely PE Jr. Expression of CD30 (Ber-H2) in naso-pharyngeal carcinoma, undifferentiated type and lympho-epithelioma-like carcinoma. A comparison study with anaplastic large cell lymphoma. ***Histopathology*** 2006; 48: 855-861.

ILLUSTRATIONS, FIGURES, PHOTOGRAPHS

Four copies of all figures or photographs should be included with the submitted manuscript. Figures submitted electronically should be in JPEG or TIFF format with a 300 dpi minimum resolution and in grayscale or CMYK (not RGB). Printed submissions should be on high-contrast glossy paper, and must be unmounted and untrimmed, with a preferred size between 4 x 5 inches and 5 x 7 inches (10 x 13 cm and 13 x 18 cm). The figure number, name of first author and an arrow indicating "top" should be typed on a gummed label and affixed to the back of each illustration. If arrows are used these should appear in a different color to the background color. Titles and detailed explanations belong in the legends, which should be submitted on a separate sheet, and not on the illustrations themselves. Written informed consent for publication must accompany any photograph in which the subject can be identified. Written copyright permission, from the publishers, must accompany any illustration that has been previously published. Photographs will be accepted at the discretion of the Editorial Board.

01Primary20060642 948 5/23/07 8:45:46 AM