In conclusion, underlying precipitating causes should be investigated in patients presenting with HHNC. Mortality seems high in patients presenting with HHNC and AMI. Perhaps, it is necessary to investigate new treatment approaches to reduce mortality in these patients.

Received 28th August 2006. Accepted 30th January 2007.

From the Department of Cardiology, School of Medicine, Trakya University, Edirne, Turkey. Address correspondence and reprint requests to: Dr. Ersan Tatli, Department of Cardiology, School of Medicine, Trakya University, Edirne, Turkey. Tel. +90 (28) 42357641. Fax. +90 (28) 42357652. E-mail: ersantatli@hotmail.com

References

1. Chu CH, Lee JK, Lam HC, Lu CC. Prognostic factors of hyperglycemic hyperosmolar nonketotic state. ***Chang Gung Med J*** 2001; 24: 345-351.
2. Gustafsson I, Hildebrandt P, Seibaek M, Melchior T, Torp-Pedersen C, Kober L, et al. Long-term prognosis of diabetic patients with myocardial infarction: relation to antidiabetic treatment regimen. The TRACE. Study Group. ***Eur Heart J*** 2000; 21: 1937-1943.
3. Norhammar A, Malmberg K, Ryden L, Tornvall P, Stenestrand U, Wallentin L. Register of Information and Knowledge about Swedish Heart Intensive Care Admission (RIKS-HIA). Under utilisation of evidence-based treatment partially explains for the unfavourable prognosis in diabetic patients with acute myocardial infarction. ***Eur Heart J*** 2003; 24: 838–844.
4. Malmberg K, Norhammar A, Wedel H, Ryden L. Glycometabolic state at admission: important risk marker of mortality in conventionally treated patients with diabetes mellitus and acute myocardial infarction long-term results from the diabetes and insulin-glucose infusion in acute myocardial infarction (DIGAMI) Study. ***Circulation*** 1999; 99: 2626-2632.
5. Kersten JR, Toller WG, Gross ER, Pagel PS, Warltier DC. Diabetes abolishes ischemic preconditioning: role of glucose, insulin, and osmolality. ***Am J Physiol Heart Circ Physiol*** 2000; 278: H1218-J1224.

A forgotten complication following pancreatic resection. *Visceral artery pseudo-aneurysms*

Yao-Kuang Huang, *MD,* ***Ming-Shian Lu,*** *MD,*
Feng-Chun Tsai, *MD,* ***Po-Jen Ko,*** *MD,*
Hung-Chang Hsieh, *MD,* ***Pyng-Jing Lin,*** *MD.*

Postoperative bleeding after pancreaticoduodenectomy (PDR), with an incidence of 7.5%, is not an uncommon complication.[1] Most of the bleeders comprised operative field and gastrointestinal ulcers at the anastomotic margin. Visceral artery aneurysms as a bleeding source following PDR, although rare, are clinically important, and potentially lethal without prompt recognition.[2,3] Despite recent advances in therapeutic techniques and diagnostic tools, the management of visceral artery aneurysms following PDR remains clinically challenging. We analyzed the initial presentations, therapeutic interventions, and outcomes of 5 patients with complicating visceral artery aneurysms after PDR, followed by a review of pertinent clinical information. Data were collected retrospectively on all patients receiving PDR and diagnosed with visceral artery aneurysms that occurred between June 2000 and June 2005. **Table 1** lists the demographics and clinical outcomes of these 5 patients. Four patients received one-stage PDR (Whipple's operation) for pancreatic head cancer. Duodenum-preserving pancreatic head resection was deployed in one patient with benign pancreatic lesion. Four out of 5 (80%) patients presented as gastrointestinal bleeding. One patient (20%) presented as bleeding from abdominal drains, and had no additional episode before visceral artery pseudo-aneurysms was proven. The interval from pancreatic resections to definitive diagnosis of visceral artery pseudo-aneurysms was 20.6±7.8 days (range, 10-30 days). Three common hepatic artery, and 2 gastroduodenal artery pseudo-aneurysms were proven in the diagnostic angiography. Common hepatic artery pseudo-aneurysms were treated by coil embolizations of the common hepatic artery (**Figure 1**). Pseudo-aneurysms in the gastroduodenal artery obliterated all feeding arteries as in case 4, or occluded the pseudo-aneurysm per se as in case 5. The only in-hospital death had received PDR for pancreatic cancer and was discharged on post-operative day 14th. The patient returned to the emergency department on post-operative day 26th owing to jaundice, severe upper gastrointestinal bleeding, and hypovolemic shock. Emergency arterial angiography disclosed a common hepatic pseudo-aneurysm, which ruptured into the gastrointestinal tract. Although hemostasis was temporarily achieved by transcatheteric coil embolization, the patient eventually succumbed as a result of multi-organ failure. There were 2 deaths in the follow-up; one died of intra-abdominal abscess in the 3rd month, and the other died of liver abscess in the 22nd month. The mean follow-up (excluded one in-hospital mortality) was 21.25±16.58 months, range 3-43 months.

Brodsky and Turnbull[4] reported a "sentinel bleed" after PDR that was attributed to vessel erosion. Fresh bloody discharge from abdominal drains comprised most initial presentations of "sentinel bleed." Relevant clinical research also had similar observations, with an average presentation of 19 days after PDR.[5] In this

BriefCommunication 973 5/15/07 10:30:44 AM

Table 1 - Demographics and clinical outcomes.

No.	Sex/Age	Surgical Procedures	Pathology	Presentation	Interval (days)	Aneurysm site	Intervention for visceral artery aneurysms	In-hospital death	Follow-up	Final Status
1	M/51	Radical PDR with pancreatico-jejunostomy Billroth II gastrojejunostomy Choledochojejunostomy and cholecystectomy Feeding jejunostomy	Ampullary adeno-carcinoma	UGIB	26	Common hepatic artery	Occlusion of common hepatic artery by 2 coils	Yes	None	Recurrent bleeding
2	M/68	Radical PDR with pancreatico-jejunostomy Billroth II gastrojejunostomy Choledochojejunostomy and cholecystectomy Feeding jejunostomy	Ampullary adeno-carcinoma	UGIB	10	Common hepatic artery	Occlusion of common hepatic artery by 4 coils	No	Died in 22nd month	Liver abscess
3	M/57	Radical PDR with pancreatico-jejunostomy Billroth II gastrojejunostomy Choledochojejunostomy and cholecystectomy Feeding jejunostomy	Ampullary adeno-carcinoma	UGIB	20	Common hepatic artery	Occlusion of common hepatic artery by 4 coils	No	Alive in 43rd month	Free of recurrence
4	M/72	Radical PDR with pancreatico-jejunostomy Billroth II gastrojejunostomy Choledochojejunostomy and cholecystectomy Feeding jejunostomy	Poorly differentiated adeno-carcinoma	Bleeding via drain	17	Gastro-duodenal artery	An outpouch contrast at the stoma of gastroduodenal artery. Occluded the aneurysms by 8 steel coils, from common hepatic artery to gastroduodenal artery	No	Alive in 17th month	Liver metastasis
5	F/65	Duodenum-preserving pancreatic head resection Roux-en-Y pancreatico-jejunostomy	Microcystic adenoma	UGIB	30	Gastro-duodenal artery	A saccular pseudoaneurysm in the middle third of the gastroduodenal artery. Fulfill aneurysmal sac by 2 coils	No	Died in 3rd month	Intra-abdominal abscess

PDR - Pancreaticoduodenectomy; UGIB - Upper gastrointestinal bleeding; Interval (days): interval from pancreaticoduodenectomy to clinical presentation.

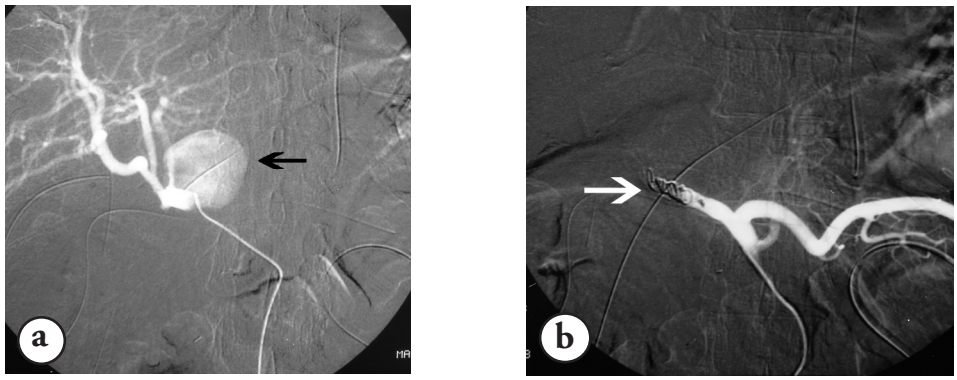

Figure 1 - An example of endovascular treatment of visceral artery pseudoaneurysm after pancreatic resection in case 3; a) Angiographic survey for intermittent gastrointestinal bleeding after Whipple's operation demonstrated anout-pouch from common hepatic artery, which was compatible with pseudoaneurysm. Black arrow indicates the pseudoaneurysm. b) Common hepatic artery was trapped with four pieces of metallic coils. The followed angiography revealed total occlusion of the pseudoaneurysm and common hepatic arterial flow. White arrow indicates the blind end of common hepatic artery.

BriefCommunication 974 5/15/07 10:30:45 AM

study, the interval from PDR to definitive diagnosis of visceral artery aneurysms was 20.6±7.8 days (range, 10-30 days). However, only one patient in our series presented as fresh blood in the abdominal drains. Eighty percent (4/5) presented a diagnostic enigma, as the gastro-intestinal bleeding is the sole manifestation. Their definite diagnoses were obtained by angiography arranged following a negative pan-endoscopic examination for peptic ulcer.

Surgical exploration and identification of the bleeding vessels may be difficult and hazardous due to the surrounding of post-surgical tissue friability. Bowel adhesion and anatomic variation following PDR further complicated the treatment. Endovascular intervention thus became the preferred treatment option for aneurysms disclosed in the angiography for indeterminate gastrointestinal bleeding after PDR. Aneurysms of the hepatic artery were treated via total exclusion without vascular reconstruction. Collateral circulation is usually sufficient through the superior mesentery artery to the gastroduodenal artery. In cases of pancreatoduodenal and gastroduodenal artery aneurysms, hemostasis is often difficult due to multiple communicating vessels. Endovascular coil embolization during angiographic study is advantageous over surgery in easily identifying and obliterating all the feeding arteries to the aneurysm in cases with such anatomic restrictions. Prompt endovascular coil embolization achieved 80% short-term success in this series. The only hospital death was caused by profound hypovolemic shock prior to resuscitation. Two late deaths directly were attributed to infection, which reflected the immuno-compromised status of the patients. In addition, one survivor was proven with liver metastasis at 17th month follow-up. Although the long-term outcomes of visceral artery aneurysms following PDR are less favorable, the endovascular approach still provides adequate efficiency within their limited life expectancy.

In conclusion, successful treatment of visceral artery aneurysms following PDR requires a high index of suspicion, early diagnosis, and timely treatment. The endovascular intervention is feasible in such conditions. Clinical practitioners associated with pancreatic disease should be familiar with this scenario.

Received 6th August 2006. Accepted 27th January 2007.

From the Division of Thoracic and Caridiovascular Surgery, Chang Gung Memorial Hospital, Linkou Center and Chang Gung University, College of Medicine, Taiwan. Address correspondence and reprint requests to: Dr. Po-Jen Ko, Division of Thoracic and Cardiovascular Surgery,Chang Gung Memorial Hospital, Linkou Center, 199 Tun-Hwa North Road Taipei, Taiwan 105. Tel. +886 (332) 81200. Fax: +886 (332) 85818. E-mail: huang137@mac.com

References

1. Rumstadt B, Schwab M, Korth P, Samman M, Trede M. Hemorrhage after pancreatoduodenectomy. ***Ann Surg*** 1998; 227: 236-241.
2. Otah E, Cushin BJ, Rozenblit GN, Neff R, Otah KE, Cooperman AM. Visceral artery pseudoaneurysms following pancreatoduodenectomy. ***Arch Surg*** 2002; 137: 55-59.
3. Reber PU, Baer HU, Patel AG, Triller J, Buchler MW. Life-threatening upper gastrointestinal tract bleeding caused by ruptured extrahepatic pseudoaneurysm after pancreatoduodenectomy. ***Surgery*** 1998; 124: 114-115.
4. Brodsky JT, Turnbull AD. Arterial hemorrhage after pancreatoduodenectomy. The sentinel bleed. ***Arch Surg*** 1991; 126: 1037-1040.
5. Turrini O, Moutardier V, Guiramand J, Lelong B, Bories E, Sannini A, et al. Hemorrhage after duodenopancreatectomy: impact of neoadjuvant radiochemotherapy and experience with sentinel bleeding. ***World J Surg*** 2005; 29: 212-216.

Isoniazid susceptibilities of *Mycobacterium tuberculosis* on blood agar

Cilem Yildiz, *MD,* ***Mahmut Ulger,*** *MSci,*
Gonul Aslan, *MD,* ***Gurol Emekdas,*** *PhD.*

Tuberculosis (TB) is an important public health problem in both developed and developing countries.[1] It is estimated that more than 8 million new cases of active TB occur annually and the global annual mortality is close to 2 million people. Mycobacterial cultures and susceptibility testing must be rapidly concluded for effective treatment and control of the disease. The 2 methods most commonly used for susceptibility testing of Mycobacterium tuberculosis (*M.tuberculosis*) include the proportion method performed on Lowenstein-Jensen medium (LJ) and Middlebrook 7H10-11 agar, and the BACTEC 460 TB system Becton Dickinson, sparks, MD, USA). The proportion method requires 3 weeks of incubation. The BACTEC 460 TB system uses a broth medium containing radio labeled palmitic acid substrate and results can be reported in 4-7 days, but it is labor-intensive, expensive, and generates radioactive waste.[2,3] The incidence of multidrug-resistant tuberculosis (MDR-TB), has increased in recent years. The MDR-TB, caused by strains resistant to at least isoniazid (INH) and rifampicin (RMP), is considered an emergent disease as well as the consequence of inadequate treatment. The World Health Organization has estimated that approximately 460,000 MDR-TB cases occur each year.[4] Early detection of MDR *M. tuberculosis* strains is important for control of tuberculosis. Drancourt et al[5]

BriefCommunication 975 5/15/07 10:30:46 AM